



Case Report

Coinfection of mucormycosis and aspergillus in a diabetic patient: A rare entity

Manju Kumari^{1,*}, Purnima Malhotra¹, Minakshi Bhardwaj¹

¹Dept. of Pathology, PGIMER, Dr. RML Hospital, New Delhi, India



ARTICLE INFO

Article history:

Received 28-11-2019

Accepted 03-12-2019

Available online 11-01-2020

Keywords:

Mucormycosis

Aspergillosis

Diabetes

Coinfection

ABSTRACT

Mucormycosis is a life threatening infection caused by mucorales occurring in immunocompromised /diabetic individuals. Aspergillosis caused by aspergillus also causes a fatal disease in these individuals. A very few cases of coinfection of aspergillosis and mucormycosis are reported in diabetic patients in the literature. Here, we report this coinfection in a 60-years old female.

© 2019 Published by Innovative Publication. This is an open access article under the CC BY-NC-ND license (<https://creativecommons.org/licenses/by/4.0/>)

1. Introduction

Mucormycosis is an opportunistic, aggressive infection caused by organisms belonging to Mucorales order of the class Zygomycetes. They are saprophytes and are universally distributed. Aspergillosis is the clinical condition caused by the Aspergillus species, most often *A. fumigatus*.¹ The predisposing conditions for both the organisms are uncontrolled diabetes, immunodeficiency, organ transplantation, underlying malignancy and cirrhosis.² If diagnosis and therapeutic interventions are delayed it may result in massive tissue destruction and, eventually death. A very few case reports of coinfection of mucormycosis and aspergillus in a diabetic are described in the literature.³

2. Case Report

A 60-yrs-old female presented with headache in left frontal region, left nasal obstruction and left sided purulent nasal discharge for last one and half month. Headache was relieved with medication. There was a history of single episode of epistaxis and diminution of vision for last 20 days. The patient was known case of uncontrolled diabetes.

Blood test revealed anemia, leucocytosis and increased ESR (Hb-10.0 g/dl, TLC-126000 cells/ cumm, ESR- 116 mm in 1st hour). Blood sugar was 276 mg/dl. Liver function test and renal function test were within normal limits. She was HIV 1 and HIV 2 nonreactive NCCT PNS revealed left maxillary, ethmoid, frontal and sphenoid sinusitis with mucosal thinning and frothing secretions in left nasal cavity with bony erosions of the walls of left maxillary.

Surgical debridement was done under general anaesthesia which showed black crusts and necrosed nasal septum. Histopathology sections showed numerous broad aseptate ribbon like hyphae of mucor along with thin septate aspergillus hyphae with acute angle branching (Figures 1 and 2). Many sporangiospores and occasional fruity bodies of aspergillus were also noted which are very rarely seen on histology sections. These hyphae, spore and fruity bodies were highlighted on silver stain (Figure 3). However, on nasal KOH mount only broad hyphae with branching were noted.

Patient was started on liposomal amphotericin B, a cumulative dose of 2000 mg was given, followed by itraconazole 200 mg OD. While on amphotericin she developed hypokalemia for which syrup potassium chloride

* Corresponding author.

E-mail address: manju.yadav126@gmail.com (M. Kumari).

was given. One unit of packed cell blood transfusion was done to correct anemia.

Patient responded well and was free of symptoms at the time of discharge.

Here we have presented a very rare combination of aspergillus with mucor infection alongwith presence of fruity bodies which are hardly seen on histopathology.

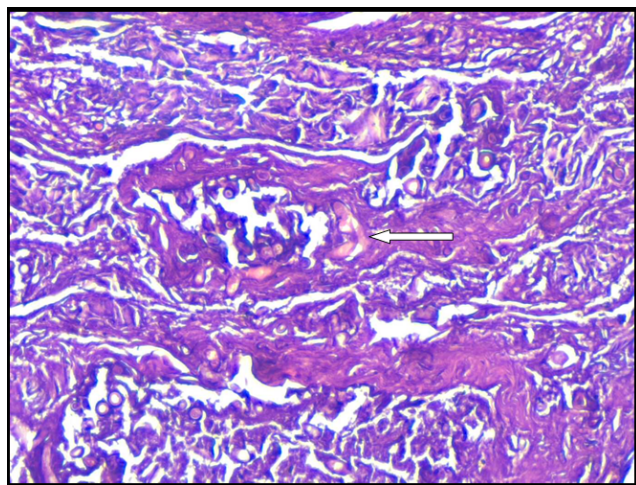


Fig. 1: Section showing angioinvasion by the fungal hyphae. (Arrow mark, H&E 200x)

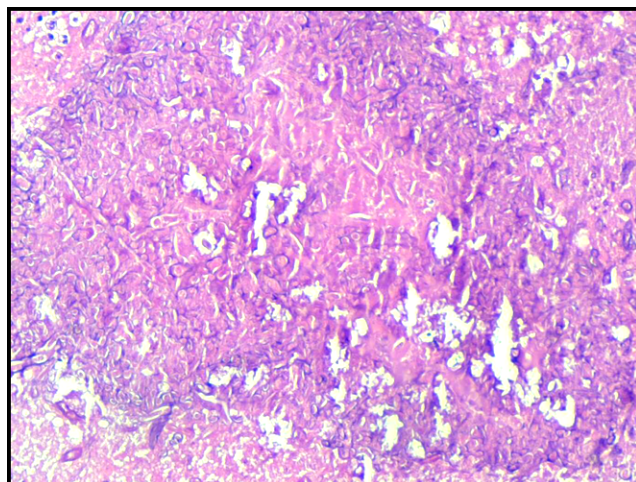


Fig. 2: Section showing broad aseptate hyphae of mucor and thin septate hyphae and spores of aspergillus. (H&E, 200x)

3. Discussion

Diabetes is a well known predisposing factor for invasive fungal infections as it can alter the immunological response of patients to the infections. There is decreased granulocyte mediated phagocytosis in these patients. Also hyperglycemia provides a good microenvironment for fungal growth. Mucormycosis is a lethal opportunistic

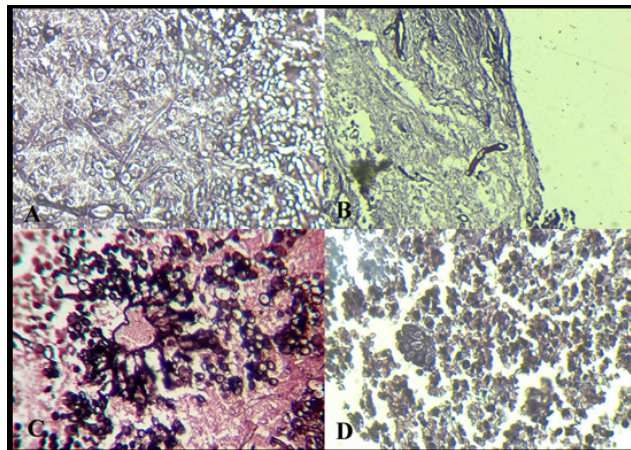


Fig. 3: Gomori silver methenamine stain showing (A). Hyphae of mucor and aspergillus (B) Broad aseptate hyphae of mucormycosis (C & D) Fruting bodies and spores of aspergillus.

infection. The various genera responsible for infection are Rhizopus (most common), Rhizomucor and Absidia.¹ The Fungal hyphae have a predilection for growth into arteries, lymphatics and nerves. These invades the vessels and cause occlusion of vessels by fibrin reaction leading to ischaemia and infarction. The black necrotic eschar produced due to infarction is characteristic of mucormycosis. Rhino-orbital-cerebral form of mucormycosis is the most common among gastrointestinal, pulmonary, subcutaneous, central nervous system, disseminated and other miscellaneous syndromes.⁴ The fungus can extend to orbit and brain along the vessels.³ The criteria for the clinical diagnosis of mucormycosis as given by Smith and Krichner⁵ are:

1. Blood mixed nasal discharge and facial pain, both on the same side.
2. Ptosis of the eyelid, proptosis of the eyeball and total ophthalmoplegia.
3. Soft peri-nasal or peri-orbital swelling with discoloration, induration and progressive vascular occlusion.
4. Multiple unrelated cranial nerve palsies
5. Black, necrotic turbinates, easily mistaken for dried, crusted blood

Invasive Aspergillus produces yellowish or black necrotic material and most commonly affects patients with uncontrolled diabetes, leukemia and immunodeficiency.⁶

The differential diagnoses in such clinical setting include septic emboli, atherosclerotic vasculopathy, vasculitis, local streptococcal and clostridial infection, and invasive Aspergillus.⁴

The diagnosis is based on histopathological demonstration of fungal hyphae which can be further highlighted by special stains like PAS and GMS. A culture can further support the diagnosis although it is not mandatory.

An early diagnosis, prompt institution of antifungal therapy (amphotericin) with timely surgical debridement and correction of underlying predisposing factor is the key to survival in cases of invasive mycosis.¹ Nephrotoxicity and other side effects of amphotericin is an obstacle to treatment for which less toxic forms of the drug ‘ such as liposomal amphotericin B, colloidal dispersion amphotericin B, and amphotericin B lipid complex ’ can be helpful.⁷

4. Conclusion

Although a very few cases of coexistence of mucormycosis and aspergillosis are reported in diabetic patient , a high suspicion should always be kept for timely diagnosis and early treatment of these cases.

5. Source of Funding

None.

6. Conflict of Interest

None.

References

1. Tryfon S, Stanopoulos I, Kakavelas E. Rhinocerebral mucormycosis in a patient with latent diabetes mellitus: a case report. *J Oral Maxillofac*

Surg. 2002;60:328–330.

2. Yohai RA, Bullock JD, Aziz AA, Markert RJ. Survival factors in rhino-orbital-cerebral mucormycosis. *Surv Ophthalmol.* 1994;39:3–22.
3. Rit K, Saha R, Dey R, Barik G. Rhino-oculo-cerebral aspergillus and mucor co-infections in an immunocompromised patient with type 2 diabetes mellitus. *Med J DY Patil Univ.* 2014;7:486–488.
4. Sugar AM. Mucormycosis. *Clin Infect Dis.* 1992;14(S):126–129.
5. Martino P, Raccach R, Gentile G, Venditti M, Girmenia C, et al. Aspergillus colonization of the nose and pulmonary aspergillosis in neutropenic patients: a retrospective study. *Haematologica.* 1989;74(3):263–265.
6. Nagarkar NM, Verma H, Punia RPS. Co-existing Mucormycosis with Aspergillosis in a patient with Diabetes Mellitus- First case report. *Otolaryngol Online J.* 2014;4:4–4.
7. Strasser MD, Kennedy RJ, Adam RD. Rhinocerebral mucormycosis. Therapy with amphotericin B lipid complex. *Arch Intern Med.* 1996;156:337–339.

Author biography

Manju Kumari Resident

Purnima Malhotra Specialist

Minakshi Bhardwaj Professor

Cite this article: Kumari M, Malhotra P, Bhardwaj M. Coinfection of mucormycosis and aspergillus in a diabetic patient: A rare entity. *Int J Med Microbiol Trop Dis* 2019;5(4):241-243.