



Case Report

Nocardia farcinica superficial sternal wound infection following coronary artery bypass surgery in a tertiary care hospital in Hyderabad

R Saraswati Jayanthi^{1,*}, R Nagamani²

¹Dept. of Microbiology, Terna Medical College & Hospital, Navi Mumbai, India

²BBR Superspeciality Hospital, Hyderabad, Telangana, India



ARTICLE INFO

Article history:

Received 06-12-2019

Accepted 20-12-2019

Available online 26-04-2020

Keywords:

Nocardia

ABSTRACT

A 54yr diabetic male was admitted with sternal wound dehiscence. Nocardia farcinica species was isolated from pus discharge from post-operative wound site. Prompt treatment with antibiotics and surgical intervention initiated cure in the patient.

© 2020 Published by Innovative Publication. This is an open access article under the CC BY-NC-ND license (<https://creativecommons.org/licenses/by/4.0/>)

1. Introduction

Nocardia are aerobic actinomycetes responsible for localized or disseminated infection in humans and animals. Cases of human infection have increased substantially in the past two decades, in association with an increasing population of immune-compromised hosts and improved methods for detection and identification of Nocardia species in the clinical laboratory

2. Case Report

A 55yr old diabetic male, case of coronary artery disease with triple vessel occlusion underwent coronary artery bypass grafting on 04.02.2015.

He had an uneventful recovery and was discharged on 14th post operative day. He was re admitted after 26 days with history of having serosanguinous discharge from operative site of 1 week duration .He gave no history of fever. His pulse was -78-/minutes, BP-110-/70 mmHg.

The total WBC count was 8000/cumm. His differential count was polymorphonuclear cells 70%, leucocytes25%, lymphocyte-5% and eosinophils were 3%.

On examination the sternal sutures were open, there was 3inch dehiscence, and the subcutaneous tissue was infected Fig 1. Pus swabs sent from the wound site which grew a dry powdery, white colony at the end of 72 hours. He had a wound debridement on 04.03.15 and started with Tab Cefum 500mg BD.

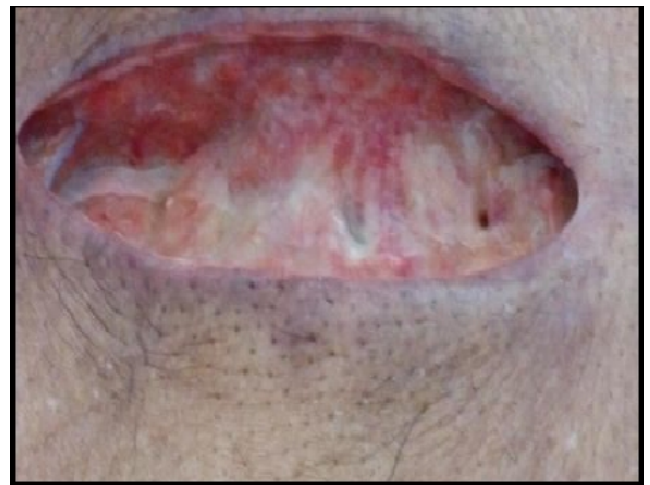

Fig. 1: Surgical wound infection

* Corresponding author.

E-mail address: drsaras@gmail.com (R. S. Jayanthi).

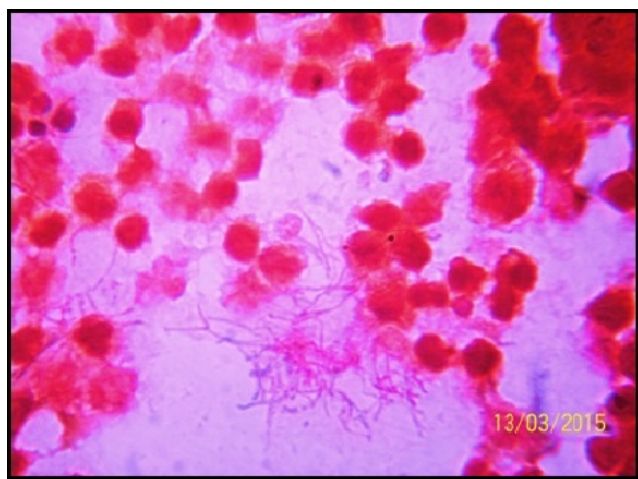


Fig. 2: Gram stain of direct smear from pus swab

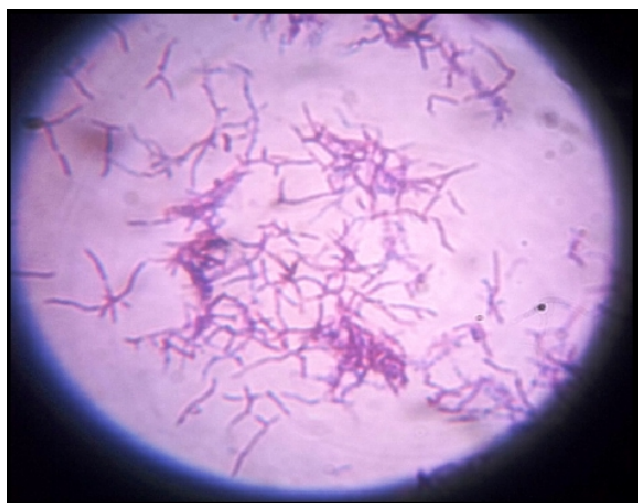

Fig. 3: Gram's stain from culture

2.1. Laboratory Diagnosis

Two pus swabs were collected from the wound and sent for Gram's stain, culture and susceptibility testing. Gram's stain from pus sample showed numerous pus cells along with Gram positive, long and thin filamentous branching structure breaking to form cocci Figure 1. The pus swabs were also inoculated onto blood agar, chocolate agar, MacConkey's agar and thioglycollate broth. After 24hrs small pin point colonies were observed, after 72hrs typical wrinkled, dull white and dry colonies appeared on Blood agar and chocolate agar Figure 2. In thioglycollate broth there was a granular turbidity. Gram stain from culture again showed Gram positive branching structures Figure 3.

Following Gram's stain Kinyoun's acid fast stain was done on culture isolate and the isolate was acid fast. Sensitivity testing was done on Mueller Hinton agar and isolate was found to be sensitive to Amikacin, Gentamycin, Erythromycin, Ciprofloxacin and Ofloxacin but resistant

to Cotrimoxazole and Penicillin. Isolate was identified as *Nocardia farcinica* by National Culture Collection of Pathogenic Fungi(NCCPF), Post Graduate Institute of Medical Education and Research, Chandigarh.

He was empirically started on Ceftum which was later changed to teicoplanin 400mg BD and Cotrimoxazole after culture reports became available. The wound debridement was done and patient started to improve clinically he was discharged after about 15 days of treatment in hospital. A review after two months the patient was asymptomatic and wound had healed well.

3. Discussion

Ubiquitous in soil, all *Nocardia* can establish superficial infection after relatively trivial inoculation injuries. The incidence of sternal wound infection is somewhere between 0.43 – 2.3%.^{1–3} The sternal wound infection may increase morbidity and mortality with increasing stay of cost treatment and hospital stay. The commonest risk factor in most cases is Diabetes mellitus. The usual cause of sternal wound infections are mostly caused by *Pseudomonas aeruginosa*, *Staphylococcus* and *Streptococcus* species⁴ and reports of *Nocardia farcinica* causing sternal wound infection is very rare.

4. Source of funding

None.

5. Conflict of interest

None.

References

1. Oakley RME, Wright JE. Postoperative mediastinitis: Classification and management. *Ann Thoracic Surg.* 1996;61:1030–1036.
2. Borger MA, Rao V, Weisel RD. Deep Sternal Wound Infection: Risk Factors and Outcomes. *Ann Thoracic Surg.* 1998;65(4):1050–1056.
3. Blanchard A, Humi M, Ruchat P, Stumpe F, Fischer A, et al. Incidence of deep and superficial sternal infection after open heart surgery: A ten years retrospective study from 1981 to 1991. *Europ J Cardio-Thoracic Surg.* 1995;9(3):153–157.
4. Okonta KE, Anbarasu M, Agarwal V, Jamesraj J, Kurian VM, et al. Sternal wound infection following open heart surgery: appraisal of incidence, risk factors, changing bacteriologic pattern and treatment outcome. *Indian J Thorac ardiovac Surg.* 2011;27:28–32.

Author biography

R Saraswati Jayanthi Professor and HOD

R Nagamani Consultant Microbiology

Cite this article: Jayanthi RS, Nagamani R. *Nocardia farcinica* superficial sternal wound infection following coronary artery bypass surgery in a tertiary care hospital in Hyderabad. *IP Int J Med Microbiol Trop Dis* 2020;6(1):66-67.