

Content available at: <https://www.ipinnovative.com/open-access-journals>

IP International Journal of Medical Microbiology and Tropical Diseases

Journal homepage: <https://www.ijmmttd.org/>

## Case Report

# Rhizopus microsporus pulmonary sepsis: Case report and review of literature

Umamaheswari K<sup>1,\*</sup>, Gnanasekar R<sup>2</sup>, Sadagopan Kumar<sup>3</sup>

<sup>1</sup>Dept. of Biotechnology, University of Madras, Guindy, Chennai, Tamil Nadu, India

<sup>2</sup>University of Madras, Guindy, Chennai, Tamil Nadu, India

<sup>3</sup>Government Hospital of Thoracic Medicine, Chennai, Tami Nadu, India



### ARTICLE INFO

#### Article history:

Received 05-05-2022

Accepted 18-05-2022

Available online 06-09-2022

#### Keywords:

Pulmonary mucormycosis

Diabetes mellitus

Rhizopus microsporus

Amphotericin B

### ABSTRACT

**Background:** The incidence of opportunistic fungal infection, mucormycosis associated with high mortality rate is steadily increasing. Pulmonary mucormycosis though rare, it relatively affects individuals with diabetes mellitus and other immunosuppressive conditions. The present study reports on case of pulmonary mucormycosis caused by *Rhizopus microsporus*.

**Materials and Methods:** Sputum sample was collected from a 47-year-old male with diagnosed with tuberculosis with spontaneous left sided pneumothorax and diabetes mellitus. The positive fungal culture was characterized by phenotypic and genotypic methods and antifungal susceptibility of the isolate was tested against azoles and amphotericin B.

**Results:** The etiological agent was identified as *R. microsporus* based on phenotypic features and molecular sequencing of ITS. The isolate was susceptible to all the tested antifungal and the patient responded well to Amphotericin B with strict glycemetic control and combination of anti-infective therapy.

**Conclusion:** Though pulmonary mucormycosis is relatively rare; it share its clinical picture with pulmonary tuberculosis and aspergillosis, hence clinical suspicion for mucormycosis in susceptible high risk patients is warranted for early diagnosis and appropriate therapy.

This is an Open Access (OA) journal, and articles are distributed under the terms of the [Creative Commons Attribution-NonCommercial-ShareAlike 4.0 License](https://creativecommons.org/licenses/by-nc-sa/4.0/), which allows others to remix, tweak, and build upon the work non-commercially, as long as appropriate credit is given and the new creations are licensed under the identical terms.

For reprints contact: [reprint@ipinnovative.com](mailto:reprint@ipinnovative.com)

## 1. Introduction

Mucormycosis is a life-threatening and necrotizing infection that has emerged increasingly as the most common invasive mycosis of importance after candidiasis and aspergillosis. The major predisposing factor for mucormycosis includes uncontrolled Diabetes mellitus, chemotherapy, hematological malignancies, acquired neutropenia, metabolic acidosis, renal failure, solid organ transplantation, immunosuppressive therapy and burn injury. The most commonly recovered genera of mucormycetes include *Rhizopus*, *Mucor*, *Rhizomucor*, *Cunninghamella* and *Saksenaia*.<sup>1</sup> Based on the clinical

presentation and anatomic localization mucormycosis is categorized as rhinocerebral, pulmonary, cutaneous, gastrointestinal, disseminated and localized infections. Pulmonary mucormycosis constitutes 24% of all reported cases of mucormycosis, but given the diagnostic limitations in clinical laboratories especially in resource limited settings this could be an underestimate. *Rhizopus oryzae* and *Rhizopus microsporus* are the most common species of mucoralean fungi causing human infection in most case series accounting for 70 to 80% cases.<sup>2</sup> We herein describe a rare case of pulmonary mucormycosis due to *Rhizopus microsporus* in pulmonary tuberculosis patient with diabetic mellitus and spontaneous pneumothorax.


\* Corresponding author.

E-mail address: [rk\\_uma@yahoo.com](mailto:rk_uma@yahoo.com) (Umamaheswari K).

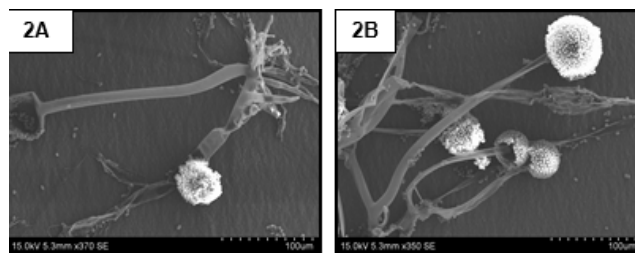
## 2. Case Description

A 47 year-old male attending Government Hospital of Thoracic Medicine, Tambaram, Tamil Nadu, India presented with complaints of breathlessness, cough with mucopurulent expectoration and low-grade fever that persisted for 2 weeks. The medical history revealed that, he had uncontrolled diabetes mellitus for the last three years and was a known case of pulmonary tuberculosis undergoing treatment for TB with no complaint of chest pain, hemoptysis and allergies. On physical examination, the patient was conscious and tachypneic (respiratory rate of 36/min) with normal blood pressure of 127/89 mm, pulse rate of 106/min, oxygen saturation of 99% and temperature of 98.4°F. Heart sounds were normal and there was no cyanosis, clubbing or oedema. The blood samples were seronegative for HIV and Hepatitis B and sputum smears whereas sputum smears was positive for acid-fast bacilli. The complete hemogram did not show any significant abnormalities: hemoglobin (12.8 g/dl), RBC (4.78  $\mu$ l), total leukocyte count (7500 cells/cmm) and differential leukocyte count of 69.8% neutrophils, 21.3% lymphocytes and 8.9% of eosinophils, basophils and monocytes. Platelets were adequate with a count of  $834 \times 10^3/\mu$ l and mild microcytic anemia was noted with MCV count of 77.2 fl/red cell. The serum chemistry profile of the patient showed severe uremia with increased urea (63mg/dl) and high creatine (1.8mg/dl) in the blood, while the other serum markers-bilirubin (0.7mg/dl), AST (50 U/L), ALT (47 U/L), SAP (249 $\mu$ g/ml), total protein (6.3g/dl), albumin (4.0 g/dl) and globulin (2.3g/dl) were normal. The blood sugar level of the patient was significantly high with fasting blood sugar level (FBS) (229 mg/dl) and post prandial (PP) sugar level (398 mg/dl). Based on the laboratory investigations and the result of chest radiograph, the patient was diagnosed with pulmonary tuberculosis with spontaneous left sided pneumothorax. The patient was admitted in intensive respiratory care unit and intercostal chest drain tube was inserted into anterior axillary line to drain the purulent fluid accumulated in the pleural space. The patient was kept under strict monitoring and was administered with intravenous cefotaxime. On day 08 of admission, the patient developed ketonuria and albuminuria with FBS (226 mg/dl) and PP (398 mg/dl) and was treated to control the blood pressure and blood glucose levels. After 20 days of chest tube insertion, the patient developed severe pyopneumothorax with temperature of 99.4°F and pulse rate of 120/min. The patient was toxic and tachypneic with no reduction in intercoastal tube drainage, although the hematological and biochemical parameters were normal. The sputum and purulent material collected from chest tube revealed presence of acid-fast bacilli on microscopy and on Sabouraud Dextrose Agar (SDA) grew fungi which remained positive on repeated sample culturing. Broad sparsely aseptate thin walled hyphae observed in direct KOH mount, appeared as fluffy and

cottony with grayish white appearance and slightly yellow on reverse on SDA medium [Figure 1a&b] which was suggestive of fungi belonging to the order Mucorales. The lactophenol cotton blue mount [Figure 1c] and scanning electron microscopic analysis [Figure 2A&B] revealed the characteristics broad hyaline, thin walled aseptate hypha and the sporangiophores were unbranched and sporangia was spherical filled with sporangiospores. Based on the macroscopic and microscopic features the fungus was identified as *Rhizopus* species.



**Fig. 1:** Macroscopic and microscopic features of *R. microsporus*; **1a):** KOH mount (40x magnification) showing the presence of aseptate hyphae; **1b):** Colony characteristics of *R. microsporus* on SDA; **1c):** Lactophenol cotton blue mount showing typical right angle unbranched sporangiophore with multispored sporangia of *R. microsporus* with aseptate hyphae and rhizoids.



**Fig. 2:** Scanning Electron Micrograph of *R. microsporus*; **2A):** Rhizoids and Columella; **2B):** Right angled unbranched sporangiophore with sporangium.

The fungi were further characterized by molecular sequencing of internal transcribed spacer (ITS) (accession number; MN177926) and D1/D2 region of ribosomal DNA (accession number; MN197703) using ITS1/ITS4 and D1/D2 primers respectively and the species was confirmed as *Rhizopus microsporus*. Based on cytological and microbiological reports, the patient was diagnosed with pyopneumothorax along with pulmonary mucormycosis. The invitro susceptibility of the *R. microsporus* towards polyene and azole antifungal drugs was tested by microbroth dilution assay as per CLSI guidelines M38-A2 showed susceptibility to amphotericin B, Itraconazole, fluconazole and voriconazole with MIC values of 0.25, 0.25, 2.0 and 0.25  $\mu$ g/ml respectively. The patient was put on strict glycemic control and treated with Amphotericin B and fever resolved in 48hrs and subsequent samples were culture

**Table 1:** Summary of pulmonary cases of infection with *Rhizopus microsporus*.

S. No.	Region/ Country	No. of Cases	Age/ Sex	Underlying condition	Site of infection	Autopsy Identification tool	Therapy	Outcome
1.	Maniwa et al. (2002) <sup>3</sup> Embu, Kenya	01	85/F	Bronchial asthma	Lungs (invasive)	Culturing	Amphotericin B, Miconazole	Died of neutropenia and enterocolitis
2.	de Mol et al. (2009) <sup>4</sup> Nijmegen, The Netherlands	01	71/M	Steroid induced hyperglycemia	Lungs (Disseminated)	Culturing and Microscopy	Itraconazole, Voriconazole	Died of open lung biopsy
3.	Saegeman et al. (2010) <sup>6</sup> Leuven, Belgium	04	56/F	Lung transplant recipient, Diabetes Mellitus	Lungs (invasive)	NA	Amphotericin B,	Death related to CMV
			70/M	Chronic myeloid leukemia, Diabetes Mellitus	Lungs (invasive)	NA	No specific therapy	Death related to Mucormycosis
			72/M	Myelodysplastic syndrome	Lungs and Heart (Disseminated)	NA	Amphotericin B	Death related to Mucormycosis
4.	Lyskova et al. (2013)[21] Sokolovska, Czechia	01	62/M	Acute myeloblastic leukemia	Lungs (invasive)	ITS sequencing	Amphotericin B and Posaconazole	Death related to Mucormycosis
5.	Kogure et al. (2014)[22] Tokyo, Japan	01	88/M	Pancytopenia	Lungs (invasive)	D1/D2 sequencing	Posaconazole, Miconazole	Death related to Mucormycosis
6.	Tsyrukunou et al. (2014)[23] Massachusetts, USA	01	61/M	Chronic obstructive pulmonary disease, Diabetes mellitus	Lungs (invasive)	ITS and D1/D2 sequencing	Fluconazole, Posaconazole, Amphotericin B	Survived
7.	Kimet al. (2014) <sup>5</sup> Incheon, South Korea	01	83/M	Pulmonary Tuberculosis, Diabetes mellitus	Lungs (invasive)	ITS and D1/D2 sequencing	Itraconazole, Amphotericin B	Died of respiratory insufficiency
8.	Sharma et al. (2016)[24] New York, USA	01	56/F	Renal transplant recipient, Diabetes mellitus	Lungs and Thyroid (Disseminated)	Microscopy	Miconazole, Voriconazole	Death related to Mucormycosis
9.	Al- Sheikhi et al. (2017)[25] Birmingham, United Kingdom	01	75/M	Myelofibrosis, Diabetes mellitus	Lungs (invasive)	Microscopy	Amphotericin B	Death related to Mucormycosis
10.	Pandey et al. (2018)[26] Haryana, India (n=1), Bihar, India(n=2), Uttar Pradesh, India (n=1), Delhi, India (n=1)	05	50/M	Chronic Kidney Disease	Lungs (invasive)	ITS sequencing	Amphotericin B	Survived
			44/M	Renal transplant recipient, Uncontrolled Diabetes mellitus	Lungs (invasive)	ITS sequencing	Amphotericin B,	Death related to Mucormycosis
			52/M	Uncontrolled Diabetes mellitus	Lungs (invasive)	ITS sequencing	Posaconazole, Amphotericin B,	Survived
		65/F	Uncontrolled Diabetes mellitus	Lungs (invasive)	ITS sequencing	Posaconazole, Amphotericin B	Survived	
		28/M	Acute lymphoblastic leukemia	Lungs (invasive)	ITS sequencing	ITS	NA	Death related to Mucormycosis

negative. The intercostal chest drain was continued further for the complete removal of purulent fluid accumulated in the pleural space along with anti-tubercular therapy and further recurrence of mucormycosis was not observed.

### 3. Discussion

Mucormycosis, previously termed as zygomycosis refers to several different infections caused by fungi belonging to the order mucorales. An increasing incidence of mucormycosis has been reported in India especially in individuals with uncontrolled diabetes and trauma. During the past two decades, mucormycosis has become the third most common invasive fungal infection in patients with hematological malignancies and organ transplantations.<sup>7</sup> The clinical presentation of mucormycosis depends on the patient's underlying medical condition. Rhino-orbitocerebral mucormycosis is the most common form (44-49%), followed by cutaneous (10-16%), pulmonary (10-11%), disseminated (6-11.6%), gastrointestinal (2-11%) and very rarely other miscellaneous form involving the bones, breasts, mediastinum and kidneys.<sup>8</sup> The species of the genus *Rhizopus* especially *R. oryzae* and *R. microsporus* is the most common etiological agent isolated and is responsible for 70% of all cases of mucormycosis. There were four known varieties of *R. microsporus* but only *R. microsporus* var. *microsporus* and *R. microsporus* var. *rhizopodiformis* have been reported as human pathogens.

Since the first case of pulmonary mucormycosis was documented in 1876 by Furbringer, there has been increase in reporting such cases.<sup>9</sup> Our report is a case of pulmonary mucormycosis in a patient with pulmonary tuberculosis, spontaneous pneumothorax and uncontrolled diabetes mellitus. Pulmonary mucormycosis occurs due to the inhalation of fungal spores into the bronchioles and alveoli, which typically results in the rapid progression of pneumonia or endobronchial disease. The clinical picture of pulmonary mucormycosis is non-specific even at late stages of infection and patients frequently have high-grade fever (>39°C), coughing, respiratory distress, weight loss, hemoptysis and pleuritic chest pain. In our case, the patient was tachypneic and had low-grade fever along with cough and mucopurulent expectoration.

In the present case, *R. microsporus* was identified as the etiological agent of pulmonary mucormycosis. The first case of *R. microsporus* infection as causative agent of rhino-orbital-cerebral mucormycosis in a diabetic patient was reported in India by Bhansali et al. in 2004.<sup>10</sup> Clinical and experimental data clearly demonstrate that numerous predisposing factors have been associated with mucormycosis, however diabetes is one of the important predisposing factors in at least 36% of cases. The patient had uncontrolled diabetes mellitus for the last three years and was under anti-tuberculosis therapy which is the predisposing factor in our study. Hyperglycemia is known

to enhance the fungal growth inside the human body and impairs neutrophil chemotaxis. Mucormycosis remains difficult to diagnose, hence early diagnosis and treatment are of extreme importance for successful eradication of the infection and for patient survival. Differential diagnosis of mucormycosis may be varied due to the different clinical presentations and organ systems involved. Therefore for a definitive diagnosis, histopathology, cytopathology, direct microscopic examination and culturing of necrotic tissue has to be considered. Several species of *Rhizopus* (*R. arrhizus*, *R. homothallicus*, *R. microsporus*, *R. schipperae* and *R. stolonifera*) are considered to cause life-threatening infections in humans and they share similar phenotypic characteristics. Current diagnosis of mucormycosis relies heavily on mycological culture, radiological and histopathological examination and diagnosis can only be definitive at a later stage of the disease, which prevents timely intervention.

Given the limitation of phenotypic identification methods wherein genus level identification is only possible, rDNA-based gene sequences are more precise in species identification of mucormycetes.<sup>11,12</sup> In this report, the etiological agent *R. microsporus* was identified phenotypically and based on PCR sequencing of the ITS region of the rDNA. The isolate had the characteristic features of fast-growing fibrous mycelium with right angle unbranched sporangiophore, multispored sporangia and rhizoids. The ITS sequence (673 bp) of *R. Microsporus* matched 100% with CBS 537.80 and ATCC 200758 and the nucleotide sequences were also deposited in GenBank with accession number MN177926 and the D1/D2 gene sequence with accession number MN197703. Treatment of mucormycosis is complex and there are no consensus treatment guidelines available. It is important to consider surgical debridement early in the disease course as the outcome in patients treated with a combined medical and surgical approach helps in successful treatment. Currently, the recommended antifungal therapy for pulmonary mucormycosis includes liposomal amphotericin B with a dose of 1.0-1.5 mg/kg/day.<sup>13</sup> Among azole antifungal drugs fluconazole, itraconazole, and voriconazole have poor or no activity against mucorales however, several clinical data supporting the use of newer triazoles including posaconazole and isavuconazole for treatment of mucormycosis.<sup>14</sup> The susceptibility data of the isolate shows that both Amphotericin B and azoles drugs were effective. The patient was treated with Amphotericin B and further recurrence of mucormycosis was not observed.

To date, only 17 cases of *R. microsporus* involving lungs as site of infection (pulmonary mucormycosis) has been reported in the literature and are listed in Table I.<sup>3-5,11,15-20</sup> The patients included 12 males and 5 females with the average age of 62 (28-88) years. 5 cases were reported from India, 4 from Belgium, 2 from

United States and one case each from United Kingdom, Kenya, Japan, Czechia, The Netherlands and South Korea. Pulmonary mucormycosis caused by *R. microsporus* occur in patient with different underlying conditions. Two of them were renal transplant patients, one had lung transplantation, two had myelodysplastic syndrome and one case each with myelofibrosis, bronchial asthma, pancytopenia, acute myeloblastic leukemia, steroid induced hyperglycemia, chronic obstructive pulmonary disorder, pulmonary tuberculosis, chronic myeloid leukemia, chronic kidney disease, acute lymphoblastic leukemia. Uncontrolled diabetes was noted as underlying disease in two reported cases. Of the total 12 patients reported, 9 had uncontrolled diabetes mellitus as the most common predisposing factor with other co morbidities. In 5 of the reported cases, the infection was diagnosed during post-mortem histological examination. Diagnosis of pulmonary mucormycosis is a challenging task as it shares several common features with pulmonary tuberculosis and pulmonary aspergillosis. In four of the reported cases, the conventional phenotypic methods such as culturing and microscopy were used in identifying the etiological agent to species level. Nine cases documented to have used either or both ITS and D1/D2 sequencing for species identification. Amphotericin B was the mainstay of treatment in 70% of the cases. The patients reported were either treated with amphotericin B alone or in combination with azoles such as posaconazole miconazole, voriconazole, micafungin, fluconazole, and itraconazole and only five of the cases were successful and 70% of them were fatal, 8/12 died of mucormycosis and four of the patients died due to other conditions such as enterocolitis, open lung biopsy, CMV infection and respiratory insufficiency. In addition to the 17 reviewed cases, Chowdhary et al., in 2014 reported six cases of pulmonary mucormycosis by *R. microsporus* from India.<sup>6</sup> Due to unavailability of clinical data, treatment and outcome, the cases were not included in this review. In the present study a case of pulmonary mucormycosis caused by *R. microsporus* was reported in a patient with pulmonary tuberculosis and diabetes mellitus and the etiological agent was identified by conventional phenotypic and PCR sequencing of both the ITS and D1/D2 region of the ribosomal DNA. The infection was successfully managed with Amphotericin B and strict glycemic control. In conclusion, pulmonary mucormycosis is a relatively rare but often fatal, rapidly progressive disease and share its clinical picture to that of pulmonary tuberculosis and pulmonary aspergillosis. Therefore it is necessary that the pulmonologists should have high index of clinical suspicion for pulmonary mucormycosis in susceptible patients with high risk factors including rapid progression of pneumonia, high grade fever and ineffective antibiotic treatment.

#### 4. Acknowledgment

The authors acknowledges DST, Govt. of India for funding this research work, Pfizer, NY, USA for the provision of

antifungal drugs and Superintendent, Government Hospital of Thoracic Medicine, Tambaram, Tamil Nadu, India for clinical specimens.

#### 5. Conflicts of interest

All contributing authors declare no conflict of interest.

#### 6. Source of Funding


None.

#### References

- Eucker J, Sezer O, Graf B, Possinger K. Mucormycoses. *Mycoses*. 2001;44(7-8):253–60.
- Alvarez E, Sutton DA, Cano J. Spectrum of zygomycete species identified in clinically significant specimens in the United States. *J Clin Microbiol*. 2009;47:1650–1656.
- Al-Sheikhli J, Taqi H, Drake J, Habib A. Rare cause of pulmonary cavitation in a 75-year old man. *BMJ Case Rep*. 2018;10:bcr2017222792. doi:10.1136/bcr-2017-222792.
- Pandey M, Singh G, Agarwal R, Dabasy Y, Jyotsna VP, Kumar R, et al. Emerging Rhizopus microspores infections in India. *J Clin Microbiol*. 2018;56(6):e00433–18. doi:10.1128/JCM.00433-18.
- Lyskova P, Zackova P, Petečuková V, Hubka V, Vašáková M, Matěj R, et al. Pulmonary mucormycosis caused by Rhizopus microsporus. *Klin Mikrobiol Infekc Lek*. 2013;19(4):132–7.
- Chowdhary A, Kathuria S, Singh PK, Sharma B, Dolatabadi S, Hagen F, et al. Molecular characterization and in vitro antifungal susceptibility of 80 clinical isolates of mucormycetes in Delhi. *Mycoses*. 2014;57(3):97–107. doi:10.1111/myc.12234.
- Roden MM, Zaoutis TE, Buchanan WL, Knudsen TA, Sarkisova TA, Schaufele RL, et al. Epidemiology and outcome of zygomycosis: A review of 929 reported cases. *Clin Infect Dis*. 2005;41(5):634–53. doi:10.1086/432579.
- Prabhu RM, Patel R. Mucormycosis and entomophthoromycosis: A review of the clinical manifestations, diagnosis and treatment. *Clin Microbiol Infect*. 2004;10(1):31–47. doi:10.1111/j.1470-9465.2004.00843.x.
- Fürbringer P. Observations on pulmonary mucormycosis in humans. *Virchows Arch Path Anat*. 1876;66:330–65.
- Bhansali A, Bhadada S, Sharma A, Suresh V, Gupta A, Singh P, et al. Presentation and outcome of rhino-orbital-cerebral mucormycosis in patients with diabetes. *Postgrad Med J*. 2004;80(949):670–4. doi:10.1136/pgmj.2003.016030.
- Kim MJ, Park PW, Ahn JY. Fatal pulmonary mucormycosis caused by Rhizopus microsporus in a patient with diabetes. *Ann Lab Med*. 2014;34(1):76–9.
- Abe A, Oda Y, Asano K, Sone T. The molecular phylogeny of genus Rhizopus based on rDNA sequences. *Biosci Biotechnol Biochem*. 2006;70(10):2387–93. doi:10.1271/bbb.60101.
- Severo CB, Guazzelli LS, Severo LC. Zygomycosis. *J Bras Pneumol*. 2010;36(1):134–41. doi:10.1590/S1806-37132010000100018.
- Marty FM, Ostrosky-Zeichner L, Cornely OA, Mullane K, Perfect JR, Thompson GR, et al. Isavuconazole treatment for mucormycosis: A single-arm open-label trial and case-control analysis. *Lancet Infect Dis*. 2016;16(7):828–37. doi:10.1016/S1473-3099(16)00071-2.
- Maniwa K, Tanaka E, Taguchi Y, Oida K, Inoue T, Kato T, et al. A case of abrupt pulmonary Infection by rhizopus microsporus var. rhizopodiformis during treatment for bronchial asthma The J of Jap Assoc for. *Kansenshogaku Zasshi*. 2002;76(5):396–9. doi:10.11150/kansenshogakuzasshi1970.76.396.
- De Mol P, Meis JF. Disseminated Rhizopus microsporus infection in a patient an oral corticosteroid treatment: a case report. *Neth J Med*.

- 2009;67(1):25–8.
17. Saegeman V, Maertens J. Epidemiology of mucormycosis: review of 18 cases in a tertiary care hospital. *Med Mycol.* 2010;48:245–254.
  18. Kogure Y, Nakamura F. Pulmonary mucormycosis with embolism: two autopsied cases of acute myeloid leukemia. *Int J Clin Exp Pathol.* 2014;7(6):3449–53.
  19. Tsyrukunou AV, Ellison R, Akalin A, Wiederhold N, Sutton DA, Lindner J, et al. Multifocal *Rhizopus microsporus* lung infection following brush clearing. *Med Mycol Case Rep.* 2014;6:14–7. doi:10.1016/j.mmcr.2014.08.001.
  20. Sharma D, Dahal K, Pathak B, Dahal U. Case of early-disseminated *Rhizopus microspores* var. *microspores* mucormycosis in a renal transplant patient. *Int Med Case Rep J.* 2016;9:139–43. doi:10.2147/IMCRJ.S100395.

### Author biography

**Umamaheswari K**, Associate Professor  <https://orcid.org/0000-0003-1528-4002>

**Gnanasekar R**, Research Student

**Sadagopan Kumar**, Clinician

**Cite this article:** Umamaheswari K, Gnanasekar R, Kumar S. *Rhizopus microsporus* pulmonary sepsis: Case report and review of literature. *IP Int J Med Microbiol Trop Dis* 2022;8(3):270-275.