

Content available at: <https://www.ipinnovative.com/open-access-journals>

IP International Journal of Medical Microbiology and Tropical Diseases

Journal homepage: <https://www.ijmmt.org/>

Case Report

A rare case of pelvic hydatidosis

Komali Jonnalagadda¹, Ajay Lucas^{2*}, Afwaan Faizal²

¹Dept. of Radio Diagnosis, Dr. Pinnamaneni Siddhardha Institute of Medical Sciences And Research Foundation, Vijayawada, Andhra Pradesh, India

²Dept. of Radio-Diagnosis, Saveetha Medical College and Hospital, Saveetha Institute of Medical and Technical Sciences (SIMATS), Saveetha University, Chennai, Tamil Nadu, India



ARTICLE INFO

Article history:

Received 06-02-2024

Accepted 18-03-2024

Available online 17-04-2024

Keywords:

Pelvic hydatidosis

Case report

Diagnosis

Imaging

ABSTRACT

This case report highlights the diagnostic intricacies and clinical implications of pelvic hydatidosis, particularly in the context of the Indian healthcare system. Despite being a rare occurrence, pelvic hydatidosis presents significant challenges in diagnosis and management, necessitating a comprehensive approach for optimal patient care. The case involved a 54-year-old male presenting with right thigh pain and a gradually enlarging groin and thigh swelling. Imaging studies revealed a large cystic lesion with multiple internal cysts extending into the pelvic cavity, suggestive of pelvic hydatidosis. Following confirmation of pelvic hydatidosis, the patient received a 7-day course of albendazole prior to undergoing surgical excision via laparotomy. The cystic mass located in the right thigh's medial aspect was successfully removed, with subsequent peritoneal irrigation and uneventful postoperative recovery. Oral albendazole was prescribed for 6 months, and at the 6-month follow-up, no signs of disease recurrence were observed. Histopathological examination confirmed the diagnosis, showcasing characteristic features of hydatid cysts. The rarity of pelvic hydatidosis compared to other forms of echinococcosis underscores the importance of maintaining a high index of suspicion, especially in regions where the disease is endemic. The complex socioeconomic landscape in India, characterized by poor sanitation and limited healthcare access, contributes to delayed diagnosis and increased morbidity rates.

This is an Open Access (OA) journal, and articles are distributed under the terms of the [Creative Commons Attribution-NonCommercial-ShareAlike 4.0 License](https://creativecommons.org/licenses/by-nc-sa/4.0/), which allows others to remix, tweak, and build upon the work non-commercially, as long as appropriate credit is given and the new creations are licensed under the identical terms.

For reprints contact: reprint@ipinnovative.com

1. Introduction

Pelvic hydatidosis, though an uncommon presentation of cystic echinococcosis, poses a significant diagnostic and therapeutic dilemma due to its elusive symptoms and atypical imaging findings.¹ Echinococcosis, caused by the larval stage of the tapeworm *Echinococcus Granulosus* (EG), typically affects the liver and lungs, with pelvic involvement accounting for a minute fraction of cases.²

In the Indian scenario, pelvic hydatidosis holds particular significance due to several factors. India is considered endemic for echinococcosis, with certain

regions exhibiting higher prevalence rates, especially in rural areas where agriculture and animal husbandry are prevalent occupations.² This endemicity increases the likelihood of encountering cases of pelvic hydatidosis, albeit relatively rare compared to other forms of the disease. The diverse socioeconomic landscape in India plays a role in the epidemiology of pelvic hydatidosis. Poor sanitation practices, inadequate healthcare access in remote areas, and limited awareness about parasitic infections contribute to underreporting and delayed diagnosis of this condition.³ Consequently, patients may present with advanced disease stages, leading to increased morbidity and mortality rates. The complexity of pelvic

* Corresponding author.

E-mail address: mslucas007@gmail.com (A. Lucas).

hydatidosis diagnosis and management is compounded by the anatomical intricacies of the pelvic region, often resulting in misdiagnosis or delayed treatment initiation due to nonspecific symptoms and its rarity. This delay not only worsens the patient's condition but also heightens the risk of intraoperative complications during surgical interventions.⁴ The socioeconomic burden in India is substantial, with prolonged hospitalizations, expensive diagnostic procedures, and extensive surgeries imposing significant financial strains, especially in resource-limited settings. Heightened awareness among healthcare professionals, targeted public health interventions focusing on prevention, and improved access to diagnostic and therapeutic facilities in endemic regions are crucial.⁵ Early detection and appropriate management strategies are imperative to mitigate the disease's impact and improve outcomes for affected individuals in India.⁶ This unique case of pelvic hydatidosis in a 52-year-old male underscores the necessity for a high index of suspicion in regions endemic to echinococcosis, emphasizing the importance of early recognition to prevent severe complications.

2. Case Summary

A 54-year-old male patient presented to Orthopaedic OPD with complaints of right thigh pain for 2 months. The patient had a history of RTA 3 years back for which he didn't receive any treatment/no imaging done. He complained of a small swelling in the right groin and thigh region with a gradual increase in size. There was associated dull aching pain. The patient is not a known case of diabetes/hypertension. Lab investigations revealed mildly increased leucocyte count (12320 cells/cu.mm), and mild anemia (9.1 g/dL). The rest of the laboratory investigations were normal (eosinophils 0.06×10^9 , neutrophils 1.5×10^9 , basophils 0.04×10^9 , monocytes 0.7×10^9). The patient was referred to radiology for further evaluation.

2.1. Ultrasound

Revealed a large well-defined cystic lesion of size 8.5 x 5 x 4.7 cm with multiple internal tiny cysts of varying sizes in the medial aspect of the right thigh in the intra-muscular plane. No evidence of internal echoes within the lesion. No significant intra/perilesional vascularity.

2.2. Computed tomography

A large fairly defined hypodense (likely cystic) lesion of size 8.7 x 5.2 x 5 cm with multiple internal tiny cysts of varying sizes in the medial aspect of the right thigh in the intra-muscular plane of the adductor compartment (Figure 1a). There was evidence of superior extension of the lesion into intramuscular (obturator internus and externus with few specks of calcifications within), intra-osseous (mentioned below), and intra-pelvic regions. There

was evidence of cortical discontinuity involving the right superior & inferior pubic rami, right acetabulum, and part of the humeral head- consistent with old fractures related to the history of trauma. There was intra-osseous extension of the lesion i.e. into the areas of probable old fracture. (Figure 1 b). There was a further extension of the lesion into the right hemipelvis abutting the right lateral border of the bladder and prostate. Further posterior extension into the right gluteal region was noted.

2.3. Magnetic resonance imaging

Showed a large well-defined altered signal intensity lesion of size 8.7 x 5.1 x 4.9 cm in the medial aspect of the right thigh in the intra-muscular plane of the adductor compartment. This appeared iso to hypointense on T1 with more hypointense internal cysts (Figure 2a) and hyperintense on T2 with more hyperintense internal cysts, (Figure 2b) with no suppression on fat-saturated sequence (STIR) (Figure 2c). There was no evidence of diffusion restriction. In the post-contrast study, there was evidence of peripheral and internal septal enhancement (Figure 1d).

Upon confirmation of the diagnosis of pelvic hydatidosis, patient was planned for surgical excision. Preoperatively patient was started on albendazole for 7 days and a laparotomy was conducted, revealing a cystic mass measuring approximately $8.7 \times 4 \times 4.5$ cm located in the medial aspect of the right thigh within the intra-muscular space of the adductor compartment. The cyst was surgically removed. Thorough peritoneal irrigation was performed using normal saline. The patient's recovery after surgery was uncomplicated. Oral albendazole was prescribed at a dosage of 400 mg twice daily for a duration of 6 months. At 6-month follow-up there was no clinical evidence of disease recurrence and follow up Ultrasound was normal, with no evidence of recurrence

2.4. Histopathological examination

The lesion was operated and the sample was sent for Histopathological examination (HPE). It revealed laminated eosinophilic membranes containing brood capsules with protoscolices and focal areas showing scattered foreign body types of giant cells containing fragments of laminated membranous within their cytoplasm. Thickened fibro-collagenous wall with focal laminated membranous infiltration by lymphocytes and foreign body type of multinucleated giant cells with fragments of laminated membranes within their cytoplasm. Focal areas of hemorrhage and calcification- Features consistent with Hydatid cyst with foreign body giant cell granulomatous reaction.

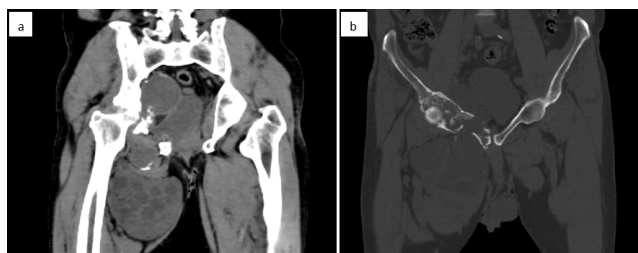

Figure 1: a: Non contrast CT Coronal reformatted image soft tissue window of pelvis; b: Non contrast CT Coronal reformatted image bone tissue window of pelvis

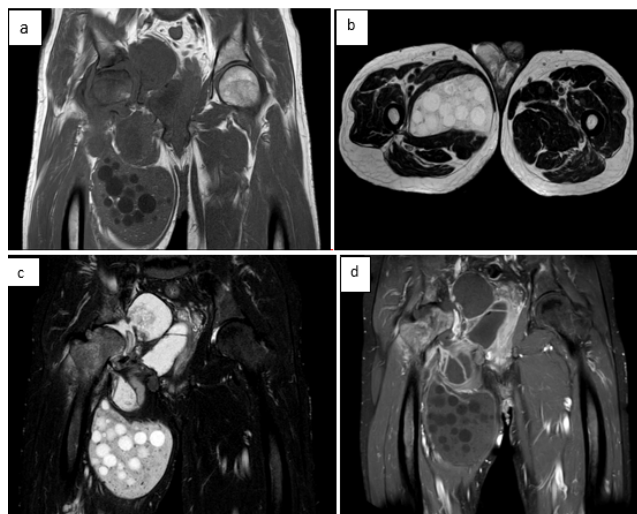


Figure 2: a: T1 weighted coronal image; b: T2 weighted non-FS axial sections at the level of proximal thigh; c: T2 weighted FS coronal section, d: T1 FS post contrast coronal section.

3. Discussion

The presented case highlights the diagnostic challenges and clinical implications associated with pelvic hydatidosis, especially in the Indian healthcare context. Pelvic involvement of echinococcosis, although rare, presents a unique set of diagnostic dilemmas due to its atypical presentation and imaging findings.

The rarity of pelvic hydatidosis in comparison to hepatic or pulmonary involvement underscores the importance of maintaining a high index of suspicion, particularly in regions endemic to echinococcosis like India. The diverse socioeconomic landscape of the country, characterized by poor sanitation, limited healthcare access in rural areas, and lack of awareness about parasitic infections, contributes to underreporting and delayed diagnosis of this condition. Consequently, patients may present with advanced disease stages, leading to increased morbidity and mortality rates.

Moreover, the anatomical complexity of the pelvic region poses challenges in both diagnosis and management. The nonspecific symptoms and imaging findings often

lead to misdiagnosis or delayed treatment initiation, further complicating the clinical course. In this case, the patient had a history of trauma, which may have contributed to the delay in seeking medical attention and the complexity of the lesion. The socioeconomic burden of pelvic hydatidosis cannot be underestimated, particularly in resource-limited settings like India.⁴ The disease necessitates prolonged hospitalizations, costly diagnostic evaluations, and extensive surgical interventions, placing a significant financial strain on affected individuals and healthcare systems.⁵

Fasihi et al present a 51-year-old Iranian man who presented to a healthcare facility with abdominal pain, revealing a case of primary disseminated intraabdominal hydatidosis with the involvement of multiple organs.⁷ Upon physical examination, two palpable abdominal masses were identified. Subsequent ultrasound and computed tomography scans unveiled the presence of six cystic lesions distributed across the liver, subhepatic region, pelvic area, and omentum. The patient underwent surgical intervention, leading to the complete removal of the cystic lesions. Postoperatively, the patient was prescribed albendazole at a dose of 400 mg/kg/day and advised to continue the treatment for a duration of 4 months. While primary disseminated intraabdominal hydatidosis is a rare occurrence, it carries significant clinical implications due to the fertility of cysts and the heightened risk of recurrence. Therefore, it is crucial to closely monitor such patients using imaging modalities and enzyme-linked immunosorbent assay for native antigen B (AgB). Additionally, postoperative albendazole therapy for a period of 4 months is recommended to minimize the risk of recurrence and ensure optimal patient outcomes.

Varediet al present and analyze a case of primary hydatidosis involving the pelvic cavity in a female patient who initially presented with significant weight loss and abdominal pain.⁸ This atypical presentation initially raised suspicion of a tumor process; however, surgical exploration and subsequent microscopic examination confirmed the diagnosis of a primary hydatid cyst. Gynecologists must recognize the potential occurrence of primary hydatid cysts within the pelvic cavity and include it in the differential diagnosis of cystic pelvic masses, particularly in regions where the disease is endemic.

Echinococcosis arises from the larval stage of EG. While the liver is the most commonly affected organ, occurrences in other body parts, such as bone involvement, are not uncommon, particularly in countries like India where cattle-raising is prevalent. Primary osseous echinococcosis often goes unnoticed until complications arise. Abhishek et al present a case of complicated pelvic echinococcosis, characterized by a left gluteal mass, destruction of the acetabulum and femoral head, and restricted hip mobility.⁹ Pre- and postoperative chemotherapy with albendazole,

along with en bloc surgical removal of the cyst, is the preferred treatment approach. It's crucial to consider primary osseous echinococcosis when encountering a case of chronic bony mass unresponsive to antitubercular therapy. Hydatid serology, along with comprehensive imaging and histopathological examinations, should be conducted to support or confirm the diagnosis and prevent long-term complications.

Bouihi et al present the case of a 24-year-old patient admitted with a massive pelvic mass accompanied by a sensation of heaviness but lacking additional signs. Ultrasound and CT scan revealed a septated, anechoic mass located laterally and subuterinely on the right side.¹⁰ The diagnosis of pelvic hydatid cyst was confirmed intraoperatively. Treatment involved resection of the protruding dome. The patient's condition improved significantly, with a favorable evolution observed over a three-year follow-up period.

4. Conclusion

The presented case of pelvic hydatidosis emphasizes the diagnostic challenges and clinical complexity associated with this rare condition, particularly in the Indian healthcare setting. Despite its rarity, pelvic hydatidosis should be considered in the differential diagnosis of patients presenting with chronic bony masses or abdominopelvic symptoms, especially in regions where echinococcosis is endemic. The case underscores the importance of thorough imaging evaluations, including ultrasound, CT, and MRI, along with histopathological examination, for accurate diagnosis and timely intervention.

5. Source of Funding

The authors declare that they have no financial support, and sponsorship was obtained for this research.

6. Conflict of Interest

The authors declare that they have no financial or non-financial conflict of interest.

7. Acknowledgments


The authors acknowledge the patient as a great source of learning.

References

1. Bhatnagar N, Kishan H, Sura S, Lingaiah P, Jaikumar K. Pelvic Hydatid Disease: A Case Report and Review of Literature. *J Orthop Case Rep.* 2017;7(4):25–8.
2. Pradhan A, Mallick B, Dash A, Nanda D. Clinical presentation and outcome of children with hydatid disease: a retrospective cross-sectional study from a tertiary care hospital in eastern India. *J Parasitol Dis.* 2021;46(1):230–5.
3. Sing P, Mushtaq D, Verma N, Mahajan NC. Pelvic hydatidosis mimicking a malignant multicystic ovarian tumor. *Korean J Parasitol.* 2010;48(3):263–5.
4. Bhattacharya A, Saha R, Mitra S, Nayak P. Primary hydatid cyst of broad ligament. *Trop Parasitol.* 2013;3(2):155–7.
5. Wani RA, Malik AA, Chowdri NA, Wani KA, Naqash SH. Primary extrahepatic abdominal hydatidosis. *Int J Surg.* 2005;3(2):125–7.
6. Paul S, Mandal S, Upadhyaya M, Pramanik SR, Biswas SC, Biswas RR, et al. Primary pelvic hydatid cyst in a postmenopausal female: a surgical challenge. *Autopsy Case Rep.* 2017;7(2):49–54.
7. Fasihi K, Bahreini A, Rafiei A, Dastyar A, Beirovand M. Primary disseminated intraabdominal hydatidosis: a case report. *J Med Case Rep.* 2022;16(1):35. doi:10.1186/s13256-022-03262-5.
8. Varedi P, Mostafavi S, Salouti SR, Saedi R, Nabavizadeh D, Samimi SA, et al. Hydatidosis of the pelvic cavity: a big masquerade. *Infect Dis Obstet Gynecol.* 2008;p. 782621. doi:10.1155/2008/782621.
9. Abhishek KS, Shrimali T, Tak V, Nag VL, Banerjee S, Khera S, et al. Primary pelvic echinococcosis though uncommon but not rare. *Trop Parasitol.* 2021;11(1):56–9.
10. Bouihi J, Moustaide H, Amrani BE, Mimouni A. Kystehydatiquepelvienprimitif: à propos d'un cas [Primary pelvic hydatid cyst: about a case. *Pan Afr Med J.* 2016;25:239. doi:10.11604/pamj.2016.25.239.11238.

Author biography

Komali Jonnalagadda, Senior Resident

Ajay Lucas, Junior Resident  <https://orcid.org/0009-0000-8522-3702>

Afwaan Faizal, Junior Resident

Cite this article: Jonnalagadda K, Lucas A, Faizal A. A rare case of pelvic hydatidosis. *IP Int J Med Microbiol Trop Dis* 2024;10(1):72-75.