

## Enteric protozoan parasitic infections in HIV seropositive individuals

Lalitha C<sup>1,\*</sup>, Sandhya Belwadi<sup>2</sup>, Sreenivasa Babu PR<sup>3</sup>

<sup>1</sup>Assistant Professor, <sup>2,3</sup>Professor, Dept. of Microbiology, Ramaiah Medical College, Bangalore

**\*Corresponding Author:**

Email: lalitha.ashu@gmail.com

### Abstract

**Background:** Parasitic infection of the intestinal tract is a major source of disease in patients with HIV particularly in the tropics where diarrhoea is a common complaint with variable severity and specific pathogens are to be identified in more than half of the HIV/AIDS patients with chronic diarrhoea.

**Objectives:** The objectives of this study was to identify the presence of intestinal protozoan parasites in HIV seropositive individuals & to compare the use of Formol ether sedimentation and Sheather's sugar floatation technique in identifying Cryptosporidium, Modified Trichrome and Calcofluor White stain to identify Microsporidia.

**Material and Methods:** A total of 78 HIV seropositive patients were included in the study from Oct 2003 to March 2004. Enteric protozoan parasitic infections were diagnosed by microscopic examination of stool specimens, which were examined as fresh wet mounts, stained smears like Modified Ziehl Neelsen, Modified Trichrome and Calcofluor white stain, Sheather's sugar floatation and Formol ether concentration techniques.

**Results:** In our study, 20 samples (25.6%) revealed the presence of enteric protozoan parasites, 10.25%, 9%, 5.12%, 1.3% showed the presence of Cryptosporidium, Giardia lamblia, Entamoeba histolytica and Isospora belli respectively.

**Conclusion:** The presence of different parasites in 25.6% of stool specimens of patients with HIV indicates that their specific diagnosis is essential. This will help initiate therapy to reduce morbidity and mortality among such patients due to these pathogens.

**Keywords:** HIV / AIDS; Cryptosporidium; Diarrhoea; Enteric Protozoan Parasites.

### Introduction

Human immunodeficiency virus infection has become a global epidemic far more extensive than what was predicted even a decade ago. The global spread has been so swift that no country has been spared and the pace of the epidemic is increasing in India.<sup>(1)</sup>

The progressive decline of immunological and mucous defense mechanisms predisposes patients to gastrointestinal manifestations of HIV infections.<sup>(2)</sup> Enteric protozoal infection is the commonest cause of diarrhoea in HIV seropositive persons. These protozoa cause disruption of small bowel villus architecture by unknown mechanisms which leads to malabsorption, indigestion and increase the bowel frequency leading to diarrhea. Symptoms persist despite starvation, and diarrhoea is often out of proportion to the mucosal abnormalities.

Changes in the immunological responses in the gut mucosa allow the persistence of protozoal infection in HIV seropositive individuals and abnormal immune responses themselves may be important in the pathogenesis of diarrhea. The CD4 lymphocyte population of the lamina propria in HIV seropositive patients shows a disproportionate reduction compared with the circulating CD4 count.<sup>(3)</sup> Studies conducted in Zaire and Uganda have shown the presence of some pathogenic agents responsible for the "Slim disease" such as Cryptosporidium, Isospora, Microsporidium, Cyclospora, Salmonella, Shigella and Campylobacter Species, amounting to a prevalence of 60 to 80%. "Slim disease" has been observed in advanced stages of HIV infection.<sup>(2)</sup> Opportunistic infections caused by intestinal

parasites vary according to the geographical area and the endemic levels in each location. Amongst the causes of diarrhea in developing countries, those of a parasitic origin are prominent in patients with AIDS.

After the emergence of AIDS, these parasites, until then known in veterinary medicine, are no longer considered as commensal organisms and are recognized as opportunistic pathogens common to these patients. Infections by these agents constitute a major secondary aggravating factor of the disease, often responsible for worsening the general health conditions, due to manifestations of diarrhoea which are difficult to control, sometimes resulting in the death of the patient.<sup>(2)</sup>

A number of studies have investigated the prevalence and epidemiology of **Cryptosporidiosis** in patients with HIV infection. The results of the studies investigating the prevalence of Cryptosporidiosis in HIV positive patients with diarrhoea have presented estimates that differ quite markedly from one another. It is not clear how much these differences may be explained by difference in study design, geographical location, population groups, and sensitivity of laboratory methods or stages of the disease.<sup>(4)</sup>

The proportion of the general population excreting oocysts is 1 to 3% in developed countries and 10% in developing countries. Cryptosporidial infection accounts for 2.2% (range 0.26 to 22%) of cases of diarrhoea in immunocompetent persons in developed countries and 6.1% (range 1.4 to 4.1%) of cases of diarrhoea in immunocompetent persons in developing countries. It occurs in upto 7% of children with diarrhoea in developed countries and upto 12% of children with

diarrhoea in developing countries. In developed countries it occurs in 14% (range 6 to 70%) of patients with AIDS and diarrhoea; in developing countries it occurs in 24% (range 8.7 to 48%) of such patients. In reports from north, south and east India *Cryptosporidium parvum* is the most common enteric protozoan parasite leading to chronic diarrheal disease in HIV infected persons.<sup>(5)</sup>

The current study was undertaken with the objective of identifying the presence of intestinal protozoan parasites in HIV positive individuals. The study would also compare the use of Formol ether sedimentation technique and Sheather's sugar floatation technique in identifying *Cryptosporidium* and also comparison of Modified Trichrome stain and Calcofluor White stain to identify *Microsporidia*.

### Material and Methods

The study was carried out in the Department of Microbiology, M.S. Ramaiah Medical College, Bangalore, over a period of one year. The HIV status of the subjects was confirmed as per National Aids Control Organization guidelines. Detailed clinical history of patients was obtained regarding the duration and frequency of diarrhoea, weight loss, loss of appetite, associated abdominal symptoms, vomiting and fever. Also the history of mode of transmission of HIV and associated opportunistic infections like Tuberculosis, Pneumonia and Oral thrush were noted.

Stool specimens were collected from these seropositive patients in a wide mouthed, clean, dry, plastic containers with tight fittings lids. The patients were asked to collect their stool sample preferably in the morning. They were instructed to avoid contamination of the stool specimen with urine or water

The specimens were brought to the laboratory without undue delay. Individuals submitting formed stools were instructed to submit another specimen if they passed loose stools subsequently. The specimens were labeled properly. The specimens were processed, and after processing they were preserved by adding 1-2gm of stool sample to 8-10ml of 10% formalin in the 15-30ml screw capped vials.

The stool samples were subjected to the following tests.

1. Wet mount of iodine and saline as preliminary rapid identification.<sup>(6)</sup>
2. Sedimentation technique: Formol ether concentration<sup>(6-8)</sup>
3. Floatation techniques: Sheather's sugar floatation technique<sup>(8,9)</sup>
4. Modified cold Ziehl Neelsen technique<sup>(7)</sup>
5. Modified Trichrome stain (Weber green)<sup>(9,10)</sup>
6. Calcofluor White stain

### Results

In the present study a total number of 78 HIV positive patients stool samples were examined to identify enteric protozoan parasites. This study was conducted at the Department of Microbiology, M.S. Ramaiah Medical College, Bangalore.

Out of the 78 HIV positive patients, 60 (77%) were male patients and 18 (23%) were female patients.

Amongst the male patients 20 (33.3%) belonged to the age group of 20-30years, 31 (51.7%) belonged to the age group of 31-40 years and 9 (15%) were >40 years of age. Amongst the female patients 8 (44.4%) belonged to the age group of 20-30 years, 7 (38.9%) belonged to the age group of 31-40 years and 3(16.7%) were >40 years of age.

Diarrhoea was the predominant presenting symptom among the 78 HIV positive patients in our study. Among the 78 HIV positive patients studied, 24 (30.8%) had acute diarrhoea, 36 (46.2%) had chronic diarrhoea. The second most common symptom among the HIV patients was fever (66.7%), followed by weight loss (51.3%), anorexia (42.3%) and pain abdomen (38.5%).

Enteric protozoan parasites identified in the stool samples collected from these patients included opportunistic and non-opportunistic pathogens. The opportunistic pathogens identified were *Cryptosporidium parvum* and *Isospora belli*. The non-opportunistic pathogens included *Giardia lamblia* and *Entamoeba histolytica*.

**Table 1: Enteric parasites detected in the HIV positive patients and their correlation with diarrhoea**

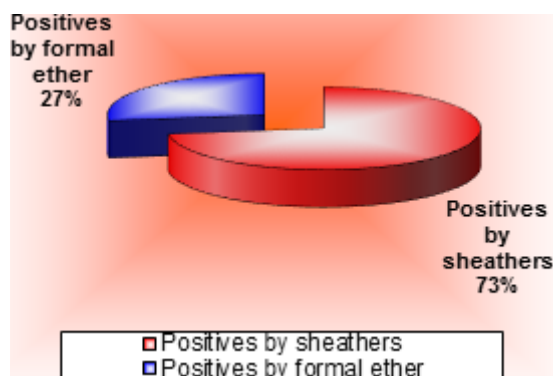
Protozoa	Acute diarrhoea (n=24)	Chronic diarrhoea (n=36)	No. diarrhoea (n=18)	Percentage
<i>Cryptosporidium parvum</i>	3	5	-	10.25
<i>Giardia lamblia</i>	4	2	1	9
<i>Entamoeba histolytica</i>	2	1	1	5.12
<i>Isospora belli</i>	-	1	-	1.3

Out of the 78 HIV patients in the study group stool samples from 20 (25.6%) patients showed the presence of enteric protozoan parasites. Stool samples from 8 patients (10.25%) showed the presence of *Cryptosporidium* species. All these patients had manifestations of diarrhoea, 3 of whom presented with acute diarrhoea and the other 5 with chronic diarrhoea. Stool samples from 7 patients (9%) showed the presence of *G. lamblia*. 4 of these patients suffered from acute diarrhoea, 2 of them from chronic diarrhoea, while 1 showed associated symptoms other than diarrhoea. 4 patients (5.12%) showed the presence of *E. histolytica* in their stool samples 2 of these patients had acute diarrhoea and 1 patient had chronic diarrhoea, while 1 had no diarrhoea.

*Isospora belli* was demonstrated in the stool sample of 1 (1.3%) patient who presented with chronic diarrhoea.

A total of 8 (10.25%) patients had *Cryptosporidium* infection. Occurrence of *Cryptosporidiosis* was found to be higher in male patients, 7 out of 60 (11.7%) as compared to female patients 1 out of 18 (5.6%). Occurrence of *Cryptosporidiosis* was found to be almost the same about, 10.71%, 10.52% and 8.33% in the age groups 20-30 years, 31-40 years and > 40 years respectively.

Out of the eight *Cryptosporidium* positive cases, all eight of them were detected by Sheather's Sugar floatation technique and only 3 were detected by Formol ether concentration technique.



**Fig.1: Comparative results of Sheather's sugar floatation and Formol ether concentration techniques**

*Cyclospora* and *Microsporidium* were not seen in the present study because of striking geographical variations in the prevalence of individual pathogens in HIV infected patients.

## Discussion

Gastrointestinal involvement in HIV/AIDS is almost universal and significant disease occurs in 50-96% of patients. Infectious causes of diarrhoea have been found in 30-80% of patients and the etiology for such diarrhoea could be either parasitic bacterial, fungal, enteric viruses or HIV itself.

In the present study, a total of 78 HIV seropositive patients were studied. Majority of the patients (84.6%) belonged to the age group of 20-40 years. Similar age related data has been provided by other authors<sup>(11)</sup> in their studies carried out on HIV positive patients. There were 77% of males in comparison to 23% of females with male to female ratio being 3.3:1. This male preponderance in the present study also coincides with the findings of other authors.<sup>(11)</sup>

In the present study 38.5% of patients suffered with diarrhoea (acute and chronic). Prevalence of diarrheal illness in HIV seropositive patients ranging from 28% to 42% has also been documented by other authors.<sup>(11,12)</sup> 25.6% of patients in the present study suffered from protozoal infestations. A prevalence of rate of 12.5% and 27.9% has also been observed in other studies.<sup>(12)</sup>

The following table shows the parasitic profile of the protozoan parasites in HIV positive patients in various National and International studies over the past 7 years.

**Table 2: Parasitic profile of the protozoan parasites in HIV positive patients in various National and International studies**

Protozoa	Talib et al.	Mukhopadhyya et al.	Ayyagari et al.	Vijaya D et al.	KN Prasad et al.	Alejandro Caraballo et al.
<i>Cryptosporidium parvum</i>	6.25%	10%	-	30%	11%	14%
<i>Isospora belli</i>	1.25%	18%	16.6%	5%	3.1%	22.8%
<i>Giardia lamblia</i>	2.50%	15%	-	10%	-	-
<i>Entamoeba histolytica</i>	2.50%	-	-	7.5%	11.5%	-

**Table 3: Parasitic profile of the protozoan parasites in HIV positive patients in various National and International studies**

Protozoa	Rakesh Sehgal et al.	Joshi M et al.	S.S. Kumar et al.	Singh A et al.	Renuka Bajaj	Mohammed Awole et al.	Indrani Banerjee et al.	Present study
Cryptosporidium parvum	1.8%	8.5%	17%	47%	18%	11%	15.5%	10.25%
Isospora belli	2.5%	17%	18.6%	-	-	7.4%	19.7%	1.3%
Giardia lamblia	8.3%	5.3%	-	-	5%	-	5%	9%
Entamoeba histolytica	1.7%	14.9%	-	-	3%	-	-	5.12%

The parasitic profile seen in the present study goes with the study of other authors, in their study on prevalence of intestinal parasitic pathogens in HIV seropositive individuals in Northern India<sup>(13)</sup> In the present study detection of Cryptosporidium (10.25%) was consistent with the findings of studies by other authors.<sup>(12-9)</sup> The occurrence of Giardia lamblia (9%) and E.histolytica (5.12%) tallies with other studies.<sup>(12,13,20-22)</sup> Evidence of Isospora belli (1.3%) in the present study correlates with studies by other authors.<sup>(12,13,23)</sup>

Other enteric protozoal pathogens causing infections in HIV seropositive patients like Cyclospora and Microsporidium were not seen in the present study because of striking geographical variations in the prevalence of individual pathogens in HIV infected patients.

#### Staining and Concentration techniques:

A definitive diagnosis of most of the parasitic infections depends on the demonstration of trophozoites, ova and cyst. This is traditionally done by stool microscopic examination, which is the gold standard in the diagnosis of intestinal parasitic infections.

In the study done by Ma Pearl and Rosemary Soave, the three step stool examination for Cryptosporidiosis in 10 homosexual men with protracted watery diarrhoea, established that, iodine wet mount as the preliminary rapid identification, modified Ziehl Neelsen stain and Sheather's sugar coverslip floatation for concentrating the oocysts.<sup>(24)</sup> In the present study similar three step stool examination was adopted for the detection of coccidian parasites and this yielded a positivity rate of 25.6%.

A comparative study done by Gagandeep Kang et al by comparing five staining methods for detection of Cryptosporidium oocysts in faecal specimens from the field, and in another study done by MacPherson and McQueen in multiattribute evaluation of six diagnostic methods, ranks the Modified Ziehl Neelsen stain as the best method for staining Cryptosporidium oocysts.<sup>(25,26)</sup> This staining method used in our study showed a clear distinct morphological appearance and bright pink appearance of oocyst which helps to spot the parasite in a pale green/ blue background.

In the present study Sheather's sugar floatation technique yielded better results when compared to Formol ether concentration technique. This

methodology correlates with the study done by Khubnani Harish et al, in their study of Cryptosporidiosis in a rural area of Maharashtra.<sup>(27)</sup>

#### Conclusion

The present study also shows that Cryptosporidium is the predominant enteric protozoan parasite in India particularly south India. We also conclude that special staining methods like Modified Ziehl Neelsen stain and concentration method like Sheather's sugar floatation technique should be employed as part of routine testing for the detection of intestinal protozoa in HIV seropositive patients. This will guide the clinicians to start an early and appropriate treatment and thus improve the quality of life of such patients. With better knowledge and diagnosis of the opportunistic infections in HIV patients, a better picture will emerge regarding these infections, which would help clinicians and health planners to tackle the AIDS epidemic in a more effective manner.

#### References

1. Kumarasamy N, Solomon S, Flanigan TP, Hemalatha R, Thyagarajan SP, Mayer KH. Natural history of human immunodeficiency virus disease in southern India. Clin Infect Dis Off Publ Infect Dis Soc Am. 2003 Jan 1;36(1):79-85.
2. Cimerman S, Cimerman B, Lewi DS. Enteric parasites and AIDS. Sao Paulo Med J Rev Paul Med. 1999 Nov 4;117(6):266-73.
3. Sharpstone D, Gazzard B. Gastrointestinal manifestations of HIV infection. Lancet Lond Engl. 1996 Aug 10;348(9024):379-83.
4. Hunter PR, Nichols G. Epidemiology and clinical features of Cryptosporidium infection in immunocompromised patients. Clin Microbiol Rev. 2002 Jan;15(1):145-54.
5. Kumarasamy N, Vallabhaneni S, Flanigan TP, Mayer KH, Solomon S. Clinical profile of HIV in India. Indian J Med Res. 2005 Apr;121(4):377-94.
6. Chatterjee KD. Textbook of Parasitology. In: 12th ed. Calcutta: Chatterjee medical publishers; 1980. p. 208-12.
7. Weltgesundheitsorganisation, editor. Basic laboratory methods in medical parasitology. Geneva; 1991. 114 p.
8. Gillespie SH, editor. Medical parasitology: a practical approach. Oxford: IRL Press; 1995. 12 p. (The practical approach series).
9. Koneman EW, editor. Color atlas and textbook of diagnostic microbiology. 5. ed. Philadelphia: Lippincott; 1997. 1395 p.

10. Forbes BA, Sahm DF, Weissfeld AS. Bailey & Scott's diagnostic microbiology. 11<sup>th</sup> ed. St. Louis: Mosby; 2002. 1069 p.
11. ayyagari A. Spectrum of opportunistic infections human immunodeficiency virus infected cases in a tertiary care hospital. *IJMM*. 1999;17(2):78–80.
12. Talib SH, Singh J. A study on opportunistic enteric parasites in 80 HIV seropositive patients. *Indian J Pathol Microbiol*. 1998 Jan;41(1):31–7.
13. Mohandas null, Sehgal R, Sud A, Malla N. Prevalence of intestinal parasitic pathogens in HIV-seropositive individuals in Northern India. *Jpn J Infect Dis*. 2002 Jun;55(3):83–4.
14. Mukhopadhyaya A, Ramakrishna BS, Kang G, Pulimood AB, Mathan MM, Zachariah A, et al. Enteric pathogens in southern Indian HIV-infected patients with & without diarrhoea. *Indian J Med Res*. 1999 Mar;109:85–9.
15. Prasad KN, Nag VL, Dhole TN, Ayyagari A. Identification of enteric pathogens in HIV-positive patients with diarrhoea in northern India. *J Health Popul Nutr*. 2000 Jun;18(1):23–6.
16. Joshi M, Chowdhary AS, Dalal PJ, Maniar JK. Parasitic diarrhoea in patients with AIDS. *Natl Med J India*. 2002 Apr;15(2):72–4.
17. Awole Mohammed et al. Prevalence of intestinal parasites in HIV infected adult patients in Southwestern Ethiopia. *Ethiop J Health Dev*. 2003;17(1):471–8.
18. Kumar SS, Ananthan S, Lakshmi P. Intestinal parasitic infection in HIV infected patients with diarrhoea in Chennai. *Indian J Med Microbiol*. 2002 Jun;20(2):88–91.
19. Singh A, Bairy I, Shivananda PG. Spectrum of opportunistic infections in AIDS cases. *Indian J Med Sci*. 2003 Jan;57(1):16–21.
20. Vijaya D, L Chandramma. Cryptosporidium and other parasites in AIDS patients with chronic diarrhoea. *Karnataka journal of medical sciences*. 2004;4(4):8–11.
21. Bajaj Renuka et al. Prevalence of intestinal protozoa in HIV seropositive patients with special reference to Cryptosporidiosis. *Journal of parasitic diseases*. 2003;27(1):29–32.
22. Banerjee I, Primrose B, Roy S, Kang G. Enteric parasites in patients with diarrhoea presenting to a tertiary care hospital: comparison of Human Immunodeficiency Virus infected and uninfected individuals. *J Assoc Physicians India*. 2005 May;53:492.
23. Caraballo Alejandro et al. Intestinal parasitic infections in HIV positive individuals in Southeastern Venezuela. *Bol Chil Parasitol Santiago*. 2001;57:3–4.
24. Ma P, Soave R. Three-step stool examination for cryptosporidiosis in 10 homosexual men with protracted watery diarrhea. *J Infect Dis*. 1983 May;147(5):824–8.
25. MacPherson DW, McQueen R. Cryptosporidiosis: multiattribute evaluation of six diagnostic methods. *J Clin Microbiol*. 1993 Feb;31(2):198–202.
26. Kang G, Mathan MM. A comparison of five staining methods for detection of Cryptosporidium oocysts in faecal specimens from the field. *Indian J Med Res*. 1996 May;103:264–6.
27. Khubnani H, Sivarajan K, Khubnani AH. Study of cryptosporidiosis in a rural area of Maharashtra. *Indian J Pathol Microbiol*. 1997 Jan;40(1):33–6.