

Corynebacterium tuberculostearicum a potential pathogen in breast abscess- A case report

Prashant Mule^{1,*}, Niranjan Patil², Seema Gaikwad³

Consultant Microbiologist, Dept. of Microbiology, Metropolis Healthcare Ltd. Mumbai, Maharashtra, India

***Corresponding Author:**

Email: prashant.mule88@gmail.com

Abstract

Gram positive, aerobic rods belonging to the genus *Corynebacterium* colonize the skin and mucosal surfaces of humans. They are frequently isolated from various clinical specimens. Interpretation of their clinical relevance is often difficult. Lipophilic corynebacteria are a particularly relevant subgroup of corynebacteria since they might be involved in infections of hospitalized patients and often multidrug resistant to commonly used antimicrobials. *Corynebacterium tuberculostearicum* is a lipophilic corynebacterium characterized in the year 2004. Routine biochemical tests do not provide reliable identification of *C. tuberculostearicum*. The present case report include its identification by matrix-assisted laser desorption ionization–time of flight mass spectrometry (MALDI-TOF MS). MALDI-TOF MS represents a helpful tool for the identification of this species. Due to the challenging identification of *C. tuberculostearicum*, we presume that this organism is often misidentified and its clinical relevance is underestimated. We report a case of inflammatory breast abscess from whom *Corynebacteria* was isolated and we discuss the potential significance of this organism.

Keywords: *Corynebacterium tuberculostearicum*, lipophilic, multidrug resistant, MALDI-TOF MS, breast abscess.

Introduction

Several *Corynebacterium* species have been implicated in human disease. *Corynebacterium diphtheriae* and *Corynebacterium jeikeium* are well-recognized pathogens, but others, including *Corynebacterium striatum*, *Corynebacterium xerosis*, *Corynebacterium minutissimum*, *Corynebacterium urealyticum*, and *Corynebacterium amycolatum*, have been implicated in wound and urinary tract infections.¹ Gram-positive, aerobic rods belonging to the genus *Corynebacterium* colonize the human skin and mucosal surfaces. They are frequently isolated from clinical specimens. As they are normal skin flora, it can be difficult to distinguish between infection, colonization, and contamination with these organisms. Their clinical relevance is often difficult to interpret. Lipophilic corynebacteria are particularly a relevant subgroup of corynebacteria since they might be involved in infections of hospitalized patients and often show resistance to commonly used antimicrobials.¹ In 1984, Brown et al. studied 16 so-called leprosy-derived coryneform (LDC) strains and named the isolates “*C. tuberculostearicum*” because their fatty acid profile comprised tuberculostearic acid.² Funke et al. proposed that the presence of gram-positive bacilli (GPB) associated with polymorphonuclear cells (PMNs) in the clinical specimen is strong evidence for their causal role as a pathogen. Repeated and pure isolation of GPB on cultures of tissue specimens also supports this role.

Case Report

A 39 year old woman presented with pain and swelling in the right breast associated with high grade fever since 5 days. On physical examination there was swelling and tenderness in the right quadrant with

erythema. The left breast appeared to be normal. There was no history of trauma or any surgical procedures in the past. No other systemic abnormality found. The patient was diagnosed as a case of right breast abscess and given a 5 days course of Amoxicillin and Clavulanic acid along the analgesics and antipyretics. After three days of antibiotic treatment patient revisited the clinic and presented with similar clinical features. Patient did not respond to the drug prescribed. Real time ultrasonography of both breasts was performed with 5. To 10.0 MHZ linear transducer with tissue harmonics. There was large ill-defined heterogeneous lesion noted in the right breast mainly in the right lower outer quadrant with fewer hyper echoic moving internal echoes within measuring 65×67×37 mm with volume of 87 CC likely to be suggestive of partly liquid abscess. There was no abnormality with nipple and sub areolar region. Few enlarged lymph nodes are seen in the right axilla largest measuring 25×8 mm. Patient was taken for incision and drainage. Incision and drainage was done the pus drained was sent for microbiological examination. The Gram stain showed small stout Gram positive bacilli with numerous polymorphonuclear leucocytes (Fig. 2). Blood agar showed pure growth of small shiny around 1 mm diameter convex colonies with slight hemolysis (Fig. 1). MacConkeys agar did not show any growth. Initially they were thought to be contaminants. On further clinical information, colonies from blood agar were processed on Vitek MS MALDI-TOF (Matrix assisted light desorption Ionization- Time of Flight Mass Spectrometry). Vitek MS MALDI-TOF (Biomérieux, France) identified the colonies as *Corynebacterium tuberculostearicum*. Antimicrobial susceptibility was performed on Vitek Compact 2. Based on the antimicrobial susceptibility pattern

(table1) Vancomycin was infused i.v over 1hour with dose of 1.0 gram twice a day. Patient has improved dramatically after 48 hours of Vancomycin. Fever and other systemic manifestations subsided. Patient was discharged on day 7 of Vancomycin.

Table 1: Antimicrobial susceptibility pattern of *Corynebacterium tuberculostearicum*

Antimicrobial	MIC range	Observed MIC
Vancomycin	0.5–2	0.5
Linezolid	0.5–1	0.5
Penicillin	0.125–32	>32
Amoxicillin-clavulanate	0.125–256	>256
Erythromycin	0.125–256	>256
Gentamicin	0.06–64	64
Ciprofloxacin	0.125–32	>32
Rifampicin	0.06–32	16
Clindamycin	0.5–256	>256
Tetracycline	0.05–32	32



Fig. 1: Blood agar showing small shiny 1-2 mm diameter convex colonies with slight hemolysis

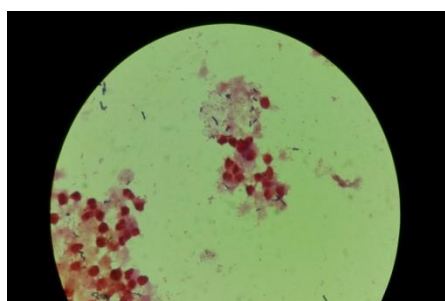


Fig. 2: Gram stain of aspirated pus showing GPB with polymorphonuclear leucocytes

Discussion

We have presented a case of right breast abscess with growth of *C. tuberculostearicum* isolated from aspirated pus. *C. tuberculostearicum* is a lipophilic species³ about which very little information is available in the current literature. Cells are pleomorphic, Gram-positive rods, non-motile and non-spore-forming, developing coccoid forms in stationary cultures. Colonies on blood agar supplemented with Tween 80 are circular, convex, glistening and 1 mm in diameter. They are aerobic and facultatively anaerobes. Oxidase

is negative and catalase is positive. Urea, gelatin and esculin are not hydrolysed. Presence of nitrate reductase is variable. *Corynebacterium mycolic* acids are present and the fatty acid profiles contain tuberculostearic acid.

It has been reported that the identification of lipophilic corynebacteria could be quite challenging because most species show identical phenotypic characteristics when investigated with routine microbiological methods.^{4,5}

The majority of the strains of *Corynebacterium* investigated, exhibited resistance to at least one antimicrobial agent in three or more antimicrobial categories, which makes them multiresistant organisms.⁶ The strain that we have isolated was susceptible to vancomycin and linezolid (Table 1). These results are in concordance with previously published data on the multiple antimicrobial resistance of investigated CDC group G-2 isolates and, conversely, their 100% susceptibility to vancomycin.^{7,8} Vancomycin may therefore represent the empirical therapeutic option for serious infection while awaiting results of susceptibility testing since vancomycin is the treatment of choice for other multiresistant corynebacteria.⁹ The fact that the patient had good clinical response to the vancomycin treatment elucidates the potential clinical impact of *C. tuberculostearicum*.

There are few literatures which primarily described the role for this bacterium in the etiology of chronic osteomyelitis and mastitis^{10,11}. The latter (i.e. mastitis) highlights its potential relevance in fatty tissue infections and also elucidates its potential role in infections emerging from inflammatory fatty tissue such as breast. 15 of the 18 patients presented in Hinic et al's article¹⁰ had a history of long hospital stays, and a majority had undergone prolonged therapy with broad-spectrum antimicrobials. This emphasizes the role of *C. tuberculostearicum* in nosocomial infections. The patient presented in this case had no prior hospital admission and only been treated with amoxicillin-clavulanic acid. However, upon hospitalization broad-spectrum antimicrobial therapy with vancomycin was initiated. Furthermore, the patient did not have any underlying comorbidity.

The presence of GPB in the specimen surrounded by inflammatory cells and repeated isolation of corynebacteria in the consecutive specimens from the same site suggests a possible role in pathogenesis (Fig 2). Although corynebacteria are associated with mastitis in animals¹ there have only been a few case reports that have implicated corynebacteria in suppurative breast disease.¹²⁻¹⁵

It is probable that corynebacteria present in breast specimens may be overlooked. Initially this isolate was considered as a potential contaminant from clinical specimen. Presence of inflammatory cells along with GPB without any evidence of other organisms suggest the possible role of this organism in causing breast

abscess. Performing antimicrobial susceptibility is of utmost important as these isolates of corynebacteria are multidrug resistant. Vancomycin remains the treatment of choice in such cases.

Conclusion

Corynebacterium species isolated from clinical specimens are usually considered contaminants. Any Gram positive bacilli isolated should be correlated clinically and its significance should be evaluated. Repeated isolation from the same site is of more clinical importance. MALDI- TOF MS plays an important role in the identification of *Corynebacterium* species like *C. tuberculostearicum* as conventional biochemical reactions lack sensitivity in its identification. Presence of gram positive bacilli along with polymorphonuclear leucocytes indicates active infection and should have high index of clinical suspicion as these organisms are multidrug resistant and difficult to treat.

References

1. Funke G, von Graevenitz A, Clarridge JE, Bernard KA. 1997. Clinical microbiology of coryneform bacteria. Clin. Microbiol. Rev. 10:125–159.
2. Brown S, Lan elle MA, Asselineau J, Barksdale L. 1984. Description of *Corynebacterium tuberculostearicum* sp. nov., a leprosy-derived *Corynebacterium*. Ann. Microbiol. (Paris) 135B:251–267.
3. Feurer C, et al. 2004. Taxonomic characterization of nine strains isolated from clinical and environmental specimens, and proposal of *Corynebacterium tuberculostearicum* sp. nov. Int. J. Syst. Evol. Microbiol. 54:1055–1061.
4. Riegel P, et al. 1995. Genomic diversity and phylogenetic relationships among lipid-requiring diphtheroids from humans and characterization of *Corynebacterium macginleyi* sp. nov. Int. J. Syst. Bacteriol. 45:128–133.
5. Watts JL, Lowery DE, Teel JF, Rossbach S. 2000. Identification of *Corynebacterium bovis* and other coryneforms isolated from bovine mammary glands. J. Dairy Sci. 83:2373–2379.
6. Magiorakos AP, et al. 2012. Multidrug-resistant, extensively drug-resistant and pandrug-resistant bacteria: an international expert proposal for interim standard definitions for acquired resistance. Clin. Microbiol. Infect. 18:268–281.
7. Weiss K, Lavardi re M, Rivest R. 1996. Comparison of antimicrobial susceptibilities of *Corynebacterium* species by broth microdilution and disk diffusion methods. Antimicrob. Agents Chemother. 40:930–933.
8. Williams DY, Selepek ST, Gill VJ. 1993. Identification of clinical isolates of nondiphtherial *Corynebacterium* species and their antibiotic susceptibility patterns. Diagn. Microbiol. Infect. Dis. 17:23–28.
9. Meyer DK, Reboli AC. 2005. Other coryneform bacteria and Rhodococcus, p 2465–2478. In Mandell GL, Bennett JE, Dolin R (ed), Mandell, Douglas, and Bennett's principles and practice of infectious diseases, 6th ed, vol 2. Churchill Livingstone. Philadelphia, PA.
10. Hinic V, Lang C, Weisser M, Straub C, Frei R, Goldenberger D. *Corynebacterium tuberculostearicum*: a potential misidentified and multiresistant *Corynebacterium* species isolated from clinical specimens. J Clin Microbiol 2012;50(8):2561–7.
11. Paviour S, MUSAAD S, Roberts S, Taylor G, Taylor S, Shore K, et al. *Corynebacterium* species isolated from patients with mastitis. Clin Infect Dis 2002;35:1434–40.
12. Phillips S, Bracis R. Recognition of *Corynebacterium* group G-2 as a cause of infection. Clin Microb News 1991; 13:78–80.
13. Binelli C, Lorimier G, Bertrand G, Parvery F, Bertrand AF, Verri le V. Granulomatous mastitis and corynebacteria infection: two case reports [in French]. J Gynecol Obstet Biol Reprod (Paris) 1996; 25:27–32.
14. Kumari P, Levy CS, McHenry KS, Fedorko D, Lucey DR. *C. amycolatum*: a novel cause of breast abscess. Infect Dis Clin Prac 2000; 9:179–81.
15. Stone N, Gillett P, Burge S. Breast abscess due to *Corynebacterium striatum*. Br J Dermatol 1997; 137:623–5.