

Disseminated cryptococcosis in an AIDS patient

Vaibhav V. Rajhans^{1*}, S. Roushani², D.S. Bhalerao³, S.C. Deorukhkar⁴, V.L. Kulkarni⁵

^{1,4,5}Assistant Professor, ²Professor and HOD, ³Professor, ¹⁻⁵Dept. of Microbiology, Rural Medical College, Loni, Maharashtra, India

*Corresponding Author: Vaibhav V. Rajhans

Email: vaibhavrajhans@gmail.com

Abstract

Humans live in peaceful coexistence with the microorganisms, but sometimes infectious conditions emerge. An increased incidence of invasive fungal infections is being observed recently. Yeasts and moulds now rank amongst the 10 most frequently isolated fungal pathogens among seriously ill patients. *Cryptococcus neoformans* is one of the common causes of meningitis in human immunodeficiency virus (HIV) infected individuals. Previously considered a sleeping giant, *Cryptococcus neoformans*, has now become an important emerging threat after the acquired immunodeficiency syndrome (AIDS) pandemic. Cryptococcosis is the first illness to appear in around 45% of the cases, among the AIDS defining illnesses. We report a case of disseminated cryptococcosis in an AIDS patient. *C. neoformans* was isolated from Cerebrospinal fluid and blood as well. Novel strategies of screening and pre-emptive therapy offer great promise at making a sustained and much needed impact on reducing morbidity related opportunistic infections. We emphasize the importance of early suspicion of cryptococcal infection in AIDS patients to escalate early diagnosis and treatment.

Keywords: Cryptococcosis, *Cryptococcus neoformans*, AIDS, Blood culture, Meningitis, Disseminated cryptococcosis.

Introduction

Human beings, most of the times, are able to live in peaceful coexistence with almost all microorganisms present around them. An infectious condition may emerge only when the immune system is compromised or the concentration of pathogenic microorganisms reach an exceptionally high density. Prions, viruses, bacteria & parasites; all have been incriminated in infectious disease conditions, but since last few decades, an increased incidence of invasive fungal infections is being observed. Fungi are remarkable organisms constituting a separate kingdom in classification; of which, yeasts and moulds now rank amongst the 10 most frequently isolated fungal pathogens among seriously ill patients.¹

The true yeast, *Cryptococcus neoformans*; a capsulated fungus from the family Basidiomycetes,² can produce sub-acute or chronic, pulmonary infections, meningeal infections or systemic infections and is often recovered from immuno-compromised patients. In fact, *C. neoformans* is one of the common causes of meningitis in human immunodeficiency virus (HIV) infected individuals.³

Cryptococcal infection commonly can occur by direct inhalation of either poorly encapsulated yeast cells or the basidiospores present in environmental reservoirs. *C. neoformans* is found throughout the world in association with excreta from birds like pigeons, environmental scavengers such as amoeba and sow bugs; and in a variety of trees.⁴ Previously considered a sleeping giant, *Cryptococcus neoformans*, has now become an important emerging threat after the acquired immunodeficiency syndrome (AIDS) pandemic.⁵

We, hereby report a rare case of disseminated cryptococcosis in an immuno-compromised patient.

Case History

A 50 year old female patient was admitted to the Pravara Rural hospital, Loni, Maharashtra with complains of on and

off fever and weakness for last one month. The patient was a known case of HIV infection since last five years. Multiple specimens of the patient were received in microbiology laboratory including blood and cerebrospinal fluid (CSF).

Blood culture was processed in BacT/ALERT 3D 120 automated aerobic blood culture system. The bottle was flagged positive by the machine after 48 hours and contents of the same were used for sub-culture on Blood agar (BA) (Image-1) and MacConkey's agar (MA). After overnight incubation at 37°C, the growth obtained was subjected to further analysis. Gram staining of the colony smear (Image-2) showed gram positive spherical budding yeast cells. Negative staining of the colonies with India ink (Image-3) showed spherical yeast cells with clear haloes. The colonies on BA were subjected to conventional tests and Vitek-2 compact system for identification and antifungal susceptibility. The isolate was identified as *Cryptococcus neoformans*, sensitive to amphotericin-B. Other antifungals like fluconazole, caspofungin, micafungin & voriconazole were reported as 'unclaimed' by the Vitek-2 system.

The colonies on BA were also subcultured on Sabouraud Dextrose Agar (SDA). Growth of *Cryptococcus*; confirmed by Gram staining and negative staining. Christensen Urease agar was inoculated for Urease test. Urea was hydrolysed.

CSF sample also showed similar findings in direct microscopy - gram positive spherical budding yeast cells in Gram staining (Image-4) and capsulated yeast cells in negative staining by India ink (Image-5). CSF culture isolate (Image-6), was identified on Vitek-2 system; as *Cryptococcus neoformans* which showed similar findings as that of growth from the blood culture.

Sputum sample of the patient was processed on GenExpert [cartridge-based nucleic acid amplification test (CBNAAT)] for *Mycobacterium tuberculosis*, which turned out to be negative. Aerobic culture, Gram & Acid fast

bacilli (AFB) staining of the sputum revealed no significant findings. Urine culture also was negative for cryptococcus.

In serology, serum sample was reactive for HIV-1 antibodies by Tri-Dot test and by chemi luminescent immuno assay (CLIA) on Vitros 3600 by Ortho clinical diagnostics. Hepatitis B surface antigen (HBsAg) and antibodies to *Treponema pallidum* by CLIA were negative.

CSF cytology revealed presence of capsulated yeast like cells, on May-Grunewald-Giemsa (MGG) stain (Image-7) and papanicolaou's stain (Image-8).

CD 4 T-lymphocyte cell count of the patient was $63/\text{mm}^3$. Patient's haemoglobin was 9 gm/dl. Total Leukocyte Counts (TLC), Differential Leukocyte Counts (DLC) and Platelet Counts were within normal limits in the beginning and remained stable except TLC which was observed rising gradually with neutrophilia.

Biochemical analysis of CSF showed marginal decrease in Glucose level. (27 mg/dl, normal range being 40-80 mg/dl) CSF protein was 41 mg/dl (normal range being 20-40 mg/dl)

Blood sugar level, serum protein levels, Liver function test and Renal function tests of the patients showed normal values.

The patient initially admitted in general ward was later shifted to ICU and put on artificial ventilation, as the patient's condition worsened. Amphotericin-B and fluconazole were started after the culture report of *C. neoformans*. Despite the best possible efforts, patient could not be saved.

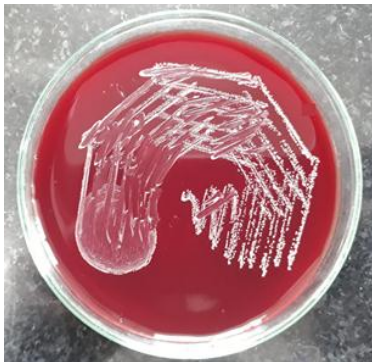

Fig. 1: *C. neoformans* grown on blood agar inoculated from blood culture bottle.

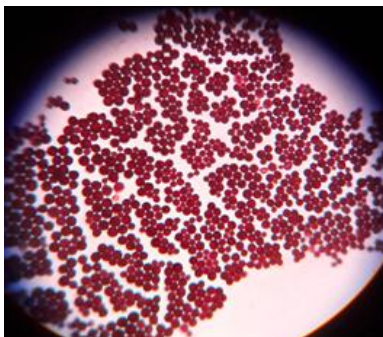


Fig. 2: Gram stain (100X) *C. neoformans* grown on BA inoculated from blood culture bottle




Fig. 3: India ink preparation (40X) of *C. neoformans* grown on blood agar inoculated from blood culture bottle

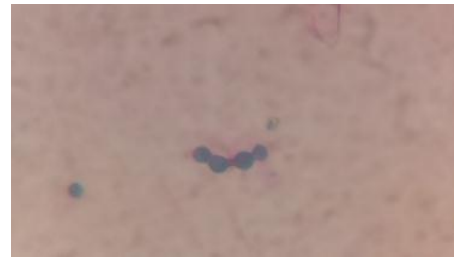

Fig. 4: Gram stain (100X) of CSF showing gram positive budding yeast cells

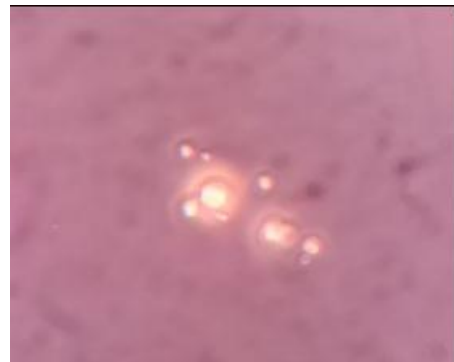

Fig. 5: India ink preparation (40X) of CSF showing clear haloes around yeast cells

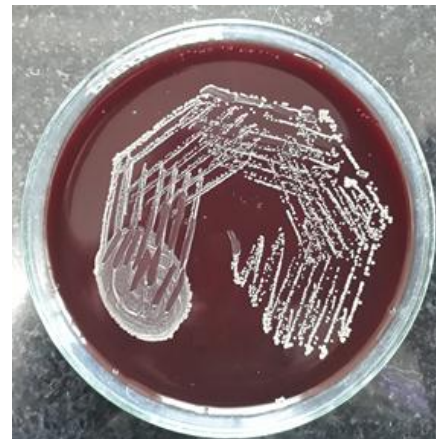

Fig. 6: *C. neoformans* grown on chocolate agar in CSF culture

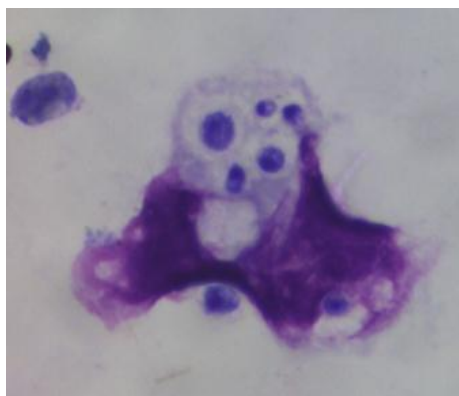


Fig. 7: May-Grunwald-Giemsa Stain (100X) of CSF

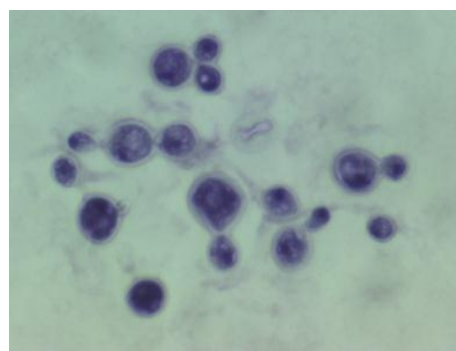


Fig. 8: Papanicolaou's stain (100X) of CSF

Discussion

Among the AIDS defining illnesses, cryptococcosis is the first illness to appear in around 45% of the cases.⁶ The prevalence of cryptococcal infections among AIDS patients varies from 2% to 10% Western Europe and U.S.; up to more than 15% in south-east Asian countries.⁷

A patient is said to be suffering from disseminated infection if cultures are positive in specimens from at least two different sites or a positive blood culture of that patient.⁸ In present case, *C. neoformans* was isolated from CSF as well as blood specimen. A case of fatal disseminated cryptococcosis is reported by Kaur *et al* (2019), in which an 11 year old female child succumbed to infection of *C. neoformans* isolated from specimens from different sites like CSF, gastric aspirate, lymph node aspirate & blood culture as well. It is noteworthy that the patient was HIV negative.⁹ Another case of disseminated cryptococcosis in an immune-competent 8 year old girl is reported by Chaudhary *et al* (2005)¹⁰ in which growth of *C. neoformans* was obtained from CSF, sputum and urine sample; but not blood. In the present case report, however, sputum and urine culture were negative for Cryptococcus. Cryptococcal meningoencephalitis diagnosed by blood culture in an adult HIV positive male is reported by Sivasangeetha *et al* (2007)⁷, although CSF culture was negative for *C. neoformans*.

The CD4 T-lymphocyte cell count of patient in our case was 63/mm³; well below 200/mm³. According to a study by Munivenkataswamy *et al* (2013),² based on 66 HIV-reactive patients; cryptococcal meningitis patients had CD4 cells less

than 200/mm³. Rather, majority patients (83%) had CD4 count less than 100/mm³. This finding is concordant with our case.

A rare case of cryptococcosis of bone marrow in AIDS patient has been reported by Gupta *et al* (2006).¹¹

Cryptococcosis, although considered as an AIDS defining disease, doesn't seem to be reported less from immunocompetent patients. Many case reports of cryptococcosis in HIV negative and apparent immunocompetent subjects are being reported.^{9,12,13} An interesting case of cryptococcosis in HIV negative patient suffering from systemic sarcoidosis, being the probable cause of immunosuppression; is reported by Botha and Wessels (1999).¹²

The standard antifungal drugs which can be used to treat Cryptococcosis are fluconazole, ketoconazole, itraconazole, voriconazole and amphotericin-B.¹⁴ Amphotericin-B is recommended to be used in progressive and life threatening fungal diseases like cryptococcosis. It is the drug of choice for its spectrum of activity and its low rates of resistance. To avoid or to minimize drug toxicity of Amphotericin B toxicities, lipid-based delivery technologies are indicated.¹⁵ A combination of liposomal amphotericin-B with fluconazole or 5-flucytocine is also practiced sometimes.^{3,9}

Both Liposomal amphotericin-B as well as fluconazole was administered to the patient in the present case.

Conclusion

Although reported sporadically in otherwise immune competent individuals, cryptococcal meningitis is very common in AIDS patients. Despite availability of effective antiretroviral therapy (ART), the worldwide burden of cryptococcal disease remains dreadfully high. Yet, novel strategies of screening and pre-emptive therapy offer great promise at making a sustained and much needed impact on reducing morbidity related to this sugar-coated opportunistic fungal pathogen. Through this case report, we would like to emphasize the importance of early suspicion of cryptococcal infection in AIDS patients; so that early establishment of full laboratory work up and institution of antifungal therapy can be done to improve patient outcomes.

Acknowledgment

We highly appreciate the co-operation extended by the Department of Pathology, Rural Medical College, PIMS (DU), Loni.

Conflict of Interest: None.

References

1. Pauw BE. What are fungal infections? *Mediterr J Hematol Infect Dis* 2011;3(1).
2. Munivenkataswamy R, Gopi A, Mohammed Usman S, Jagadeesh. Human immunodeficiency virus associated cryptococcal meningitis at a tertiary care centre: Diagnostic tools and Antifungal susceptibility testing. *J Clin Diagnostic Res* 2013;7(8):1623–5.
3. Arora U, Aggarwal A, Cryptococcal meningitis in aids patients

- A report of two cases : *Indian J Med Microbiol* 2019;(3):153–5.
4. Maziarz EK, Perfect JR. Cryptococcosis. *Infect Dis Clin North Am*. 2016;30(1):179–206. Available from: <https://www.ncbi.nlm.nih.gov/pmc/articles/PMC5808417/pdf/nihms914122.pdf%0Ahttps://linkinghub.elsevier.com/retrieve/pii/S0891552015000951>
 5. Pal M. Cryptococcus gattii: an emerging global mycotic pathogen of humans and animals. *J Mycolopathol Res* 2014;52(1):1–6.
 6. Hazen KC, Howell AS, Candida, Cryptococcus and other yeasts of medical importance. Chapter 114. In: Manual of Clinical Microbiology volume 2, 10th ed. Murray PR, Baron EJ, Pfaller MA, Tenover CF, Tenover RH, editors. American society for Microbiology: Wash.
 7. Sivasangeetha K, Harish BN, Sujatha S, Parija SC, Dutta TK, Cryptococcal meningoencephalitis diagnosed by blood culture, *Ind Journ Med Microbiol* 2007;25(3):282–4.
 8. Chuang YM, Ho YC, Chang HT, Yu CJ, Yang PC, Hsueh PR. Disseminated cryptococcosis in HIV-uninfected patients. *Eur J Clin Microbiol Infect Dis* 2008;27:307–10.
 9. Kaur H, Zaman K, Thapa BR, Rudramurthy SM. Fatal cryptococcosis involving multiple sites in an immunocompetent child. *Indian J Med Microbiol* 2015;33:S148–50.
 10. Chaudhary MW, Sardana K, Kumar P, Dewan V, Anand VK, Disseminated Infection with Cryptococcus Neoformans var Neoformans in an 8 Years Immunocompetent Girl, *Indian J Pediatrics* 2005;72(1).
 11. Gupta S, Kakar A, Byotra SP, Prakash V, Handoo A, Marrow Cryptococcosis in Acquired Immunodeficient. 2006; 54, 381
 12. Botha RJP, Wessels E. Cryptococcal meningitis in an hiv negative patient with systemic sarcoidosis. *J Clin Pathol* 1999;52(12):928–30.
 13. Patil RT, Sangwan J, Juyal D, Lathwal S. Meningitis due to Cryptococcus gattii in an immunocompetent patient. *J Clin Diagnostic Res* 2013;7(10):2274–5.
 14. Khan ZU, Randhawa HS, Kowshik T. Antifungal susceptibility of Cryptococcus neoformans and Cryptococcus gattii isolates from decayed wood of trunk hollows of Ficus religiosa and Syzygium cumini trees in north-western India. 2007;(June):312–6.
 15. Ostrosky-Zeichner L, Marr KA, Rex JH, Cohen SH, Cohen SH. Amphotericin B: time for a new “gold standard”; *Clin Infect Dis* 2003;37(3):415–25. Available from: <http://www.ncbi.nlm.nih.gov/pubmed/12884167>

How to cite this article: Rajhans VV, Roushani S, Bhalerao DS, Deorukhkar SC, Kulkarni VL. Disseminated cryptococcosis in an AIDS patient. *Int J Med Microbiol Trop Dis* 2019;5(1):127–30.