



Case Report

Rickettsia, A harbinger of havoc

Debabrata Chakraborty^{1,*}, Mandira Chakraborty², Sadanand Dey¹, Jayanta Roy³

¹Dept. of Neurology, Apollo Gleneagles Hospital, Kolkata, West Bengal, India

²Dept. of Microbiology, Medical College Kolkata, Kolkata, West Bengal, India

³Dept. of Neurology, AMRI Hospitals Mukundapur, Kolkata, West Bengal, India



ARTICLE INFO

Article history:

Received 03-11-2019

Accepted 05-11-2019

Available online 11-01-2020

Keywords:

Rickettsiae

Postthrombolysis

Stroke

ABSTRACT

Stroke and infection have a close relationship! There is possibly interplay of inflammation with traditional risk factors of stroke such as hypertension, hyperlipidemia, diabetes, and smoking. Rickettsia infection is already known to have multisystemic involvement. Stroke, both ischaemic and hemorrhagic though rarely reported to be associated with this infection often resulted in drastic consequences. Here, we will present a case where a gentleman who presented with stroke following a rickettsial infection only few days after he was thrombolysed for an initial event. We probably managed to avoid a catastrophe by treating the infection at earliest!

Key Messages: Infection may interact with traditional risk factors of stroke and may precipitate a vascular event. Epidemiological knowledge of existing infections in community, early detection and intervention may prevent complications even if stroke is precipitated.

© 2019 Published by Innovative Publication. This is an open access article under the CC BY-NC-ND license (<https://creativecommons.org/licenses/by/4.0/>)

1. Introduction

Stroke and infection have a close relationship and both goes hand in hand. It is hypothesized that infection, specific genetic factors and traditional risk factors interact with each other and synergistically enhance stroke risk.¹ Overall, the reported prevalence of infection in the month preceding ischaemic stroke ranges from 18% to 40%, and in the week preceding stroke from 10% to 35%.²

Here, we will report how a probable catastrophic event was avoided by early intervention in a patient who was suspected to have rickettsial infection.

2. Case History

A 52 year old gentleman, known diabetic, hypertensive and smoker, independent at baseline was under rehabilitation for alcohol de-addiction. On an early winter morning, he had an acute onset slurring of speech at 12.05 pm and

presented to emergency within an hour. On presentation, he had dysarthria with complete right hemiparesis NIHSS (National Institutes of Health Stroke Scale) of 13. CT scan and CTA (CT Angiogram) revealed ASPECTS (Alberta Stroke Program Early CT Score) of 10 with significant narrowing at left M1 division of Middle cerebral artery (MCA) respectively [Figure 1]. Thrombolysis was started with door to needle time of 24 minutes. At 2:25 pm (25 minutes from initiation of thrombolysis), he had a sudden deterioration of sensorium with frothing from mouth, upward and left gaze with plegia of the paretic side (NIHSS 15). Immediate CT ruled out bleed and he was loaded with levetiracetam followed by maintenance. He improved to NIHSS of two (post infusion) and had NIHSS of one next day morning. His MRI brain revealed multiple patchy infarcts at left MCA territory [Figure 2]. Considering large artery atherothrombotic narrowing at M1 segment of middle cerebral artery, dual antiplatelets with high dose statin was started and he was finally discharged home on day 4 with NIHSS of 0. He was improving steadily at home and was compliant with his medications.

* Corresponding author.

E-mail address: drdchakraborty1980@gmail.com (D. Chakraborty).

After 10 days of discharge, he had an episode of intermittent fever and cough. He visited OPD and oral antibiotic was started. Two days later, he presented to the emergency in confused state with high grade fever, chills, rashes (evanescent and in centrifugal distribution), joint pain, hypotension and fluctuating right sided weakness. MRI of brain ruled out any new event. He was started on broad spectrum antibiotics (including doxycycline) and was haemodynamically stabilized.

We had two back to back cases of rickettsia before presentation of this case so we started doxycycline prophylactically after examining the rashes.

Next day morning, he was alert, less febrile, haemodynamically stable, rashes improved to some extent but detected to have complete right hemiplegia, facial droop and dysarthria (NIHSS of 9). The repeat MRI in morning revealed new infarct in posterior limb of internal capsule, anterior temporal lobe and corona radiata of the same MCA territory [Figure 3]

He had minimal deficit initially during this presentation (NIHSS 3); and was suspected to have a perforator disease causing the subcortical involvement. He was also under suspicion for infection (possibility of infective endocarditis was there) and was thrombolysed only 2 weeks back. Hence, he was managed conservatively during this event. His investigations revealed high CRP (201 mg/l), leucocytosis with positive Weil felix test for spotted fever group Rickettsia (Proteus Antigen OX 2- 1:160 and OX 19- 1:40). Investigation came negative for infective endocarditis and vasculitic markers and his metabolic parameters also remained stable throughout. He improved steadily with rehabilitation and was finally discharged home with power of almost 4/5 MRC grade on the affected side.

3. Discussion

This is first case where shortly after a successful thrombolysis, patient presented with another stroke and rickettsial infection. It is well known that there is interplay of inflammation with traditional risk factors of stroke such as hypertension, hyperlipidemia, diabetes and smoking. Infections lead to expression of tumor necrosis factor- α (TNF- α) and IL-6 that lead to thrombosis.¹ Inflammatory C-reactive protein might promote localised coagulation, and therefore thrombosis by stimulating monocytes to produce tissue factor that initiates the extrinsic pathway of coagulation.³ CRP can also affect plaque stability by promoting leukocyte migration through the expression of cellular adhesion molecules, activation of matrix metalloproteinases predisposing to plaque rupture.¹

Platelet activation in patients with acute ischaemic stroke was increased among patients with a history of infection in the week preceding stroke.⁴ There are many infections including bacterial, fungal, viral and parasitic that directly lead to ischaemic and haemorrhagic stroke. Here we will

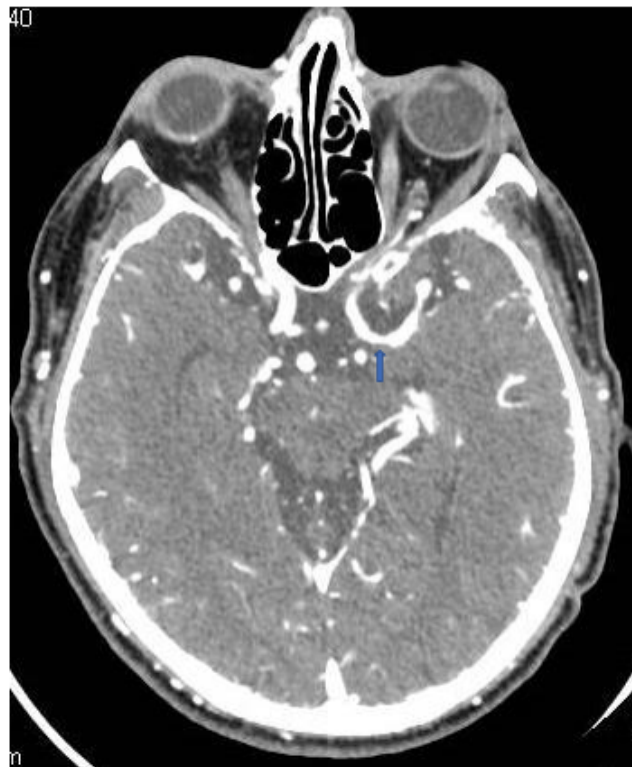

Fig. 1: CTA at presentation: proximal MCA stenosis (blue arrowhead).

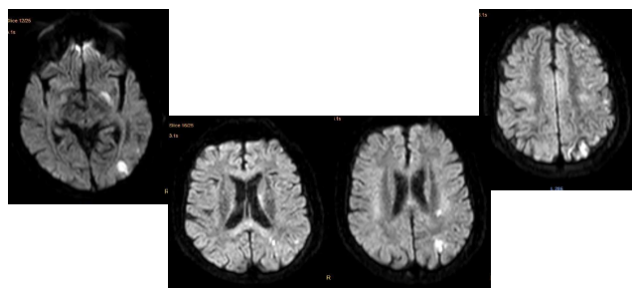


Fig. 2: MRI at initial discharge revealing patchy infarcts in left MCA artery

discuss pathogenesis of a microorganism that rarely has role in stroke.

Family Rickettsiaceae phylogenetically occupy a position between bacteria and viruses. Rickettsiae are small, nonflagellate, gram negative pleomorphic cocco-bacilli adapted to obligate intracellular parasitism and transmitted by arthropod vectors.⁵

Man is an accidental host and transmission to humans occur by infected arthropod vector or exposure to infected animal (incubation period varies from 2 to 21 days). Vector to human transmission occur primarily by bite, where regurgitation of infected saliva occurs during feeding.⁶

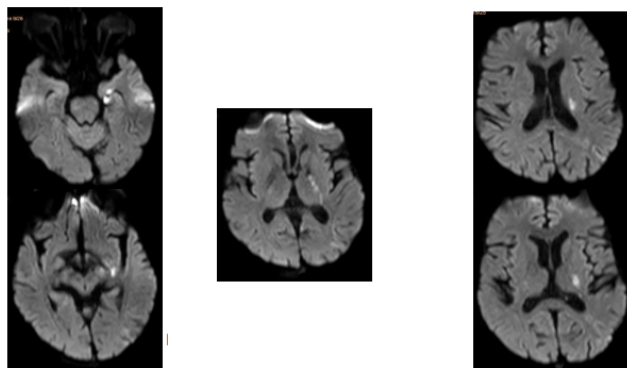


Fig. 3: Final MRI (after the second event) revealing new infarcts at posterior limb of internal capsule, anterior temporal lobe and corona radiata.

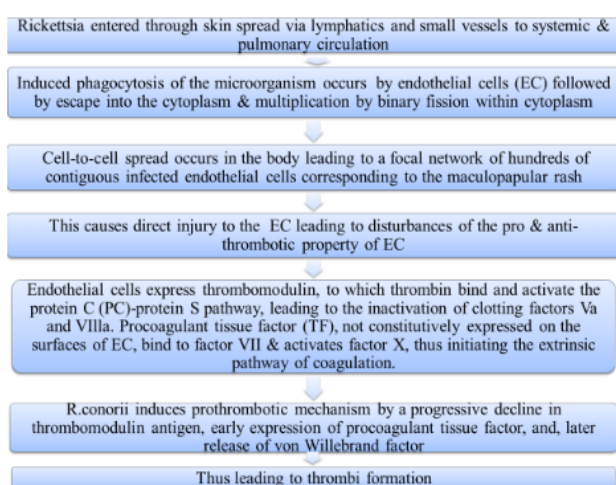


Fig. 4: Brief summary of Rickettsial pathogenesis.

The flowchart [Figure 4] is a brief summary of Rickettsial pathogenesis.^{7,8} These microorganisms induce coagulopathies and thrombotic events and the hemostatic and fibrinolytic changes occur as late manifestations of illness, especially if treatment is delayed.^{9,10}

Jong-Hoon Chung et al in their case series highlighted rickettsia may have contributed in even large artery stroke (ICA occlusion), focal haemorrhage and also subdural hematoma.¹⁰

In our case, the initial mechanism of stroke was large vessel atherothrombotic disease and with traditional risk factors on board, the new onset of infection might have precipitated platelet activation. The CRP level was also high during the final presentation (201 mg/L) that could have further contributed in the pathogenesis of this event.

It is difficult to prove or disprove that Rickettsia is the direct cause of stroke but it may have acted as a provoking factor for stroke. Early detection and intervention

of infection may prevent complications even if stroke is precipitated. Although, it is not clear whether we have prevented a bigger event by starting early doxycycline, it is beyond doubt that epidemiological knowledge of existing infections in the community help us to diagnose and act fast for better outcome.

4. Source of Funding

None.

5. Conflict of Interest

None.

References

1. Lindsberg PJ, Grau AJ. Inflammation and infections as risk factors for ischemic stroke. *Stroke*. 2003;34:2518–2532.
2. Emsley CAH, Hopkins SJ. Acute ischaemic stroke and infection: recent and emerging concepts. *Lancet Neurol*. 2008;7:341–353.
3. Cermak J, Key NS, Bach RR, Balla J, Jacob HS, et al. C-reactive protein induces human peripheral blood monocytes to synthesize tissue factor. *Blood*. 1993;82:513–520.
4. Zeller JA, Lenz A, Eschenfelder CC, Zunker P, Deuschl G. Platelet leukocyte interaction and platelet activation in acute stroke with and without preceding infection. *Arteriosclerosis, Thrombosis, Vascular Biology*. 2005;25:1519–1523.
5. and CKJP. Ananthanarayan and Paniker's Textbook of Microbiology. University Press Pvt. Ltd ; 2008,. p. 412–421.
6. Rathi N, Rathi A. Rickettsial Infections: Indian Perspective. *Indian Perspective*. 2010;47.
7. Mandell GL, Bennett JE, Dolin R, Mandell D. Bennetts Principles and Practice of Infectious Diseases. vol. 187. Churchill Livingstone Elsevier ; 2010,. p. 2499–2407.
8. Teyssie N, Arnoux D, George F, Sampol J, Raoult D. von Willebrand Factor Release and Thrombomodulin and Tissue Factor Expression in Rickettsia conorii Infected Endothelial Cells. *Infection Immunity*. 1992;p. 4388–4393.
9. Ben-Zvi IE, Meltzer O, Feld I. Bank. A case of murine typhus associated with large vessel infarct of the spleen. *Am J Med Sci*. 2008;6:502–503.
10. Chung JH, Yun NR, Kim DM, Lee JW, Yoon SH, et al. Case Report: Scrub Typhus and Cerebrovascular Injury: A Phenomenon of Delayed Treatment? *Am J Trop Med Hyg*. 2013;89(1):119–122.

Author biography

Debabrata Chakraborty Consultant

Mandira Chakraborty Tutor

Sadanand Dey Consultant

Jayanta Roy Consultant

Cite this article: Chakraborty D, Chakraborty M, Dey S, Roy J. Rickettsia, A harbinger of havoc. *Int J Med Microbiol Trop Dis* 2019;5(4):238–240.