

# Intraperitoneal Hydatidosis with Predominant Renal Symptoms: A Case Report

Nandini Chatterjee<sup>1</sup>, Suvajit Das<sup>2</sup>, Mainak Mukhopadhyay<sup>3</sup>, Chandan Chatterjee<sup>4\*</sup>

<sup>1</sup>Associate Professor, Department of Medicine, Murshidabad Medical College, Murshidabad, <sup>2</sup>Assistant Professor,

<sup>4</sup>Associate Professor, Department of Pharmacology, ESI-PGIMER, ESIC Medical College, Kolkata, <sup>3</sup>PG Trainee, Department of Cardiology, Nilratan Sircar Medical College, Kolkata

**\*Corresponding Author:**

Email: rivuc2006@gmail.com

---

## ABSTRACT

*We present the case of a 35 year old lady from a remote area with flank pain and polyuria, which was treated repeatedly with antibiotics without avail, only to be diagnosed later as a case of disseminated hydatidosis.*

**Key Words:** *Hydatidosis, Intraperitoneal, Albendazole*

---

## INTRODUCTION

Hydatid disease is a parasitic infection caused by the cestode *Echinococcus granulosus*. It is endemic in the cattle grazing areas of Australia, New-Zealand, Middle East, India, Africa, South America and Turkey[1]. Dogs are the definitive hosts harbouring the adult tapeworms in their small intestine. Their faeces containing infective ova can contaminate vegetables and drinking water, thus spreading the infection to humans, who act as intermediate hosts. The primary sites of infection in humans are the liver (75%) and the lungs (15%)[1]. In few occasions, the disease may secondarily disseminate to other intra-abdominal sites including the peritoneum[1]. Primary peritoneal hydatid cysts are a rarity[2]. Most of these cases develop into visceral cysts and remain asymptomatic until they enlarge to produce pressure symptoms such as pain, fullness of the abdomen and obstructive symptoms[2]. We present a case of multiple intra-abdominal hydatidosis where atypical presentation led to delay in diagnosis and subsequent unnecessary intake of multiple treatment regimes, in a 35 year old lady. Imaging modalities along with serological tests finally helped in clinching the diagnosis.

## CASE PRESENTATION

A 35 year old lady presented to us in the out-patient department of a tertiary care government run hospital, with complaints of right sided dull aching flank pain with dysuria and increased frequency of urination over the past six months. There was no history of hematuria or any local trauma. Her bowel habits remained unaltered and menstruation seemed regular. A non-diabetic, non-hypertensive and mother of two children, she hailed from a remote, rural area of Eastern India and had a history of taking several ineffectual antibiotic regimens and analgesic therapies for the present condition, over the past six months. These medications were either taken over-the-counter or prescribed by local practitioners. Her past investigations included

routine and microscopic urine examination, urine culture sensitivity tests and renal function tests. Despite the non-contributory laboratory tests on several occasions, she was treated on the assumption that she was suffering from urinary tract infections. Some of these prescriptions were irrational and seemed to be prescribed over the counter by quack practitioners in local medicine shops. On one occasion, she was misdiagnosed as having pelvic inflammatory disease and treated with anti-microbial and anti-fungals. She had finally decided to attend a tertiary care hospital due to increasing intensity of her symptoms despite prolonged and varied treatments.

On clinical examination, she showed mild pallor and bipedal edema. Palpation of the abdomen revealed mild hepatomegaly and multiple round non-tender smooth two to three inch-size lumps, scattered over lower abdomen. There was no lymphadenopathy and loins were normal on palpation except for mild tenderness on the right side. Other systemic findings were non-significant.

## INVESTIGATIONS

Complete hemogram and blood biochemistry were normal except a haemoglobin level of 10gm/dl. Routine examination and culture sensitivity testing of urine sample were also normal. Chest X-ray was within normal limits. Ultra-sonogram of whole abdomen revealed a large cyst (size 5 cm. x 5 cm. x 5 cm.) over the region of the upper pole of the right kidney along with three smooth walled cysts in the liver and three other in the pelvis. These cysts ranged from two to three centimetres in largest diameter. These findings prompted us to do an urgent CT scan of abdomen for better delineation (Fig. 1). CT scan confirmed the sonography findings with greater clarity but no additional masses or cysts were noted.

These cysts were thin walled with few areas showing evidences of calcification. The largest cyst as ascertained from tomography was peritoneal in origin

and was compressing the right kidney and ureter without invading into it (Fig. 2, Fig. 3, Fig. 4). Spoke wheel patterns were found in some cysts while scolices were not clearly noted in any of the cysts.

However, the patient had refused to go for invasive tests and hence aspiration biopsy was precluded.

The clinical presentation along with findings of multiple septate cysts on imaging led us to seek for an anti echinococcal antibody test and the titre came out to be 1: 64 against a laboratory normal titre range of up to 1:32. Therefore, our diagnosis came out to be a case of disseminated hydatidosis with predominant urological symptoms.

## **DISCUSSION**

The common differential diagnosis of intra-abdominal cysts in a middle aged woman include cystic tumours, ovarian tumours, hydatid disease, intra-abdominal abscess, necrotic malignant soft tissue tumour, cystic lymphangioma, etc. Disseminated intra peritoneal hydatidosis is an uncommon finding, the incidence

being around 13%. [2] It usually results from spillage from hepatic, splenic or peritoneal cysts due to trauma or surgical rupture. [3] However, spontaneous rupture of micro cysts may occur in 12% of cases. [1]

Abdominal distension and pain are common symptoms of hydatid cysts. However, urinary frequency, dysuria and flank pain mimicking pyelonephritis were confounding factor in our case. The compression of the right kidney and ureter could possibly explain the flank pain and urinary frequency in this patient.

Treatment options in such cases include surgery of large cysts coupled with albendazole therapy [4,5] and our patient has started receiving the drug and is awaiting surgery.

The novelty of our case was in the presentation of the case. It opened our eyes to the fact that all cases of flank and dysuria are not suffering from urosepsis. It also exemplifies the importance of simple palpation which nowadays seems to have been replaced by quick remedies leading to vast economic burdens.

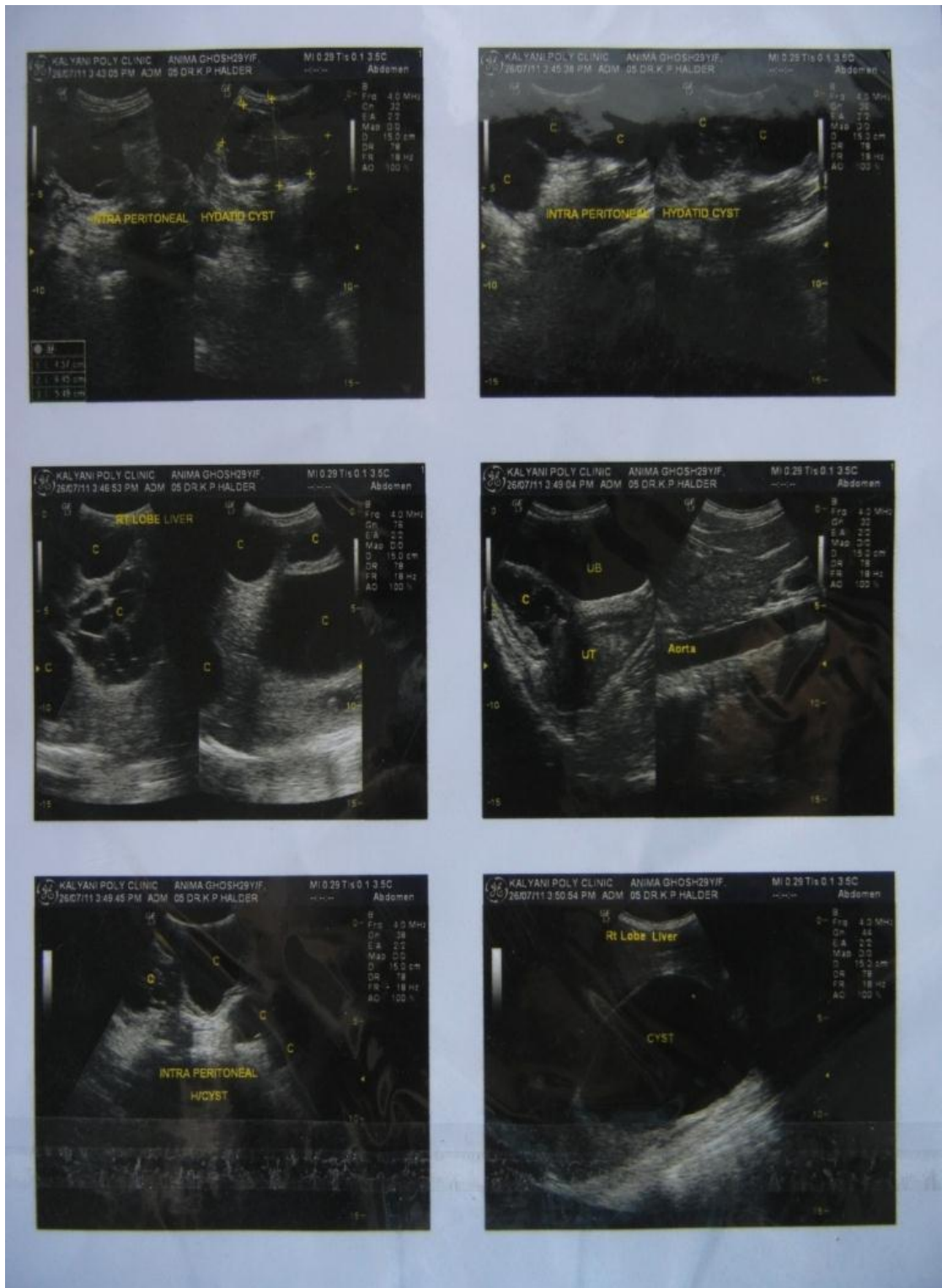


Fig. 1: USG abdomen revealing multiple smooth walled cysts in liver and pelvis

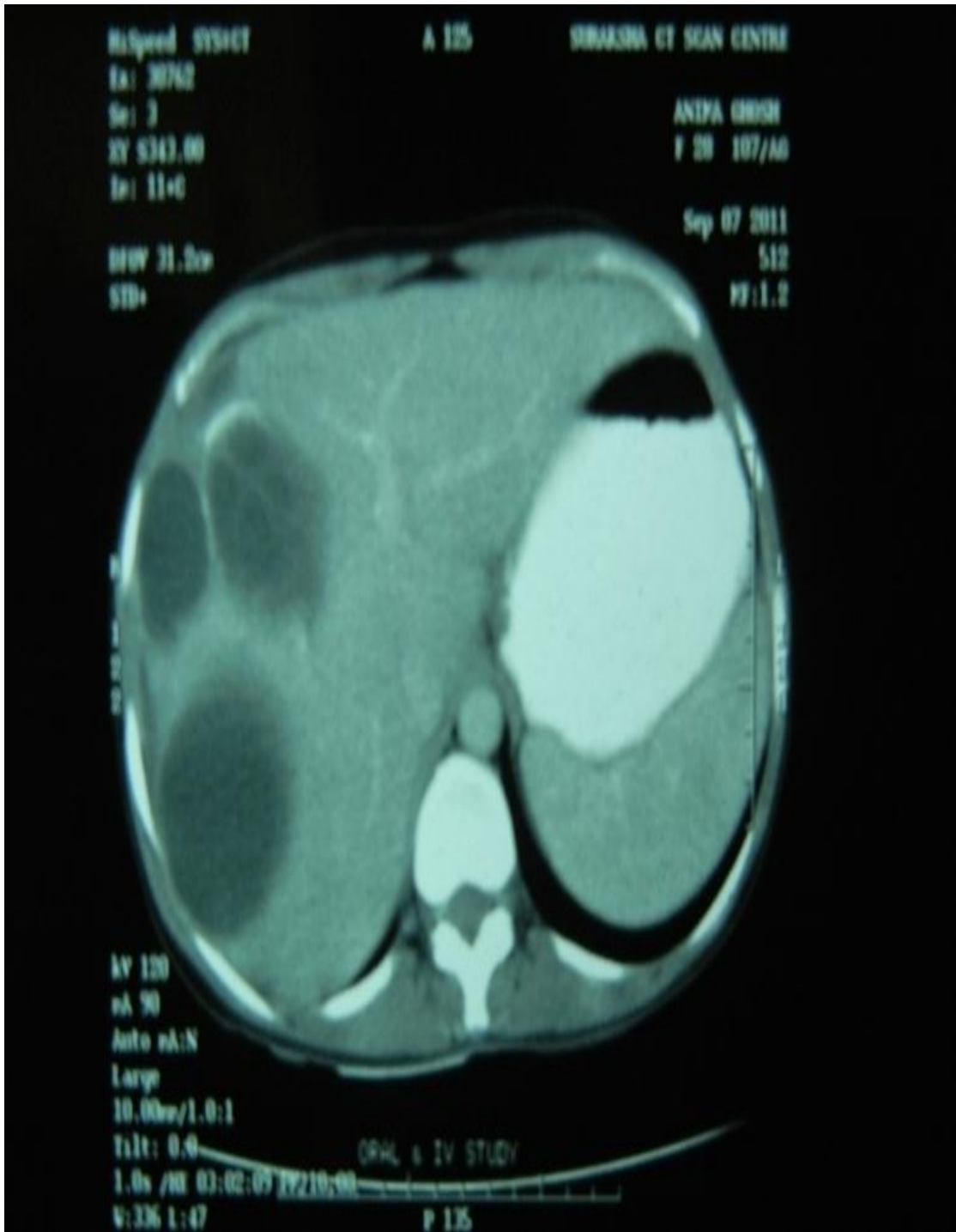


Fig. 2: CT scan of abdomen shows multiple smooth walled cysts

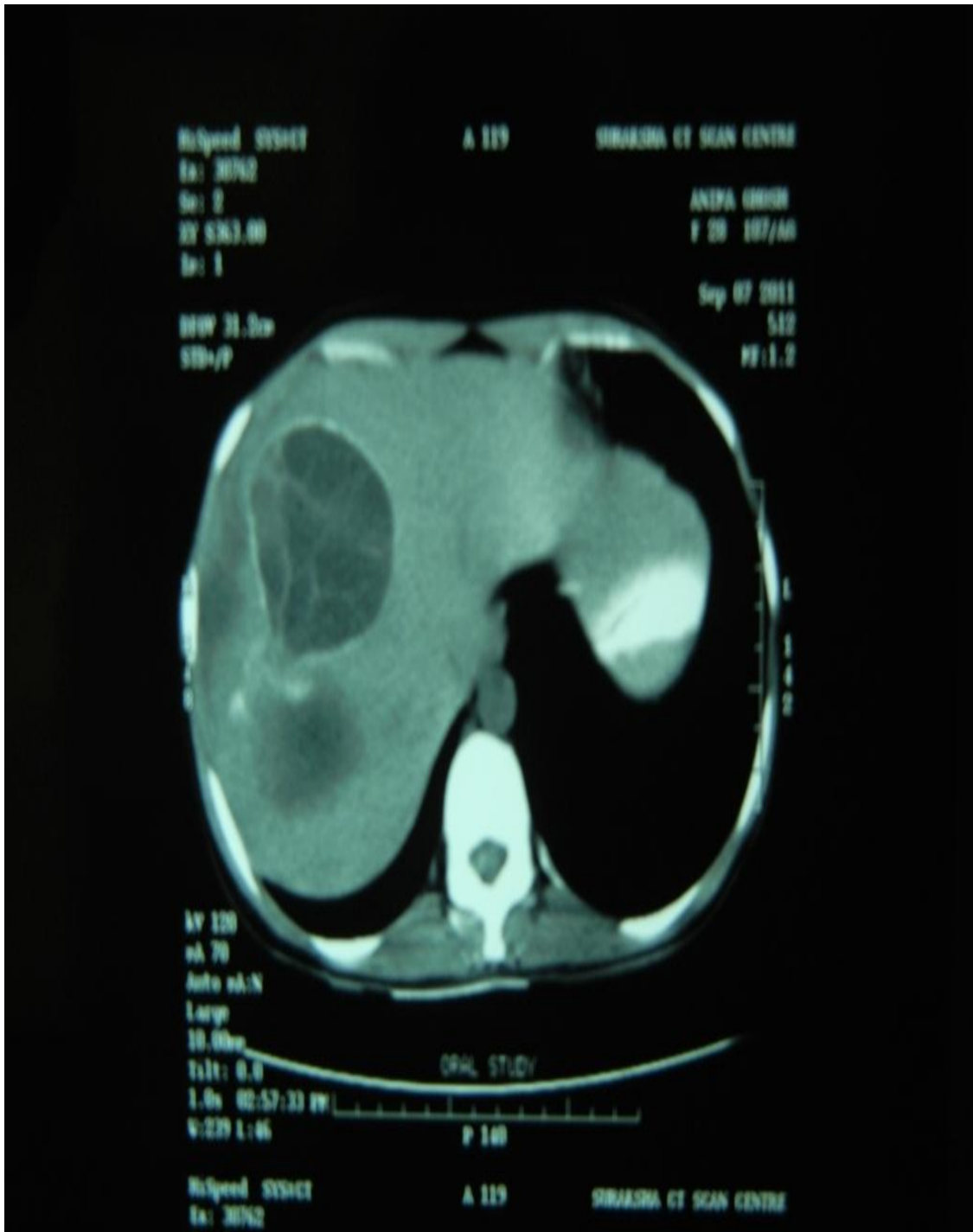
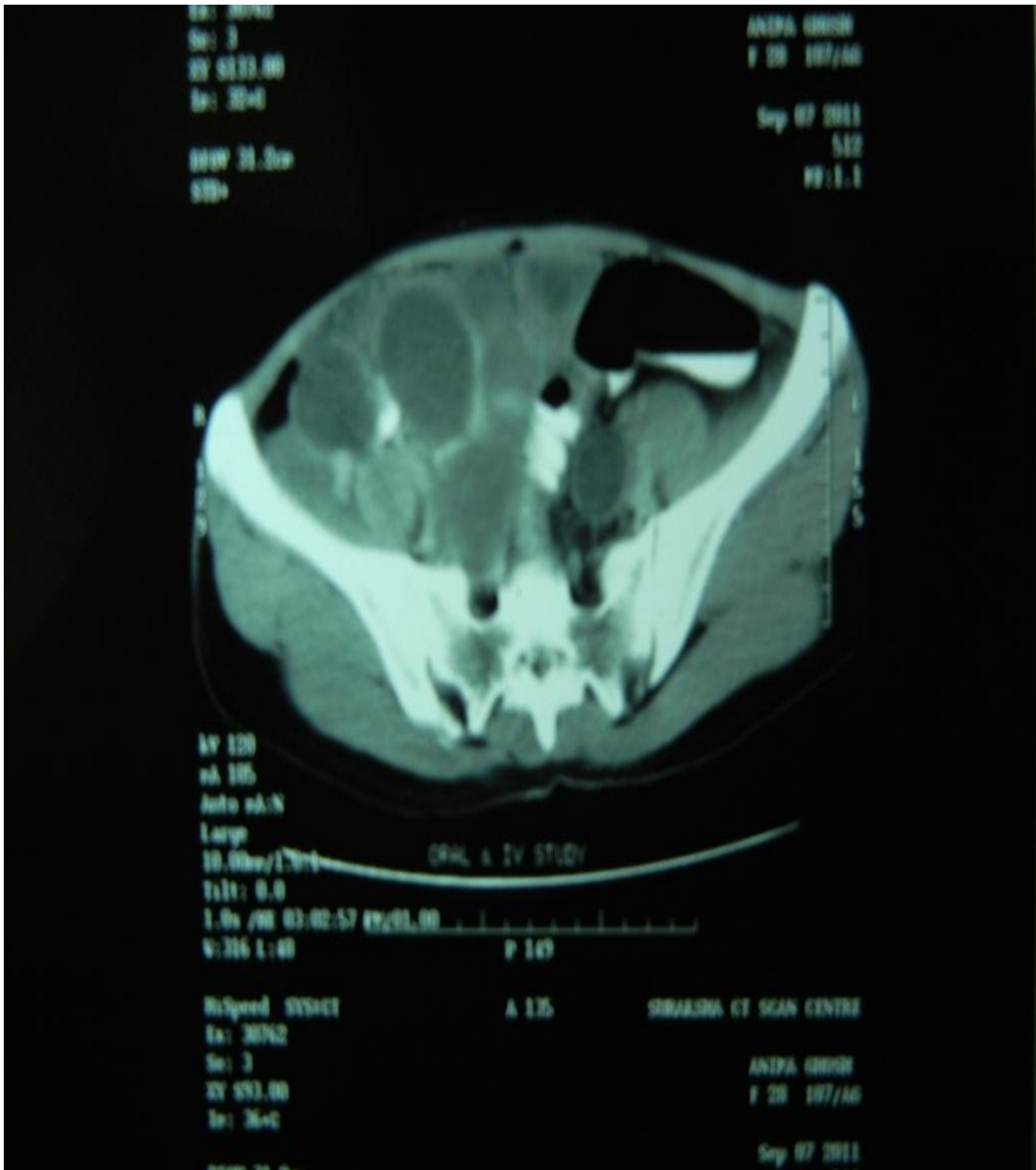
Fig. 3: CT scan of abdomen shows septate (spoke wheel pattern) in a hepatic cyst



**Fig. 4:** CT scan of abdomen shows a large cyst compressing the right kidney

#### REFERENCE

1. Sayek I, Yalin R, Sanac Y. Surgical treatment of hydatid disease of the liver. *Arch Surg.* 1980;115:847-50.
2. Pedrosa I, Saiz A, Arrazola J, Ferreiros J, Pedrosa CS. Hydatid disease: radiologic and pathologic features and complications. *Radio graphics* 2000;3:795-817.
3. Karavias DD, Vagianos CE, Kakkos SK, Panagopoulos CM, Androulakis JA. Peritoneal echinococcosis. *World J Surg* 1996;20:337-40.
4. Butterschoen K, Carli Butterschoen D. Echinococcus granulosus infection: the challenge of surgical treatment. *Langenbecks Arch Surg* 2003;4:218-30.
5. Balik AA, Celebi F, Basglu M, Oren D, Yildirgan I, Ataman alp SS. Intra-abdominal extra hepatic echinococcosis. *Surg Today* 2001;10:881-4.