

Content available at: <https://www.ipinnovative.com/open-access-journals>

IP International Journal of Medical Microbiology and Tropical Diseases

Journal homepage: <https://www.ipinnovative.com/journals/IJMMTD>

Original Research Article

To study the prevalence & clino-mycological profile of Otomycosis in Saurashtra & Kutch region of Gujarat

Madhulika Mistry^{1,*}, Apurva Pathak¹¹Dept. of Microbiology, P.D.U Govt Medical College & Civil Hospital, Rajkot, Gujarat, India

ARTICLE INFO

Article history:

Received 21-11-2020

Accepted 30-11-2020

Available online 02-01-2021

Keywords:

Aspergillus

Otomycosis

ABSTRACT

Background: Otomycosis is a superficial, sub-acute or chronic infection of the external auditory canal. It is worldwide in distribution with a higher prevalence in the hot, humid, and dusty areas of the tropics and subtropics. A wide variety of fungi can cause Otomycosis.

Objectives: To determine the demographic profile & spectrum of fungi involved in Otomycosis in saurashtra & Kutch region of Gujarat.

Materials and Methods : A retrospective study of 101 clinically suspected cases of otomycosis were conducted. The sample are taken by two sterile cotton swabs comprised of secretions, pus and debris from the external auditory canal. Direct microscopic examination by 10% KOH, Gram stain & culture on *Sabouraud Dextrose Agar* medium was done. Identification of fungi done by lacto phenol cotton blue, GERM TUBE TEST & growth on CORNMEAL AGAR and Hichrome Media used for species identification.

Result: Out of 101 cases, 76(75.24%) were Culture Positive and 74(73.26%) were KOH positive. Out of 74 KOH positive, 65(87.83%) cases were culture positive. Predominantly males (52.6%) were affected. The most affected age group is 31-40 yrs of age (23.68%). *Aspergillus niger* (52.63%) was the predominant species isolated followed by *Aspergillus flavus* (36.84%), *Candida spp*, *Penicillium spp*. & *Rhizopus spp*. The disease is predominantly unilateral.

Conclusion: Otomycosis should be suspected clinically and should be confirmed by laboratory diagnosis to prevent unnecessary use of antibiotics & there by antibiotic resistance. Mycological diagnosis is important to differentiated from bacterial infection, since symptoms (pruritus, otalgia, otorrhea and hypacusis) are not specific.

© This is an open access article distributed under the terms of the Creative Commons Attribution License (<https://creativecommons.org/licenses/by/4.0/>) which permits unrestricted use, distribution, and reproduction in any medium, provided the original author and source are credited.

1. Introduction

Otomycosis is an acute, sub-acute or chronic fungal infection of the Pinna, the external auditory meatus and the ear canal.¹ This is commonly seen in tropical and subtropical regions of the world. The frequency to otomycosis depends upon different climatic conditions with higher prevalence in the hot, humid and dusty areas.² This is worldwide in distribution with prevalence ranging from 9% to 30% among patients presenting with signs and symptoms of otitis externa and discharging ears in otolaryngology

settings.^{2,3}

Though Otomycosis is rarely a life-threatening disease, it is a challenging and frustrating entity for both patients and otolaryngologists because it usually requires long-term treatment and follow-up. In spite of this, recurrences may occur.⁴

Otomycosis is commonly associated with increased ear canal moisture, warmth and treatment of a bacterial infection with long term topical antibiotic therapy, which can lead to depletion of the protective cerumen layer, maceration of underlying skin, increase in ambient pH and a modification of the microbial flora of external auditory canal, thereby selecting for untreated organisms. A medical

* Corresponding author.

E-mail address: madhulika_mistry@yahoo.co.in (M. Mistry).

history of diabetes and / or an immunocompromised state may be present.⁵ Most patients suffering from early otomycosis complain of severe itching which often progress to pain, hearing loss, and often leading to tympanic membrane perforations.⁶⁻⁸

The flora found in the EAC is made up of a series of microorganisms viz. genus *Aspergillus* or yeast-like fungi, *Candida spp.*, *Staphylococcus aureus*, *Staphylococcus epidermidis*, *Streptococcus* species, *Micrococcus*, *Corynebacterium* species, *Bacillus* species, *Pseudomonas aeruginosa*, *Escherichia coli*, *Haemophilus influenzae*, *Moraxella catarrhalis* etc. Commensal flora is not pathogenic as long as the balance between bacteria and fungi is maintained in the EAC.⁹

This study is undertaken to determine the spectrum of fungi involved in Otomycosis including KOH and culture results in Tertiary care hospital, Rajkot.

2. Materials and Methods

This is a retrospective study conducted in the Dept of Microbiology, P.D.U Govt. Medical College & Civil Hospital, for a period of 9 months between June 2018 to Feb 2019, on patients attending the Department of ENT. A total of 101 clinically suspected cases of otomycosis were enrolled for the study. Mycological study was carried out on debris, scrapping or exudates samples from auditory canal(s), using two sterile cotton swabs.

1. One swab was used for Direct microscopic examination for detection of fungal elements. For this KOH (10%) and Gram stain.
2. Second swab was inoculated on Sabouraud’s Dextrose Agar (SDA)

Cultures were incubated in parallel at room temperature (25°C) and at 37°C for 4weeks. On alternate days, cultures were examined for growth. Identification of fungi was done by standard procedures.

Culture plates were examined for growth every 2-3 days. The presence of fungal elements in KOH mount was confirmed by growth on SDA. If no growth was obtained on SDA after 4 weeks, then culture was considered sterile. If growth was seen on SDA medium, the morphology of fungal isolates was further studied by using the Lacto Phenol Cotton Blue (LPCB). Presumptive identification of *Candida spp.* was done by using GERM TUBE TEST. The *Candida* strain was further grown on CORNMEAL AGAR and Hichrome Media for species identification.

3. Result

The study included 101 suspected clinical samples from ENT OPDs collected over a period of 9 months (June 2018 to Feb 2019) in the Microbiology Laboratory at P.D.U Medical College, Rajkot, Gujarat. Fungal culture

yields 76 isolates out of 101 suspected samples of otomycosis representing prevalence of otomycosis 75.2%. All specimens yielded single organism. *Aspergillus niger* 40(52.63%) was the predominant species isolated. *Aspergillus flavus* 28(36.84%) was the second most common species isolated, followed by *Candida spp* 5(6.57%) *Penicillium spp* 2(2.63%), *Rhizopus spp* 1(1.33%). Out of 5 *Candida spp*; 2 *Candida albicans*, 1 *Candida parasilopsis*, 1 *Candida glabrata*, 1 *Candida guilliermondii* were isolated.

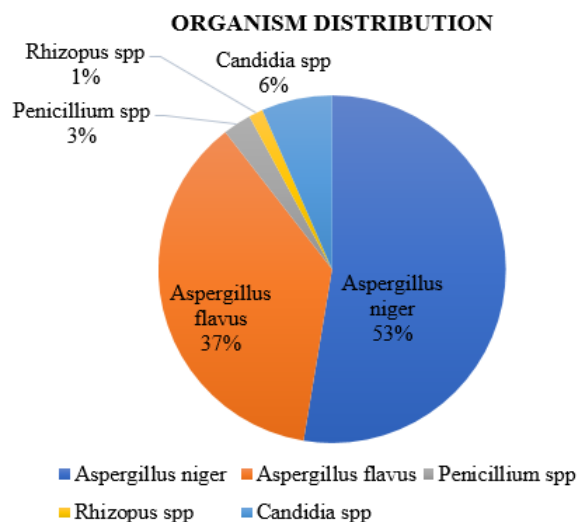


Fig. 1: Spectrum of fungi

Table 1 shows that out of 76 patients, 36 were female and 40 were male, female: male ratio being 9:10. Maximum number of patients 18(23.68%) were in age 31-40 years, followed by in 21-30 years 16(21.05%), in >60 years 16(21.05%), in 41-50 years 15(19.73%) & in 51-60 years 16(21.05%).

Table 1: Age group & Gender

Age group (in years)	Female	Male	Total
11-20	3	2	5 (6.57%)
21-30	9	7	16 (21.05%)
31-40	11	7	18 (23.68%)
41-50	7	8	15 (19.73%)
51-60	2	4	6 (7.89%)
>60	4	12	16 (21.05%)
Total	36	40	76

Table 2 In this study, otomycosis was found to be 98.6% unilateral in which the right side showed 43(56.6%) predominance over the left side 32(42.1%). Bilateral involvement was seen in 1(1.3%) case.

Of these 76 cases, 65 were both microscopy and culture positive, whereas 11 cases were microscopically negative

Table 2: Correlation of KOH and Fungal culture

KOH	Culture positive	Culture negative	Total
KOH Positive	65	9	74
KOH Negative	11	16	27
Total	76	25	101

for fungal elements but fungal culture positive. 16 cases were both microscopy and culture negative & 9 cases were positive only by microscopy. Thus true positive cases were 65 & true negative were 16 by KOH preparation when compared to culture (gold standard). Sensitivity & specificity of KOH preparation was 85.53% & 64% respectively. The accuracy was 80.20%

4. Observation

Otomycosis is a chronic superficial fungal infection that affects the deeper ear canal skin and the tympanic membrane. Otomycosis is one of the most common presenting diseases at the Otorhinolaryngology Outpatient Department particularly in the tropical and subtropical countries. Otomycosis remains common source of misery for patients. Often remains unnoticed and unattended until severe pain occurs. Various factors pave the way for saprophytic fungus to gain foothold in external canal skin such as trauma by frequent ear cleaning, topical ear drops etc.

The occurrence of otomycosis is 75.2% may be due to high degree of humidity in this region. Similar findings were reported from Praveen Kumar Karn et al;¹⁰ Rao et al¹¹ and Agrawal Priti et al¹² where it was seen to be 81.70%, 78.3% and 88.6% respectively. Other Indian studies report varying culture positivity from 28% to 100%.^{13,14}

The most predominant agent for otomycosis in the present study was *A. niger* (52.63%) probably due to its high preference for the external auditory canal and its ability to produce a great amount of conidia. This finding is comparable to other study by Kumar R et al,¹⁵ Sampath Chandra Prasad et al¹⁶ in which the most common pathogenic fungus was *A. niger*. However, the results obtained by Kaur et al¹⁷ show that in the tropical regions, the commonest aetiologic agents accountable for otomycosis are *A. fumigatus* (41.1%) and *A. niger* (36.9%). Other fungi that have been associated with otomycosis in our study were *A. flavus*, *Candida spp*, *Penicillium spp*, *Rhizopus spp*.

In present study 65 cases were smear and culture positive, whereas 11 cases were smear negative but culture positive for fungal elements. 9 samples didn't show any growth on media though they were positive for fungal elements on direct smear, probably because of stringent requirement of fungi for some essential nutrient or may be contaminants.

Fungal diseases are not related to gender, but some studies had different results around otomycosis. In our study, infection of otomycosis was seen more in men than women which is consistent Agrawal Priti et al¹² and H.S Satish et al.¹⁸ However, some studies like Visweswara Rao Suraneni et al,¹⁹ Kiakojuri K et al²⁰ and Bhat K. S. et al²¹ showed female preponderance.

An analysis of the age group revealed that otomycosis can affect any age from 11-20 year through more than 60 years. Whereas the incidence was found to be low below 20 years and 51-60 years. In our study the occurrence was high in the age group 31-40 years which is similar to finding in Panigrahi Monalisa et al,¹⁸ Gupta Suharshi et al.¹⁹

Otomycosis was found to be predominantly unilateral with the right side of ear being more affected when compared to left. The occurrence of bilateral otomycosis is very low.^{20,21} In this study, bilateral involvement was found in 1.3% cases, which is consistent with the findings of Sabz et al. (2019) who observed bilaterality in 9% of the patients.²² Otomycosis is mostly unilateral or associated with slight cases of bilateral otomycosis. This indicates that it is not a very contagious pathology without predilection for one side of the ear.

5. Conclusion

In my study, *Aspergillus* species was the commonest fungi involved in Otomycosis with male predominance, affecting 31-40 years of age in majority and unilaterality predominance. Otomycosis should be suspected clinically and should be confirmed by laboratory diagnosis to prevent unnecessary use of antibiotics & there by emergency of antibiotic resistance. Mycological diagnosis is important since symptoms (pruritus, otalgia, otorrhea and hypacusis) are not specific so, laboratory diagnosis helps to know the exact etiology of Otomycosis to initiate appropriate antifungal therapy in time. Microscopic smear examination cannot be taken as evidence of negativity for fungal presence and has to be confirmed with culture of the specimen the gold standard.

6. Source of Funding

No financial support was received for the work within this manuscript.

7. Conflict of Interest

The authors declare they have no conflict of interest.

References

1. Mahmoudabadi AZ. Mycological studies in 15 cases of otomycosis. *Pak J Med Sci.* 2006;22(4):486–8.
2. Pontes ZB, Silva AD, Lima E, De O, Guerra M, De H, et al. Otomycosis; A retrospective study. *Braz J Otolarygol.* 2009;75(3):367–70.

3. Mugliston T, O'Donoghue G. Otomycosis—A continuing problem. *J Laryngol Otol*. 1985;99(4):327–33. doi:10.1017/s002221510009678x.
4. Ho T, Vrabec JT, Yoo D, Coker NJ. Otomycosis: Clinical features and treatment implications. *Otolaryngol-Head Neck Surg*. 2006;135(5):787–91. doi:10.1016/j.otohns.2006.07.008.
5. Dennis J, Bruderly T, Razzak YA. Otitis externa.OCNA. *Otolaryngol Clin North Am*. 1996;29(5):761–82.
6. Viswanatha B, Sumatha D, Vijayashree MS. Otomycosis in Immunocompetent and Immunocompromised Patients: Comparative Study and Literature Review. *Ear Nose Throat J*. 2012;91(3):114–21. doi:10.1177/014556131209100308.
7. Hurst WB. Outcome of 22 cases of perforated tympanic membrane caused by otomycosis. *J Laryngology Otolology*. 2001;115(11):879–80. doi:10.1258/0022215011909486.
8. Stern F, Hinsley FH, Thomas EE, Simkins CAG, Ransom CFG. British Intelligence in the Second World War: Its Influence on Strategy and Operations. Volume III, Part II. *Foreign Affairs*. 1988;67(1):192–192. Available from: <https://dx.doi.org/10.2307/20043728>. doi:10.2307/20043728.
9. Mgbor N, Gugnani HC. Otomycosis in Nigeria: treatment with mercurochrome. *Mycoses*. 2001;44(9-10):395–97. doi:10.1046/j.0933-7407.2001.00682.x.
10. Karn PK, Lakshmanan A, Hemamalini M, Madhavan R. Otomycosis: A study from a tertiary care center. *J Pharm Res*. 2014;8(3):266–8.
11. Rao RP, Rao R. A mycologic study of otomycosis in a tertiary care teaching hospital in Karnataka, India. *Int J Contemp Med Res*. 2016;3(7):1918–20.
12. Agarwal P. Otomycosis in a Rural Community Attending a Tertiary Care Hospital: Assessment of Risk Factors and Identification of Fungal and Bacterial Agents. *J Clin Diagn Res*. 2017;11(6):14–8. doi:10.7860/jcdr/2017/25865.10068.
13. Deshmukh J, Surpam R, Band A. Mycological study of aspergillus infections in otomycosis in eastern part of Maharashtra. *Int J Health Sci Res*. 2014;4(10):77–82.
14. Chapparbandi RB, Kazi FN, Ali K. Otomycosis: An Overview in Hyderabad Karnataka Region. *J Evol Med Den Sci*. 2014;3(46):11213–6. doi:10.14260/jemds/2014/3462.
15. Kumar R, Kumar S, Kumar C. Clinical and microbial study of Otomycosis. *Int J Med Health Res*. 2017;3(1):118–9.
16. Prasad SC, Kotigadde S, Shekhar M, Thada ND, Prabhu P, Souza TD, et al. Primary Otomycosis in the Indian Subcontinent: Predisposing Factors, Microbiology, and Classification. *Int J Microbiol*. 2014;2014:1–9.
17. Kaur R, Mittal N, Kakkar M, Aggarwal AK, Mathur MD. Otomycosis: A Clinicomycologic Study. *Ear Nose Throat J*. 2000;79(8):606–9. doi:10.1177/014556130007900815.
18. Panigrahi M, Paty BP, Parida B, Padhi S, Sahu S, Narasimham I, et al. Clinicomycological Study of Otomycosis with Antifungal Susceptibility Testing Of Fungal Isolates. *IOSR J Dent Med Sci*. 2019;18:7–12.
19. Gupta S, Mahajan B. Prevalance and Demographical Profile of Patients Presenting with Otomycosis. *JK Sci*. 2015;17(3).
20. Yehia MM, Al-Habib HM, Shehab NM. Otomycosis: A common problem in North Iraq. *J Laryngol Otol*. 1990;104(5):387–93. doi:10.1017/s0022215100158529.
21. Zorar L, Fischman O, Suzuki FA, Felipe RG. Otomycosis in São Paulo. *Revista do Instituto de Medicina Tropical de São Paulo*. 1991;33(3):169–73. doi:10.1590/s0036-46651991000300001.
22. Sabz G, Gharaghani M, Mirhendi H, Ahmadi B, Gatee MA, Sisakht MT, et al. Clinical and microbial epidemiology of otomycosis in the city of Yasuj, southwest Iran, revealing *Aspergillus tubingensis* as the dominant causative agent. *J Med Microbiol*. 2019;68(4):585–90. doi:10.1099/jmm.0.000948.

Author biography

Madhulika Mistry, Associate Professor & Laboratory Director

Apurva Pathak, Third Year Resident

Cite this article: Mistry M, Pathak A. To study the prevalence & clino-mycological profile of Otomycosis in Saurashtra & Kutch region of Gujarat. *IP Int J Med Microbiol Trop Dis* 2020;6(4):213-216.