

Content available at: <https://www.ipinnovative.com/open-access-journals>

IP International Journal of Medical Microbiology and Tropical Diseases

Journal homepage: <https://www.ijmmttd.org/>

Original Research Article

Study of keratomycosis at a tertiary care teaching hospital

Ami Jeswin¹, Veluri Gayathri^{2,*}¹Dept. of Microbiology, Al-Azhar Medical College, Thodupuzha, Kerala, India²Dept. of Microbiology, NRI Institute of Medical Sciences, Sanghivalasa, Visakhapatnam, Andhra Pradesh, India

ARTICLE INFO

Article history:

Received 24-11-2020

Accepted 07-01-2021

Available online 25-06-2021

Keywords:

Fungal Keratitis
Bacterial Keratitis
Aspergillus
Fusarium
Candida species

ABSTRACT

Background: Corneal infections are one of the leading causes of ocular morbidity and blindness worldwide. If normal defence mechanisms of the eye are compromised, almost any microorganism can invade the cornea. It is important to know the exact aetiology of corneal ulcer to institute appropriate therapy in time, least serious consequences may follow.

Aim: To isolate and identify the fungi from corneal scrapings of suspected keratitis patients.

Material and Methods: A prospective study of Fungal keratitis was conducted at Al-Azhar Medical College & Super Speciality Hospital in Thodupuzha, Kerala a tertiary care hospital with a capacity of 650 beds. The duration of the study was two years from January 2018 to January 2020. Patients with suspected fungal corneal ulcers presenting in the Out-Patient Department (OPD) of Ophthalmology were investigated for fungal etiology in the Department of Microbiology were included in this study. Each patient was examined with slit lamp. Data collected from history given by patient and patient examination. Using standard techniques. The specimens collected were then smeared on two slides, which were stained with Gram stain (for bacterial keratitis) and 10% potassium hydroxide preparation (for fungal keratitis) studied under light microscope.

Results: Of the 866 patients with corneal ulcer investigated, 83 cases with fungal and 36 with bacterial aetiology was identified. Males were more commonly affected and were mostly in the age group of 31-40 year. It was seen that trauma was the most common predisposing factor especially in the agriculturists and the farmers. Among the identified fungi, most were hyaline. Of the 83 positive specimens, the most frequent agent isolated was Fusarium species in 31 (37.3%) cases. *Aspergillus flavus* 23 (27.7%) was the second most common followed by *Aspergillus fumigatus*, *Penicillium spp.*, *Rhizopus arrhizus*. *Candida albicans* were 5 (6%) followed by *Rhodotorula glutinis* 1 (1.2%).

Conclusion: Fungal Keratitis is a serious problem usually following corneal trauma, it requires rapid detection and identification of fungal agents for treatment to prevent disastrous consequences.

© This is an open access article distributed under the terms of the Creative Commons Attribution License (<https://creativecommons.org/licenses/by/4.0/>) which permits unrestricted use, distribution, and reproduction in any medium, provided the original author and source are credited.

1. Introduction

Fungal keratitis is one of the most devastating microbial keratitis with the worst visual prognosis, potentially leading to blindness.¹ Over 40% of microbial keratitis cases are caused by Fungal infection in several tropical and subtropical countries.² The clinical characteristics of Fungal keratitis are mild pain, the insidious growth of fungal

pathogens in the deep cornea, and difficult to differentiate it from other kinds of microbial keratitis early on. Therefore, the early and accurate diagnosis of Fungal keratitis by means of clinical features is sometimes impossible due to patients' delayed visits or the great similarities of Fungal keratitis with other types of microbial keratitis in early stages of the disease. In addition, conventional laboratory approaches using smears (Direct microscopy) and microbial cultures fail to serve as reliable diagnostic tools in many cases. Direct microscopy is limited by

* Corresponding author.

E-mail address: dr.velurigayathri@gmail.com (V. Gayathri).

examiners' experience, while the culture approach is time-consuming and incapable of isolating fastidious fungal pathogens. As a result, several severe complications such as hypopyon, glaucoma, iris atrophy, cataract, corneal melting, corneal perforation and endophthalmitis may occur in patients with Fungal keratitis.³

Moreover, to the problems of current clinical and laboratory diagnosis, the medical treatment of Fungal keratitis is also full of challenges. Approximately one third of Fungal keratitis patients were refractory to antifungal agents and ultimately required therapeutic keratoplasty.⁴ Currently available antifungal agents have limitations not only in the drug-dependent capacities of corneal penetration but also in species-dependent fungicidal capacity.⁵ In order to rescue the vision of those patients with a delayed visit, minimize the risk of medical treatment failure, and quickly determine the need for surgical management, precise diagnosis is the decisive factor.

The characteristics of ocular surface samples are critical considerations in diagnosing Fungal keratitis because the number of ocular surface samples is low and collected samples usually carry many fewer pathogens than non-ocular samples. Therefore, we first reviewed the characteristics of Fungal keratitis, the clinical diagnosis of Fungal keratitis, the conventional and laboratory diagnosis techniques of Fungal keratitis.

2. Aim

To isolate and identify the fungi from corneal scrapings of suspected keratitis patients.

3. Materials and Methods

The present study was conducted at Al-Azhar Medical College & Super Specialty Hospital in Thodupuzha, Kerala a tertiary care hospital with a capacity of 650 beds. This is a prospective observational study. The duration of the study was two years from January 2018 to January 2020. Patients with suspected fungal corneal ulcers presenting in the Out-Patient Department (OPD) of Ophthalmology were investigated for fungal etiology in the Department of Microbiology were included in this study. A total of 866 cases were tested for suspected fungal and bacterial corneal ulcer during the study period. Fungal and bacterial pathogens were identified in 83 and 36 cases, respectively. Socio-demographic history and information pertaining to the risk factors was recorded. After diagnosing the infective corneal ulcer clinically, under strict aseptic conditions, corneal scrapings were obtained by qualified ophthalmologists of the Hospital and were sent to the Microbiology Department for further processing.

Different modalities of diagnosis are discussed as under:

1. Collection of sample

2. Direct microscopic examination
3. Culture

3.1. Collection of sample

3.1.1. Clinical isolates

Pathogens of Fungal keratitis isolated from microbial cultures of ocular surface samples were obtained via direct scraping of the corneal ulcer, swabbing of the corneal ulcer site and microbes from the tears. The culture media for obtaining fungal isolates include solid and liquid media. Blood agar and chocolate agar were the standard solid media for bacterial keratitis and were able to recover about 56%–79% and 44%–53% of fungal pathogens, respectively.⁶ Sabouraud dextrose agar was thought to be the standard culture medium for Fungal keratitis.⁷ Researchers have suggested omitting this agar due to its time-consuming isolation of fungal pathogens and an even lower recovery rate than blood agar.⁸

3.1.2. Corneal scrapes

Corneal scraping should be performed by either a sterile Kimura spatula or a 15-surgical blade under a bio microscope with a sterile procedure to prevent flora contamination from either the conjunctiva or eyelid.⁹ The sampling area should include not only the margin of the ulcer but also the stroma of the ulcer centre. Some fungal pathogens may invade deeper stroma and a false negative result of the laboratory tests may occur if only superficial samples from the margin of the ulcer are obtained. For deeply invaded Fungal keratitis a corneal biopsy or keratoplasty must be considered to obtain the infectious corneal tissue especially for those with a medically refractory course. For Fungal keratitis breaking through the cornea into the aqueous chamber, aqueous tapping may be considered to obtain aqueous samples and is performed before anterior chamber irrigation with an anti-fungal agent.

3.1.3. Corneal swabs

Corneal swabbing with a transportation medium used initially to minimize the destruction of corneal stromal tissue. Culture results using the single-swabbing approach were more accessible and less cumbersome than corneal scraping and are comparable to the multi-sample method.¹⁰ Subsequent inoculation to the indicated culture media can be assisted by technicians in a clinical microbial laboratory. Therefore, the swabbing approach is suitable for patients with small and superficial ulcers, as well as for ophthalmologists in the community setting who do not have access to the full set of culture media.

3.1.4. Direct microscopy

1. Gram's stain
2. 10% potassium hydroxide preparation

3.2. Culture techniques

The basic technique of laboratory isolation of fungus is inoculation of clinical material into dextrose agar medium known as Sabouraud's Agar.

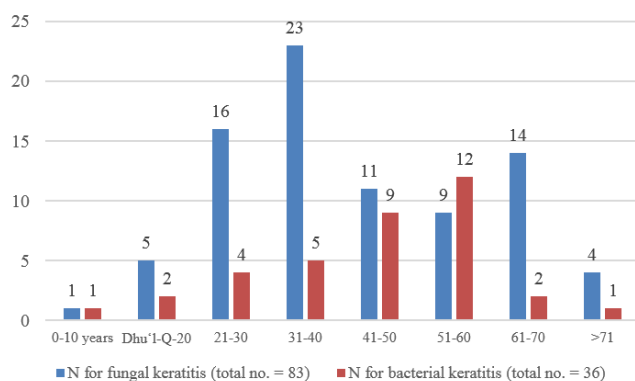
3.3. Statistical analysis

Frequency distributions were obtained and percentages were calculated accordingly.

Statistical analysis was done by Modules Exact test of SPSS.

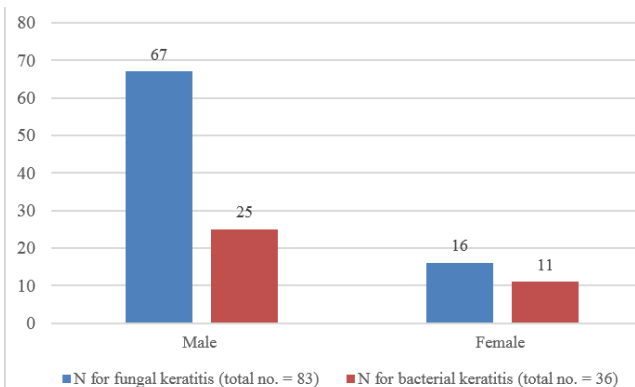
4. Results

A total of 866 cases were tested for suspected fungal and bacterial corneal ulcer during the study period. Fungal and bacterial pathogens were identified in 83 (23.50%) and 36 (11.00%) cases, respectively.



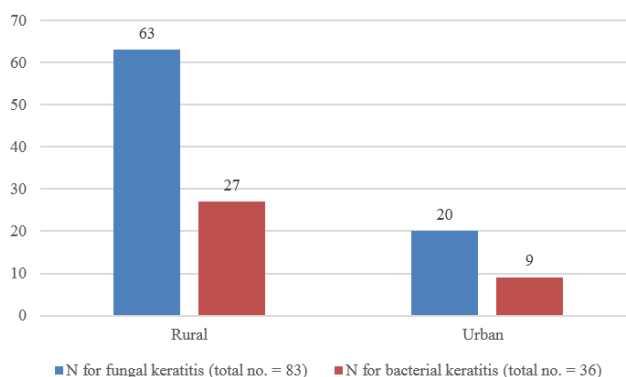
Graph 1: Distribution of age group

Age distribution of the patients is shown in Graph 1, which shows higher prevalence of fungal keratitis between 31 to 40 years 23 (27.71%). Whereas, the most common age group affected of bacterial keratitis from 51 to 60 years 12 (33.33%).



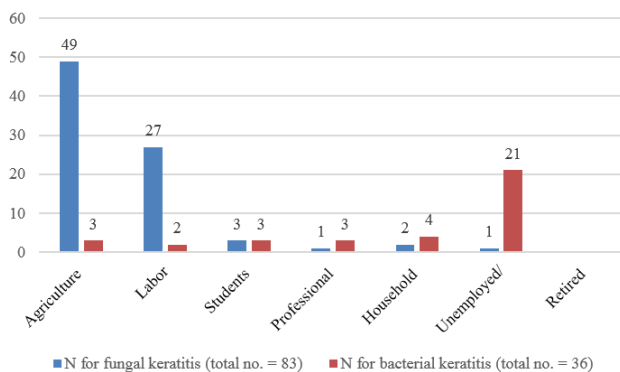
Graph 2: Gender wise distribution of patients

Gender distribution of the patients is shown in Graph 1, out of the total 119 cases of fungal keratitis investigated (67 males and 16 females), bacterial keratitis was associated in 25 (70.5%) males and 11 (29.5%) females.



Graph 3: Distribution of patients according to residence

The prevalence of fungal keratitis was maximum in rural area patients 63% and bacterial keratitis was in 27%.

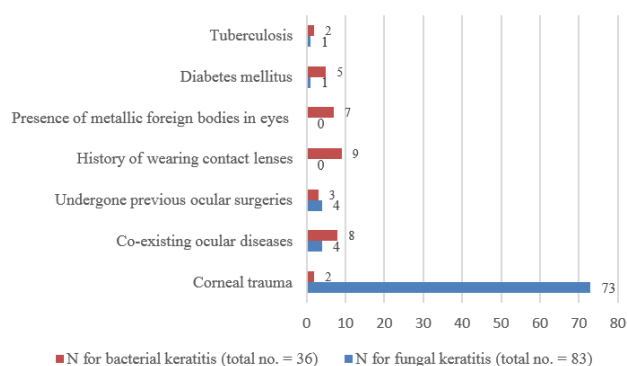


Graph 4: Distribution of patients according to occupation

Among the fungal keratitis cases, the prevalence was found to be more in young and middle-aged agriculturists 57 (59%) and labourers 27 (32.5%). On the other hand, unemployed/retired was 21 (58.3%) and household 4 (11.1%).

In fungal keratitis, corneal trauma was maximum 73 (87.9%). In bacterial keratitis, the history of wearing contact lenses and presence of co-existing ocular diseases 9 (25%) and 8 (22.2%), respectively. A major fraction of the patients diabetic 5 (13.8%).

Among the identified fungi, most were hyaline. Of the 83 positive specimens, the most frequent agent isolated was *Fusarium* species in 31 (37.3%) cases. *Aspergillus flavus* 23 (27.7%) was the second most common followed by *Aspergillus fumigatus*, *Penicillium spp.*, *Rhizopus arrhizus*. *Candida albicans* is 5 (6%) followed by *Rhodotorula*

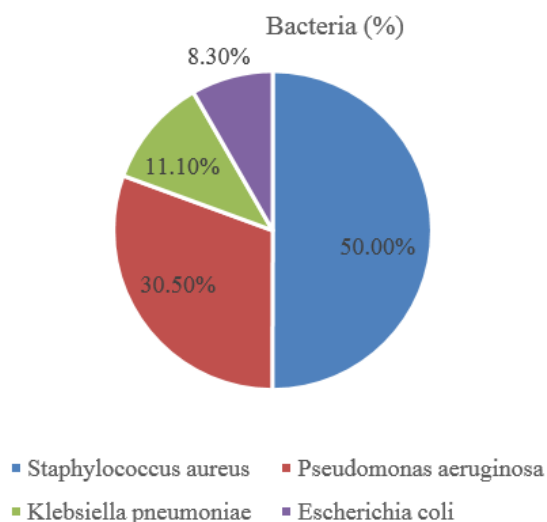


Graph 5: Distribution of patients according to predisposing factors

Table 1: Annual frequency of hyaline and dematiaceous fungi in 83 patients with fungal keratitis

| Fungi | Total (%) |
|------------------------------|------------|
| Hyaline | |
| <i>Fusarium spp.</i> | 31 (37.3%) |
| <i>Aspergillus flavus</i> | 23 (27.7%) |
| <i>Aspergillus fumigatus</i> | 11 (13.2%) |
| <i>Penicillium spp.</i> | 7 (8.4%) |
| <i>Rhizopus arrhizus</i> | 2 (2.4%) |
| Dematiaceous | |
| <i>Curvularia lunata</i> | 3 (3.6%) |
| Yeast | |
| <i>Candida spp.</i> | 5 (6%) |
| <i>Rhodotorula glutinis</i> | 1 (1.2%) |
| Total | 83 |

glutinis 1 (1.2%).



Graph 6: Annual frequency of bacterial isolates in 36 patients with bacterial keratitis.

Out of 866 cases studied, direct microscopic examination for bacteria was positive in 36 cases and isolated by culture. Among the identified bacteria, the most frequent agent isolated was *Staphylococcus aureus* in 18 (50%) cases, followed by *Pseudomonas aeruginosa* in 11 (30.5%)

5. Discussion

Keratitis is the second most common cause of blindness throughout the world and the foremost cause of visual morbidity and associated complications.¹¹ Microbial keratitis is more common in tropical and sub-tropical regions of the world and mycotic keratitis accounts for >50% of these. The causative fungi vary between different geographical regions and climatic conditions.¹²

Mycotic keratitis can occur due to filamentous fungi which is common in tropical and sub-tropical regions, or it can be due to infection by yeast. Keratitis due to filamentous fungi mostly occurs in outdoor workers; in rural setting in agricultural workers and in urban setting in construction workers. Keratitis due to *Candida* usually occurs in patients with pre-existing ocular conditions or chronic systemic diseases, superimposed on ocular virus infections or in contact lens users.¹³

In any region, the trend also shows variation with different seasons of the year and in different age groups. India is a country with diverse geographical features and climatic conditions, varied seasonal deviations and disparate flora and fauna in different regions. The life style and occupations range from rural agricultural population to the inhabitants of mega metropolitan urban cities. The seasonal variation in fungal keratitis cases is not only attributed to the temperature and humidity of the environment, but also to the wind and harvest of crops, which play important role in ocular trauma specially in countries like India.¹⁴ Due to the fact that mycotic keratitis is more common in outdoor workers belonging to lower socio-economic group, males of productive age group are usually affected.

It is pertinent to look deeply into the etiological agents causing fungal eye infections in different geographical regions and their variation over years, across seasons, gender and age groups. The present study was performed in a tertiary care hospital in Kerala, India. Therefore, the findings reflect the trends in fungal eye infections not only in Thodupuzha but in a larger area of Kerala, India.

In the study population, male to female ratio was roughly 2:1, and the maximum numbers of cases were from 31-40 years of age followed by those in 21-30 years. In most of the studies of mycotic keratitis- there was male preponderance, male to female ratio as high as 3.5: 1 has been reported. In another study the most commonly affected age ranging between 16-50 years.¹⁵

The distinct characteristics of patients with fungal keratitis found in our study from rural regions accounted for 76% and urban 24%, whereas bacterial keratitis 75% from

rural and 25% from urban—are consistent with observations made in the majority of other studies. The incidence is reported to be higher in tropical countries.¹⁶

The maximum number of fungal keratitis patients from agriculture farmer 59% and bacterial keratitis were unemployed/retired were 58.3%. Apart from a humid atmosphere, agricultural-based livelihood in this region and unemployed/retired also make the population more vulnerable to fungal infections. People of low socioeconomic classes who were generally farmers and labourers often come in contact with fungal spores during their common day to day outdoor activities which increase their susceptibility to fungal infection. The incidence of farmer is quite similar to the study of Kotigadde who have shown it to be 63%.¹⁷ Majority of the patients 68.75% belonged to low socioeconomic classes, 25% belongs to upper lower class, 6.25% belonged to lower middle class whereas no patient belonged to upper or upper middle class based on Kuppaswamy's socioeconomic classes.¹⁸

In the present study, corneal trauma was the key antecedent factor which was also the predominant risk factor (87.9%). Application of herbal medicines and other self-prescribed treatments like application of various oils, honey, and cow milk to the eye on trauma or foreign body sensation was also reported.¹⁹ On the other hand, bacterial keratitis was commonly seen in co-existing ocular diseases, presence of metallic foreign bodies in eyes and few cases had a history of therapeutic contact lens use is unlikely, as majority of our patients belong to rural background. In those cases, constant irritation of cornea by lens and lack of hygiene seems to predispose the patients to fungal and bacterial keratitis.

In another study in paediatric age group, *Aspergillus* spp. was the most frequent isolate (39.5%) followed by *Fusarium* spp. (10.7%), *Alternaria* (10.2%) and *Curvularia* (7.4%). This study also reported a seasonal variation with peak incidence in months of September and October.²⁰

There is a lot of variation in culture positivity and spectrum of pathogens from different parts of India. From central India, Pune and Mumbai have reported 25.9% and 10.07% positivity respectively, with *Aspergillus* spp. (17.6% and 57% respectively) and *Candida* being the most common isolated mould and yeast respectively.²¹

Two studies from southernmost state of India-Tamil Nadu, have reported 34% culture proven mycotic keratitis from clinical suspects. Both studies have reported *Fusarium* to be the most common isolate (42.8% and 14.5% respectively).²² One of the studies has commented that spectrum of fungal isolates over a duration of 10 years has been stable; the other has shown a non-significant increase in culture isolation during monsoon.²³

In a small study from Kerala (West coast India), 36% of clinically suspected cases of fungal keratitis were culture positive; *Aspergillus* spp (24%) and *Candida* spp (8%) were

the most common isolates reported.²⁴

Another study from Hyderabad- a city in South India has reported 39.8% positivity of fungal culture with *Fusarium* (37.2%) being the most common isolate followed by *Aspergillus* (30.7%). Also, increase in positivity has been reported during monsoon and winter months.²⁵

In a study from London, most common fungal isolates were *Candida* (32.9%) and *Fusarium* (32.9%), followed by *Aspergillus* (8.9%). The authors, while comparing their two studies of years 1994 to 2006 and 2007 to 2014 have reported statistically significant increase in annual number of culture positive fungal keratitis in the latter study. Also, they found that in the earlier study, 59.3% isolates were yeasts and 40.7% were moulds; however, in the second study 70% were moulds and 33% were yeasts (3% being mixed infections of moulds and yeasts).²⁶

A shift in the predominant bacterial pathogens was observed when compared with earlier findings. In our study, 50% of *Staphylococcus aureus* were isolated followed by *Pseudomonas* species 30.5%. Similar finding of isolates of bacteria in a previous study by Hagan et al.²⁷ In reports from Nepal and south India, Gram positive cocci have been reported as the primary cause of bacterial keratitis.²⁸ The proportion of bacterial ulcers caused by *Streptococcus* spp increased in our study. Similar diagnostic criteria were used in the previous study and, therefore, the trend may be attributable to a genuine change of bacterial flora within the geographical area, as influenced by climate and environment. There is a paucity of information in the literature regarding the aetiology of bacterial corneal ulcers in sub-Saharan tropical Africa and, therefore, comparisons are only possible with similar geographical and climatic regions outside the continent of Africa. *Pseudomonas* species were identified as the commonest bacterial isolate in a study of 142 cases of suppurative keratitis in Bangladesh in a study by Dunlop et al and also by Williams et al, who found that 40% of bacterial isolates were *Pseudomonas* spp. A predominance of *Pseudomonas* species has been reported in Hong Kong, Florida, and Paraguay.²⁹

Fungal pathogens were looked for only in clinically suspected cases of mycotic keratitis, we could not prospectively correlate the results with clinical manifestations and response to treatment. Also, we have not analysed the factors responsible for origin of the mycotic keratitis in our patients.

6. Conclusion

Fungal keratitis is often a severe disease in which diagnosis can be challenging, the response to medical treatment is slow, and the clinical outcome is poor. Corneal perforation is 5 to 6 times more likely with fungal keratitis than it is with bacterial keratitis. Because of serious consequences of infectious keratitis, it is important to know the exact aetiology of corneal ulcer to institute appropriate therapy

in time. Laboratory confirmation should be undertaken and fungal infection should be ruled out before prescribing corticosteroids and antibacterial antibiotics.

7. Source of Funding

No financial support was received for the work within this manuscript.

8. Conflicts of Interest

There are no conflicts of interest.

References

- Behrens-Baumann W, Finis D, Mackenzie C. Keratomycosis-Therapy Standards and New Developments. *Klin Monatsbl Augenheilkd*. 2015;232:754–64.
- Mohd-Tahir F, Norhayati A, Ishak SR, Ibrahim M. 2012.
- Wong TY, Fong KS, Tan DT. Clinical and microbiological spectrum of fungal keratitis in Singapore: a 5-year retrospective study. *Int Ophthalmol*. 1997;21(3):127–30.
- Sirikul T, Prabripulaloong T, Smathivat A, Chuck RS, Vongthongsri A. Predisposing Factors and Etiologic Diagnosis of Ulcerative Keratitis. *Cornea*. 2008;27(3):283–7. doi:10.1097/ico.0b013e31815ca0bb.
- Lucca AJD. Harmful fungi in both agriculture and medicine. *Rev Iberoam Micol*. 2007;24:3–13.
- Sharma S, Sahu SK, Garg P, Pradhan L, Nalamada S, Das S, et al. Natamycin in the treatment of keratomycosis: Correlation of treatment outcome and in vitro susceptibility of fungal isolates. *Indian J Ophthalmol*. 2011;59(6):512–14. doi:10.4103/0301-4738.86328.
- Kanafani ZA, Perfect JR. Resistance to Antifungal Agents: Mechanisms and Clinical Impact. *Clin Infect Dis*. 2008;46(1):120–8. doi:10.1086/524071.
- Sharma S, Garg P, Rao GN, Gopinathan U. Review of epidemiological features, microbiological diagnosis and treatment outcome of microbial keratitis: Experience of over a decade. *Indian J Ophthalmol*. 2009;57(4):273–9. doi:10.4103/0301-4738.53051.
- Ibrahim MM, Vanini R, Ibrahim FM. Epidemiology and medical prediction of microbial keratitis in southeast Brazil. *Arq Bras Oftalmol*. 2011;74:7–12.
- Bharathi MJ, Ramakrishnan R, Meenakshi R, Padmavathy S, Shivakumar C, Srinivasan M, et al. Microbial Keratitis in South India: Influence of Risk Factors, Climate, and Geographical Variation. *Ophthalmic Epidemiology*. 2007;14(2):61–9. doi:10.1080/09286580601001347.
- Bharathi MJ, Ramakrishnan R, Meenakshi R, Shivakumar C, Raj DL. Analysis of the risk factors predisposing to fungal, bacterial and Acanthamoeba keratitis in south India. *Indian J Med Res*. 2009;130:749–57.
- Moriyama AS, Hofling-Lima AL. Contact lens-associated microbial keratitis. *Arq Bras Oftalmol*. 2008;71(6):32–6. doi:10.1590/s0004-27492008000700007.
- Behrens-Baumann W, Finis D, Mackenzie C. Keratomycosis-Therapy Standards and New Developments. *Klin Monatsbl Augenheilkd*. 2015;232:754–64.
- Wong TY, Fong KS, Tan DT. Clinical and microbiological spectrum of fungal keratitis in Singapore: a 5-year retrospective study. *Int Ophthalmol*. 1997;21(3):127–30.
- Sirikul T, Prabripulaloong T, Smathivat A, Chuck RS, Vongthongsri A. Predisposing Factors and Etiologic Diagnosis of Ulcerative Keratitis. *Cornea*. 2008;27(3):283–7. doi:10.1097/ico.0b013e31815ca0bb.
- Lucca AJD. Harmful fungi in both agriculture and medicine. *Rev Iberoam Micol*. 2007;24:3–13.
- Mohajernejzhadfarid Z, Daneshgar F, Mansouri M, Tabatabaee A. Keratomycosis after incidental spillage of vegetative material into the eye: Report of two cases. *Oman J Ophthalmol*. 2013;6(2):122–26. doi:10.4103/0974-620x.116659.
- Vergheese S. Post traumatic fungal keratitis caused by *Acremonium* recifei. *Indian J Pathol Microbiol*. 2010;53(3):587–8. doi:10.4103/0377-4929.68263.
- Tanure MAG, Cohen EJ, Sudesh S, Rapuano CJ, Laibson PR. Spectrum of Fungal Keratitis at Wills Eye Hospital, Philadelphia, Pennsylvania. *Cornea*. 2000;19(3):307–12. doi:10.1097/00003226-200005000-00010.
- Zapater RC. Opportunistic fungus infections, *Fusarium* infections (keratomycosis by *Fusarium*). *Jpn Med Mycol*. 1986;27:68–9.
- Keay LJ. Clinical and microbiological characteristics of fungal keratitis in the United States. *Ophthalmology*. 2001;118(5):920–6.
- Thomas PA, Leck AK, Myatt M. Characteristic clinical features as an aid to the diagnosis of suppurative keratitis caused by filamentous fungi. *Br J Ophthalmol*. 2005;89:1554–8.
- Florakis GJ. Scanning Slit Confocal Microscopy of Fungal Keratitis. *Arch Ophthalmol*. 1997;115(11):1461–3. doi:10.1001/archophth.1997.01100160631019.
- Charlebois ED, Das M, Porco TC, Havlir DV. Reply to Wilson et al. Oxford University Press (OUP); 2011. Available from: <https://dx.doi.org/10.1093/cid/cir480>. doi:10.1093/cid/cir480.
- Varaprasathan G, Miller K, Lietman T, Whitcher JP, Cevallos V, Okumoto M, et al. Trends in the Etiology of Infectious Corneal Ulcers at the F. I. Proctor Foundation. *Cornea*. 2004;23(4):360–4. doi:10.1097/00003226-200405000-00009.
- Norina TJ, Raihan S, Bakiah S, Ezanee M, At LS. Microbial keratitis: aetiological diagnosis and clinical features of patients admitted to Hospital Universiti Sains Malaysia. *Singapore Med Journal*. 2008;49:67–71.
- Muller GG, Kara-Jose N, and RSDC. Antifungals in eye infections: drugs and routes of administration. *Rev Bras Oftalmol*. 2013;72(2):132–41.
- Kimakura M, Usui T, Yokoo S, Nakagawa S, Yamagami S, Amano S, et al. Toxicity of Topical Antifungal Agents to Stratified Human Cultivated Corneal Epithelial Sheets. *J Ocul Pharmacol Ther*. 2014;30(10):810–4. doi:10.1089/jop.2014.0044.
- Gallis HA, Drew RH, Pickard WW. Amphotericin B: 30 Years of Clinical Experience. *Clinical Infectious Diseases*. 1990;12(2):308–329. Available from: <https://dx.doi.org/10.1093/clinids/12.2.308>. doi:10.1093/clinids/12.2.308.

Author biography

Ami Jeswin, Assistant Professor

Veluri Gayathri, Professor

Cite this article: Jeswin A, Gayathri V. Study of keratomycosis at a tertiary care teaching hospital. *IP Int J Med Microbiol Trop Dis* 20021;7(2):65-70.