

Content available at: <https://www.ipinnovative.com/open-access-journals>

IP International Journal of Medical Microbiology and Tropical Diseases

Journal homepage: <https://www.ijmmt.org/>

## Original Research Article

## Study of rise in cases of mucormycosis during covid-19 pandemic

Subhadra Tissopi<sup>1</sup>, Vishakha Shikhare<sup>1</sup>, Meena Ramteerthakar<sup>1</sup>, Pankaj A Joshi<sup>1,\*</sup>, Vanita A Kulkarni<sup>1</sup><sup>1</sup>Dept. of Microbiology, Government Medical College, Miraj, Maharashtra, India

## ARTICLE INFO

## Article history:

Received 11-10-2021

Accepted 19-11-2021

Available online 12-02-2022

## Keywords:

COVID19

Rhino-orbital mucormycosis

Diabetes mellitus

Corticosteroids

## ABSTRACT

**Background and Aims:** There are reports of the rise of Rhino-orbital mucormycosis in COVID-19 patients during the second wave of the COVID-19 pandemic in India. Mucormycosis developed in patients who had the history of COVID-19 infection, uncontrolled diabetes mellitus with associated co-morbidities like hypertension, bilateral pneumonia, ischemic heart disease and concurrent use of steroids and oxygen therapy. So, to understand the association of mucormycosis with COVID-19 and other co-morbidities, we conducted a systemic study of mucormycosis in people with COVID-19.

**Materials and Methods:** Tissue samples of patients, clinically and radiologically suspected of mucormycosis, received in microbiology department were examined by KOH mount microscopically and cultured on SDA. The culture isolates were then subjected to lactophenol cotton blue for identification.

**Results and Observations:** A total of 35(72.91%) samples were positive for fungal filaments in either KOH mount or fungal growth on SDA. *Rhizopus* spp. was most commonly isolated in culture, followed by *Mucor* spp. Mucormycosis was predominantly seen in males, 37(77.08%), than in females, 11(22.91%). The commonest risk factors associated with mucormycosis were COVID-19 positivity 42(87.5%) and diabetes mellitus 41(85.41%).

**Conclusion:** To reduce the risk of fungal infection, all efforts should be made to maintain blood glucose levels under control and judicious use of corticosteroids in patients with COVID-19.

This is an Open Access (OA) journal, and articles are distributed under the terms of the [Creative Commons Attribution-NonCommercial-ShareAlike 4.0 License](https://creativecommons.org/licenses/by-nc-sa/4.0/), which allows others to remix, tweak, and build upon the work non-commercially, as long as appropriate credit is given and the new creations are licensed under the identical terms.

For reprints contact: [reprint@ipinnovative.com](mailto:reprint@ipinnovative.com)

## 1. Introduction

COVID-19 is an infectious viral disease caused by the severe acute respiratory syndrome coronavirus 2 (SARS-CoV-2) that was first detected in humans in the month of December, 2019. It causes respiratory symptoms ranging from mild to severe pneumonia.<sup>1</sup> Besides, COVID-19 infection in human beings has found to bring along fungal infections.<sup>1,2</sup>

During the second wave of the COVID-19 pandemic in India, there were reports about the rise of Rhino-orbital mucormycosis in COVID-19 patients.<sup>1</sup> Patients

present with symptoms like headaches, ptosis, facial pain or weakness, blood-tinged nasal discharge, visual disturbances, and pain in the eye.<sup>2,3</sup> Mucormycosis is a rare invasive fungal infection caused by fungi of the order Mucorales like *Rhizopus*, *Mucor*, *Rhizomucor*, *Cunninghamella* and *Absidia*.<sup>2</sup> The main reason that facilitate the germination of Mucorales spores in people with COVID-19 are hypoxia (low oxygen), high glucose (diabetes, new onset hyperglycemia, steroid-induced hyperglycemia), acidic medium (metabolic acidosis, diabetic ketoacidosis [DKA]), high iron levels (increased ferritins) and decreased phagocytic activity of white blood cells (WBC) due to immunosuppression (SARS-CoV-2 mediated, steroid-mediated or background comorbidities).

\* Corresponding author.

E-mail address: [drjpankaj@gmail.com](mailto:drjpankaj@gmail.com) (P. A. Joshi).

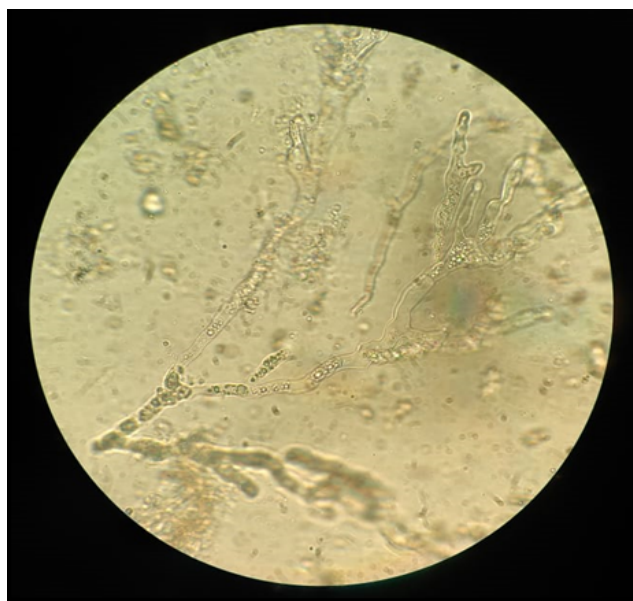
In addition, prolonged hospitalisation with or without mechanical ventilators also contributes to mucormycosis infection in COVID-19 patients.<sup>4</sup> Mucormycosis is a life-threatening infection and the mortality rate is over 50%.<sup>1,3</sup> Thus, to understand its association with COVID-19 and other co-morbidities, it has become necessary to conduct a systematic study of mucormycosis in people with Covid-19.

## 2. Materials and Methods

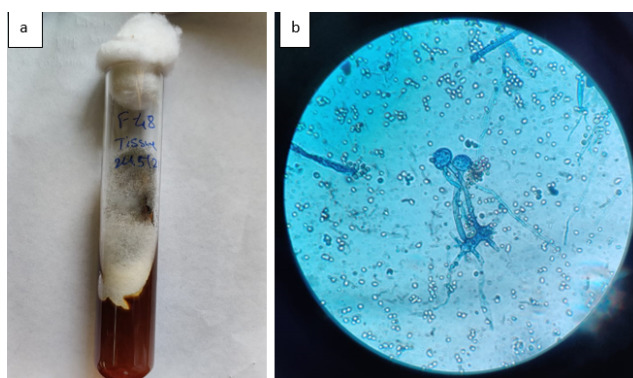
Endoscopic tissue samples of patients, clinically and radiologically suspected of mucormycosis received in the microbiology department were processed for microscopy and culture. A detailed history was obtained from each patient. For microscopy, small amount of sample was placed on a clean slide, a drop of 10% KOH was added, and a cover slip was placed on this. The wet mount was then placed in a wet chamber for 20–30 minutes and examined microscopically using 10x and 40x objectives. Cultures were done on Sabouraud's dextrose agar (SDA) without cyclohexamide and incubated at 37°C. All culture isolates were identified by macroscopic and microscopic examination. The culture isolates were subjected to lactophenol cotton blue and observed under a microscope for identification. On KOH preparation, the samples which showed a characteristic broad, non-septate, ribbon like hyphae with wide angle branching at irregular intervals, on microscopy, were considered as KOH positive (Figure 1). On culture, any dense, white to light grey, fibrous, or cotton candy growth that showed morphology consistent with mucorales on lactophenol cotton blue (LPCB) mount under a microscope was labelled as culture positive (Tables 2 and 3).

## 3. Results and Observations


A total of 48 samples were included in this study in which 35 (72.91%) samples were positive for fungal filaments in either KOH mount or fungal growth on SDA. Of these, 33 samples showed fungal filaments in KOH mount and 12 showed fungal growth [Table 1]. The majority of the culture isolates were *Rhizopus* spp. 8(66.66%), followed by *Mucor* spp. 2(16.66%), *Aspergillus* spp. 1(8.33%) and *Candida* spp. 1(8.33%) [Table 2]. Mucormycosis was found to be more common in males than females, 37(77.08%) compared to 11(22.91%). It was found to be common between the third and seventh decades of life. The common risk factors found to be associated with mucormycosis were COVID-19 positivity 42(87.5%), diabetes 41(85.41%) with concurrent use of oxygen therapy 26(54.16%), corticosteroids 20(41.66%), hypertension 14(29.16%), bilateral pneumonia (6.97%) and ischemic heart disease 2(4.16%) [Table 3]. Diabetes was found to be the most common risk factor apart from COVID-19 positivity, with 18 patients being newly



**Fig. 1:** Broad, ribbon-like, non-septate hyphae with wide angle branching seen in wet mount (KOH x 400)



**Fig. 2:** a: white to light grey mycelia growth of *Rhizopus* spp. after three days of incubation on SDA; b: microscopic appearance of *Rhizopus* spp. (LPCB x 400)



**Fig. 3:** a: light to dull grey mycelia growth of *Mucor* spp. after four days of incubation on SDA; b: microscopic appearance of *Mucor* spp. (LPCB x 400)

diagnosed with diabetes mellitus at the time of presentation. Besides, it was found that the duration of mucormycosis development in COVID-19 positive patients varies from 3 to 45 days.

**Table 1:** Microscopy and culture results.

Type of test	Samples (48)		
	KOH +	Culture +	Culture -
	KOH -	10	23
	KOH -	2	13

**Table 2:** Cultural isolates from tissue samples.

S.No	Culture isolates	Total isolated (12)
1	<i>Rhizopus</i> spp.	8 (66.66%)
2	<i>Mucor</i> spp.	2 (16.66%)
3	<i>Aspergillus</i> spp.	1 (8.33%)
4	<i>Candida</i> spp.	1 (8.33%)

**Table 3:** Risk factors associated with mucormycosis

S.No	Risk factors	Number (%)
1	COVID-19	42 (87.5%)
2	Diabetes mellitus	41 (85.41%)
3	O2 mask	26 (54.16%)
4	Corticosteroids	20 (41.66%)
5	Hypertension	14 (29.16%)
6	Bilateral pneumonia	3 (6.97%)
7	Ischemic heart disease	2 (4.16%)

#### 4. Discussion

Despite the fact that mucormycosis is a rare invasive fungal infection, several cases of mucormycosis in people with COVID-19 have recently been reported.<sup>5</sup> Diabetes mellitus is an independent risk factor for severe COVID-19 as well as mucormycosis.<sup>4,6</sup> A.K. Singh et al. reported that COVID-19 accompanied by immune-compromised states such as long-standing diabetes, HIV (human immunodeficiency virus), tumors, severe prolonged neutropenia, and so on, was more likely to develop fungal co-infection.<sup>7</sup>

As evident from our study, mucormycosis developed in patients who had the history of COVID-19 positivity, uncontrolled diabetes mellitus with background comorbidities like hypertension, bilateral pneumonia, ischemic heart disease and concurrent use of corticosteroids and oxygen therapy.<sup>4,5</sup> In our study, it is apparent that mucormycosis was predominantly seen in males and during the third to seventh decade of life.<sup>4,8</sup> The duration from COVID-19 positivity to presentation of mucormycosis varies from day 3 to 45 days.<sup>8</sup>

In our study, KOH was found to be more sensitive in detecting the fungi as compared to culture. Approximately only one third of the samples positive for KOH were

found to be culture positive.<sup>9</sup> The high number of culture negative findings but microscopically KOH positive can be explained by a number of reasons, such as grinding or homogenization of tissue specimens, which may destroy the delicate hyphae of mucormycetes, the presence of genera that require special culture conditions, recent or ongoing therapy with antifungals effective on Mucorales or even a lack of expertise.<sup>6,9,10</sup> The most common fungi isolated in this study was *Rhizopus* which was followed by *Mucor*.<sup>4,11,12</sup> Co-infection with fungal pathogens like *Aspergillus* and *Candida* has also been observed in COVID-19 patients.<sup>4</sup> Despite early diagnosis and aggressive surgical and medical therapy, the prognosis for recovery from mucormycosis is generally poor.<sup>13</sup> In our study group, out of 48 patients, 5 died during their hospital stay.

#### 5. Conclusion

In this COVID-19 era, all patients presenting with symptoms such as headache, nasal obstruction, crusting, pain in the eye, periorbital edema, ptosis and facial pain and numbness with or without the history of uncontrolled diabetes mellitus should be highly suspicious of mucormycosis. All efforts should be made to maintain diabetes under control and corticosteroids should be used judiciously in patients with COVID-19. As the number of patients included in this study is small, further studies need to be done to understand the association of mucormycosis with COVID-19.

#### 6. Conflict of Interest

The authors have stated explicitly that there are no conflicts of interest in connection with this article.

#### 7. Source of Funding


None.

#### References

- Awal SS, Biswas SS, Awal SK. Rhino-orbital mucormycosis in COVID-19 patients-a new threat. *Egypt J Radiol Nucl Med.* 2021;52(1):1–6.
- Revannavar SM, Supriya PS, Samaga L, Vineeth VK. COVID-19 triggering mucormycosis in a susceptible patient: a new phenomenon in the developing world? *BMJ Case Reports CP.* 2021;14(4):241663. doi:10.1136/bcr-2021-241663.
- Selarka L, Sharma S, Saini D, Sharma S, Batra A, Waghmare VT, et al. Mucormycosis and COVID-19: An epidemic within a pandemic in India. *Mycoses.* 2021;64(10):1253–60. doi:10.1111/myc.13353.
- Singh AK, Singh R, Joshi SR, Misra A. Mucormycosis in COVID-19: a systematic review of cases reported worldwide and in India. *Diabetes Metab Syndr.* 2021;15(4):102146. doi:10.1016/j.dsx.2021.05.019.
- Sarda R, Swain S, Ray A, Wig N. COVID-19 associated Mucormycosis: An epidemic within a pandemic. *QJM.* 2009;114(6):335–56. doi:10.1093/qjmed/haab165.
- Skiada A, Pavleas I, Drogari-Apiranthitou M. Epidemiology and diagnosis of mucormycosis: an update. *J Fungi (Basel).* 2020;6(4):265. doi:10.3390/jof6040265.

7. Song G, Liang G, Liu W. Fungal co-infections associated with global COVID-19 pandemic: a clinical and diagnostic perspective from China. *Mycopathologia*. 2020;31:1–8.
8. Ravani SA, Agrawal GA, Leuva PA, Modi PH, Amin KD. Rise of the phoenix: Mucormycosis in COVID-19 times. *Indian J Ophthalmol*. 2021;69(6):1563–8.
9. Lackner M, Caramalho R, Lass-Flörl C. Laboratory diagnosis of mucormycosis: current status and future perspectives. *Future Microbiol*. 2014;9(5):683–95.
10. Katragkou A, Walsh TJ, Roilides E. Why is mucormycosis more difficult to cure than more common mycoses? *Clin Microbiol Infect*. 2014;20(6):74–81. doi:10.1111/1469-0691.12466.
11. Branscomb R. An overview of mucormycosis. *Lab Med*. 2002;33(6):453–8.
12. Walsh TJ, Gamaletsou MN, Mcginnis MR, Hayden RT, Kontoyiannis DP. Early clinical and laboratory diagnosis of invasive pulmonary, extrapulmonary, and disseminated mucormycosis (zygomycosis). *Clin Infect Dis*. 2012;54(1):55–60.
13. Chamilos G, Lewis RE, Kontoyiannis DP. Delaying amphotericin B-based frontline therapy significantly increases mortality among patients with hematologic malignancy who have zygomycosis. *Clin Infect Dis*. 2008;47(4):503–9.

## Author biography

**Subhadra Tissopi**, Post Graduate Student  <https://orcid.org/0000-0001-8245-6666>

**Vishakha Shikhare**, Associate Professor

**Meena Ramteerthakar**, Associate Professor

**Pankaj A Joshi**, Associate Professor

**Vanita A Kulkarni**, Professor and Head

**Cite this article:** Tissopi S, Shikhare V, Ramteerthakar M, Joshi PA, Kulkarni VA. Study of rise in cases of mucormycosis during covid-19 pandemic. *IP Int J Med Microbiol Trop Dis* 2022;8(1):55-58.