

## An Isolated Hydatid Cyst Of the Lung Spontaneously Evacuated into the Bronchus

Rajendra Prasad Takhar<sup>1,\*</sup>, Moti Lal Bunkar<sup>2</sup>, Rama Kishan Saran<sup>3</sup>, Saroj Mirdha<sup>4</sup>,  
Savita Arya<sup>5</sup>

<sup>1</sup>Assistant Professor, <sup>2</sup>Senior Resident, Dept. of Respiratory Medicine,

<sup>5</sup>Resident, Dept. of Dermatology, Govt. Medical College, Kota, Rajasthan

<sup>3</sup>Associate Professor, Dept. of Surgery, S.N Medical College, Jodhpur, Rajasthan

<sup>4</sup>Medical Officer, Dept. of GNO, Govt. District Hospital, Nagaur, Rajasthan

**\*Corresponding Author**

E-mail: drrajtakhar@gmail.com

---

### Abstract

Pulmonary hydatid cysts are common in endemic regions but isolated active pulmonary hydatid cyst, which is communicated with bronchus, is not a common finding in adult population. Here we present a case of 35-year-old male who presented with breathlessness, cough with expectoration, chest pain and a homogenous rounded opacity of right lower zone on chest X ray. Ultrasound, contrast enhanced computed tomography revealing mass like lesion with multiple internal air pockets with ring enhancement and expectoration of salty material with complete clearing of the lesion following a cough bout confirmed the diagnosis of complicated hydatid cyst communicating with bronchus.

**Key words:** Complicated, Hydatid cyst, Isolated, Intra-bronchial, Lung, Rupture.

---

### Introduction

Pulmonary hydatid cysts or Echinococcosis is parasitic zoonosis, caused by larvae of the tapeworm Echinococcus are common in endemic regions like India. These cysts may virtually occur in any of the body organ but lungs are second only to the liver in frequency of involvement and probably the most common site in children.<sup>[1]</sup> Pulmonary involvement in adults has been reported in 10 - 30% of cases in different series.<sup>[2]</sup>

In adult population a concomitant hepatic cyst is present up to 80% of cases and isolated pulmonary hydatid cyst is not a common observation.<sup>[3]</sup> Although simple pulmonary hydatid cyst can arise anywhere in the lung, but right lower lobe involvement is more frequently reported.<sup>[4]</sup> When a hydatid cyst ruptures into the bronchus or pleural cavity, with or without secondary infection is termed as complicated hydatid cyst<sup>[5]</sup> Here we present a case of isolated complicated pulmonary hydatid cyst in a young adult which spontaneously evacuated into the right lower lobe bronchus following rupture.

### Case Report

A 35-year-old Hindu male, hotel cook by profession, presented to pulmonary medicine outpatient department with breathlessness, cough with expectoration, chest pain, decreased appetite and low grade fever of three month duration. Significant past history included adequate treatment of pulmonary tuberculosis two years back. Patient has had few goats as domestic animals since 20 years.

Physical examination on admission to the hospital showed tachycardia (120/min regular), respiratory rate of 20 breaths per minute, oxygen saturation of 95% on room air, and a blood pressure of 100/60. There was

mild clubbing of the fingers. Examination of the respiratory system revealed dull note, normal vesicular breath sounds of decreased intensity and a few crepitations over the right lower chest posteriorly and laterally. Other systemic examinations were unremarkable. Routine blood examination revealed polymorphonuclear leukocytosis (Total count 13,000/cu.mm, Poly 81 lympho 14 Eosinophils 04). A comprehensive metabolic panel and electro cardiogram were unremarkable. The chest radiograph PA view (Fig. 1) showed a well-circumscribed, dense oval homogenous opacity of 6 x 7cm size with no air bronchogram in the homogenous mid and lower zone.

A contrast enhanced computed tomography (CECT) scan revealed a homogenous rim enhancing cystic lesion of around 6cm in diameter with few air bubbles inside, in the posterior/lateral basal segments communicating with the right lower lobe segmental bronchus along with evidence of old treated tuberculosis in the form of fibrobronchiectatic shadows and volume loss over left upper lobe and apical segment of left lower lobe (Fig. 2a, 2b). Ultrasonography and computed tomography of the abdomen excluded the presence of other cysts in liver or other intra-abdominal organ.

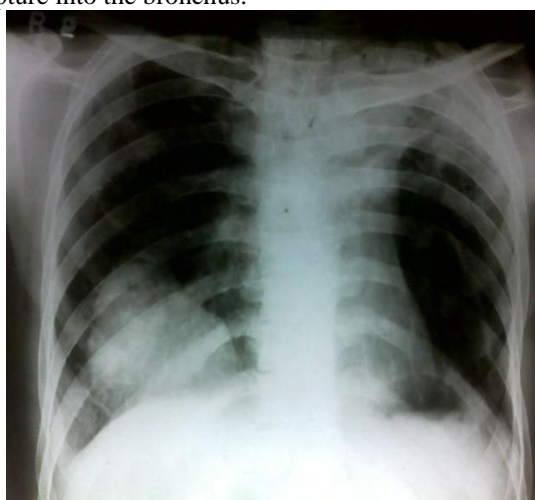
ELISA for echinococcus antigen was significantly positive and a provisional diagnosis of the hydatid cyst was considered and patient was referred for surgical intervention in the form of complete excision of the cyst.

After one month patient presented again with coughing and expectoration of a large amount (approximate 300ml) of salty/sour brownish coloured fluid containing sputum and mucus following some strenuous activity at home. This led to dramatic relief in chest pain and breathlessness. On further questioning

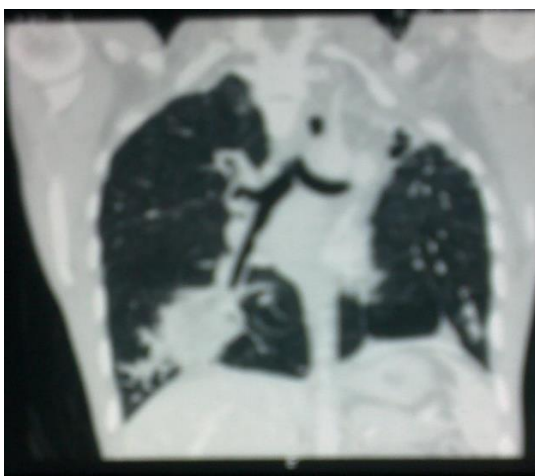patient confessed that he had not attended any cardiothoracic surgeon and went back to home after discharge from our hospital. Patient came with expectorated material in a jar and the histopathological study of this fluid showed presence of fragments of lamellate membrane and scolices of echinococcus, confirming our previous diagnosis of hydatid cyst.

A repeat chest x ray PA view (fig. 3) showed a well-defined oval cavitating lesion without any air-fluid level in the lower zone of right lung abutting the right dome of diaphragm. A chest tomography at this moment revealed a well-defined large spherical air-filled cavity indicating cyst rupture or bronchial evacuation into the segmental bronchus leaving gas content behind and surrounding consolidation in the posterior basal segment of right lung with minimal pleural effusion (Fig. 4).

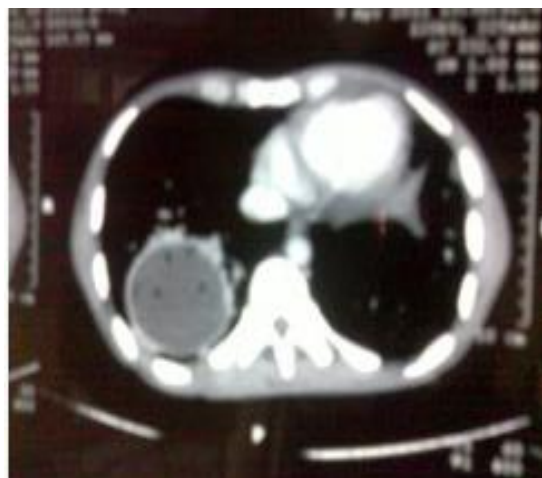All these finding confirmed the diagnosis of isolated pulmonary hydatid cyst with communicating rupture into the bronchus.



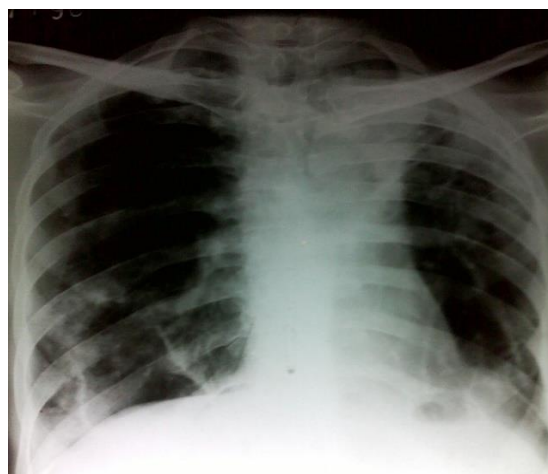**Fig. 1:** Chest X-ray PA view showing a well-circumscribed, oval, mass like lesion in the right mid and lower zone abutting diaphragmatic outline



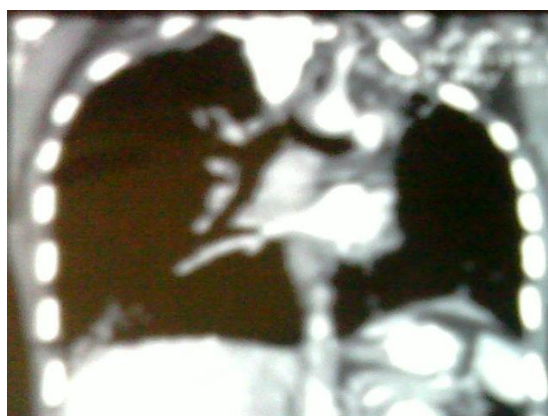**Fig. 2(a):** Coronal CT of chest (lung window) showing well-defined cystic lesion in the right lower lobe



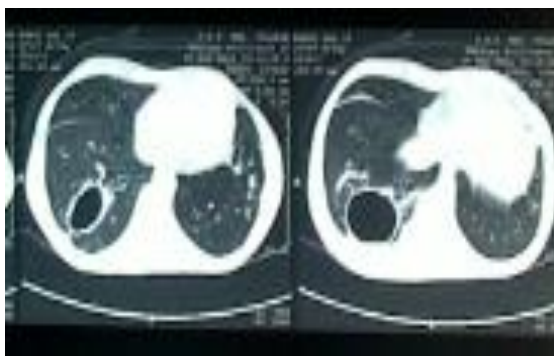**Fig. 2(b):** Axial CT of chest (mediastinal window) showing a homogenous rim enhancing cystic lesion with few air bubbles in the right lower lobe



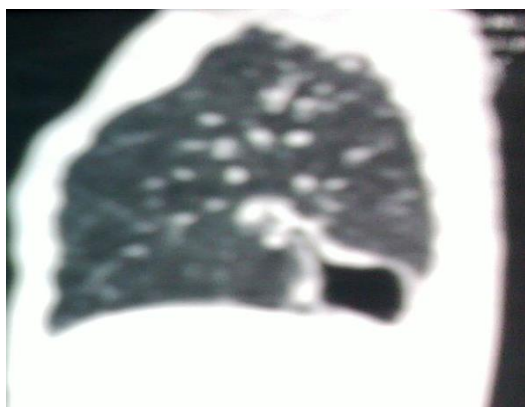
**Fig. 3:** Repeat chest X ray PA view showing a cavitating lesion in the same region indicating complete evacuation of cyst into the bronchus



**Fig. 4(a):** Coronal CT of chest showing absence of cyst with residual air filled cavity lesion and surrounding consolidation in the right lower lobe



**Fig. 4(b): CT axial section shows a large spherical air-filled cavity in the same region following evacuation**



**Fig. 4(c): Sagittal CT section showing the residual air-filled cavity**

## Discussion

Hydatid disease in humans most commonly occurs in the liver (55–70%) followed by the lung (10–35%); the both these organs involved simultaneously in about 5–13% of cases.<sup>[2,6]</sup> Isolated pulmonary involvement in hydatid disease is uncommon.<sup>[7]</sup>

The diagnosis of pulmonary hydatid is primarily based on the clinical presentation, imaging characteristics, predominantly X-ray examinations, computed tomography (CT), ultrasonography to look for associated abdominal hydatids, and confirmation by detection of specific serum antibodies by immunodiagnostic tests like enzyme Linked Immunosorbent assay (ELISA).

Clinical manifestations of ELISA pulmonary hydatid disease (echinococcosis) vary widely depending on the size and site of the cyst and status of the cyst whether it is intact or ruptured. Intact cysts are usually an incidental finding and sometimes may present with cough, dyspnea or chest pain of varying severity when size is large enough to cause pressure symptoms or mechanical effect on organ function. Hydatid cyst of lung parenchyma is called complicated when it ruptures into a bronchus, pleural cavity or biliary tree and they may present with intense cough and expectoration of cystic contents usually described

as salty or sour material, productive cough, repetitive hemoptysis, fever or anaphylactic.<sup>[8]</sup> The patients define this as a salty or peppery water anaphylaxis expectoration, indicating spring-water expectoration, and it may even be an expectoration of membrane particles.<sup>[9]</sup>

Rupture of pulmonary hydatid is the most common complication<sup>[10]</sup> and it can rupture either into the pleural cavity or bronchus.<sup>[11]</sup> If it ruptures into the bronchus, presents as coughing and expectoration of a large amount of salty sputum containing mucus, hydatid fluid, and rarely fragments of the laminated membrane or any acute symptom such as cough with putrid expectoration, hemoptysis, fever, chest pain, vomiting or membrane expectoration, or sudden aggravation in one of these symptoms is indicative of intrabronchial rupture.<sup>[11]</sup>

Ruptured pulmonary hydatid cyst may sometimes cause complications like empyema, bronchopleural fistula, and collapsed lung while sometimes intrabronchial rupture of isolated lung hydatid may relieve all the symptoms like in our case. Hydatid cyst may rupture following any trauma to the chest, or spontaneously as a result of increased intracystic pressure due to progressive enlargement, due to an infectious process, vigorous coughing, or after needle aspiration<sup>[12]</sup> The rupture of pulmonary hydatid may be of three types: Contained, communicating and direct. Communicating and direct forms have more serious clinical implications as they rupture in bronchus and surrounding parenchyma than contained rupture in which cyst contents remains within cyst itself.<sup>[13]</sup> In presented case, a cavity without any air-fluid level and no collapsed germinative layers were noted, a finding consistent with direct rupture of hydatid cyst into right lower bronchus suggestive of complete evacuation of cyst content into the bronchus. Surrounding consolidation and mild pleural effusion was probably due to inflammatory response to endobronchial spread of cyst contents.

The chest radiograph is usually the first investigation in suspected cases of pulmonary hydatid cyst or the uncomplicated hydatid cyst is discovered incidentally when radiograph is taken for some other reason. Unruptured pulmonary hydatid cyst on chest X ray shows single or multiple homogenous round or oval well circumscribed masses with smooth borders surrounded by normal lung tissue. Imaging appearances of hydatid cyst may vary according to its relationship to adjacent lung tissue. Following any secondary infection or rupture into bronchus or other adjacent structure, the radiological appearance may become atypical leading to incorrect and/or delayed diagnosis.<sup>[8]</sup> Ruptured infected hydatid cysts are usually difficult to diagnose radiologically if past documentation of hydatid cyst is not present.<sup>[11]</sup> Computerised tomography is considered as the most sensitive diagnostic tool for detection of ruptured hydatid cyst.<sup>[14]</sup>

Serological tests like Casoni skin test and Weinberg test are not specific<sup>[11]</sup> Confirmation of hydatid disease is done by detection of specific serum antibodies by immunodiagnostic tests like enzyme Linked Immunosorbent assay (ELISA) and titers more than 1:1,600 are usually considered diagnostic<sup>[18]</sup> with overall diagnostic efficacy of 92.3%.<sup>[15]</sup> while the other authors have reported specificity and sensitivity of immunoblot assay to be >99%.<sup>[16]</sup>

CT reveals the hypoattenuating nature of these lesions. On CECT scan, pathognomonic features of ruptured or complicated hydatid cysts include detached or collapsed endocyst membrane, collapsed daughter cyst membranes, and intact daughter cysts.<sup>[17]</sup> When air enters in the hydatid cyst many of well known radiological signs forms like the “meniscus sign,” which occurs when cyst growth produces erosions in the bronchioles in which air is present between the pericyst and the laminated membrane. Air between the endocyst and pericyst creates the “onion peel sign”. The collapsed and crumpled endocyst floats freely and produces the “water lily sign” presence of a thin-walled translucent or cavitory lesion containing air is quite unusual finding in cases of hydatid cyst which was present in our case, post expulsion of cyst material in bronchus.<sup>[19]</sup>

Differential diagnosis of pulmonary hydatid cyst includes tuberculosis, primary and secondary tumors, lung abscess, bronchopulmonary infections, Wegener’s granulomatosis, bronchiectasis, pneumothorax, pleurisy/ loculated pleural effusion and empyema.<sup>[8]</sup>

Treatment of pulmonary hydatid cyst is primarily surgery and the aim of surgery is to remove the cyst completely while preserving the lung tissue as much as possible.<sup>[8]</sup>

## Conclusion

The purpose of reporting this case is to share the feature of spontaneous rupture of pulmonary hydatid, leading to complete evacuation of cyst into the bronchus and complete relief of symptoms requiring no further treatment.

**Conflict of Interest: None**

**Source of Support: Nil**

## References

1. Thumler J, Munoz A. Pulmonary and hepatic echinococcosis in children. *Pediatr Radiol.* 1978;7:164–71.[PubMed]
2. Fraser RS, Muller NL, Coleman N, Pare PD. Protozoa, Helminths, Arthropods and Leeches. In: Fraser and Pare’s Diagnosis of diseases of the chest. 4th ed. WB Saunders Philadelphia. 1999;1033-66.
3. Kanat F, Turk E, Aribas OK. Comparison of pulmonary hydatid cysts in children and adults. *ANZ J Surg.* 2004;74:885–9. [PubMed]
4. Morar R, Feldman C. Pulmonary echinococcosis. *Eur Respir J.* 2003;21:1069–77. [PubMed]
5. Kuzucu A, Soysal O, Ozgel M, Yologlu S. Complicated hydatid cysts of the lung: Clinical and therapeutic issues. *Ann Thorac Surg.* 2004;77:1200–4. [PubMed]
6. Saidi F. Treatment of echinococcal cysts. In: Nyhus LM, Baker RJ, Sabiston DC, editors. *Mastery of surgery.* 2nd ed. London: Little, Brown and Company; 1992. p. 818–37.
7. Harlaftis NN, Altreas HA, Panagiotis SN. Hydatid disease of the lung. In: Shields TW, LoCicero J, Ponn RB, Rusch VW, editors. *General Thoracic Surgery.* 6th Ed. Philadelphia: Lippincott Williams & Wilkins, P.1298.
8. Ihsan Alloubi (2013). *Thoracic Hydatid Cyst: Clinical Presentation, Radiological Features and Surgical Treatment, Principles and Practice of Cardiothoracic Surgery,* Dr. Michael Firstenberg (Ed.), ISBN: 978-953-51-1156-6, InTech, DOI: 10.5772/53533. Available from: <http://www.intechopen.com/books/principles-and-practice-of-cardiothoracic-surgery/thoracic-hydatid-cyst-clinical-presentation-radiological-features-and-surgical-treatment>. Last accessed on 15 december 2015.
9. Xanthakis D, Efthimiadis M, Papadakis G, Primikiriou N, Chassapakis G, Roussaki A, et al. Hydatid disease of the chest Report of 91 patients surgically treated. *Thorax* 1972;27(5):517-28.
10. Doğan R, Yüksel M, Cetin G, Süzer K, Alp M, Kaya S, et al. Surgical treatment of hydatid cysts of the lung: report on 1055 patients. *Thorax* 1989;44(3):192-9.
11. Balci AE, Eren N, Eren S, and Ulka R, “Ruptured hydatid cysts of the lung in children: clinical review and results of surgery,” *Annals of Thoracic Surgery*, vol. 74, no. 3, pp. 889–92, 2002.]
12. Mouaqit O, Hibatallah A, Oussaden A, Maazaz K, Taleb KA. Acute intraperitoneal rupture of hydatid cysts: a surgical experience with 14 cases. *World Journal of Emergency Surgery.* 2013 Jul 26;8(1):28.[PMC free article] [PubMed]
13. Lewall DB, McCorkell SJ. Rupture of echinococcal cysts: diagnosis, classification, and clinical implications. *AJR Am J Roentgenol* 1986;146(2):391-4.
14. B. Gulalp, Z. Koseoglu, N. Toprak et al., “Ruptured hydatid cyst following minimal trauma and few signs on presentation,” *Netherlands Journal of Medicine*, vol. 65, no. 3, pp. 117–8, 2007
15. Balamurali Srinivasan & Prashant Nanasahab Mohite & Shyam Kumar Thingnam. Extrapulmonary intrapleural hydatid cysts—rare variant of uncommon disease. *Indian J Thorac Cardiovasc Surg* (2010)26:247–50.
16. Sbihi Y, Rmiqui A, Rodriguez-Cabezas MN, Orduña A, Rodriguez-Torres A, Osuna A. Comparative sensitivity of six serological tests and diagnostic value of ELISA using purified antigen in hydatidosis. *J Clin Lab Anal.* 2001;15:14–8. [PubMed]
17. G. H. Basavana, G. Siddesh, B. S. Jayaraj, and M. G. Krishnan, “Ruptured hydatid cyst of lung,” *Journal of Association of Physicians of India*, vol. 55, pp. 141–145, 2007.
18. Koul PA, Koul AN, Wahid A, Mir FA. CT in pulmonary hydatid disease: unusual appearances. *Chest.* 2000;118:1645–47.
19. Polat P, Kantarci M, Alper F, Suma S, Koruyucu MB, Okur A. Hydatid disease from head to toe. *Radiographics* 2003;23:475–94.