

Content available at: <https://www.ipinnovative.com/open-access-journals>

IP International Journal of Medical Microbiology and Tropical Diseases

Journal homepage: <https://www.ijmmt.org/>

Case Report

Isolation of salmonella typhi from pleural empyema necessitans- A case report from a tertiary care hospital, Bangalore, Karnataka

Supriya Dey¹, Girish Narayanaswamy^{1,*}¹Dept. of Microbiology, Vydehi Institute of Medical Sciences & Research Centre, Bangalore, Karnataka, India

ARTICLE INFO

Article history:

Received 02-11-2022

Accepted 15-11-2022

Available online 28-12-2022

Keywords:

Empyema necessitans

Salmonella enterica serotype typhi

Pleural cavity abscess

Bacteremia

Extraintestinal Antimicrobial therapy

ABSTRACT

Pleural Empyema necessitans refers to the extension of an empyema out of the pleural space and in to the neighbouring chest wall and surrounding soft tissues.

Salmonella typhi is a versatile pathogen with amazing potential of infecting almost all organs of its host. Globally, the life threatening illness caused by Salmonella typhi have made this pathogen a serious health concern for infection control professionals. Salmonella typhi usually manifests as a febrile illness with bacteremia after initial entry through the gastrointestinal route, but it can occasionally cause significant disease in extraintestinal sites. Various microbes have been found associated with pleural cavity abscesses that ultimately lead to high morbidity and mortality rates, but pulmonary involvement due to Salmonella typhi is rare. We are reporting an unusual and rare case of pleural cavity abscess caused by Salmonella typhi in a 44 years old febrile patient, admitted to a tertiary care hospital, Bangalore with a complaints of swelling on the left sided chest wall. Diagnosis was made by HRCT THORAX which revealed an well defined hypodense collection with peripheral rim enhancement in anterior chest wall around 7th to 8th costochondral junction, communication with left pleural cavity. Pus was collected from the abscess by incision and drainage. Salmonella enterica serotype typhi was isolated from the sample. Patient was put on appropriate antimicrobial therapy.

This is an Open Access (OA) journal, and articles are distributed under the terms of the [Creative Commons Attribution-NonCommercial-ShareAlike 4.0 License](https://creativecommons.org/licenses/by-nc-sa/4.0/), which allows others to remix, tweak, and build upon the work non-commercially, as long as appropriate credit is given and the new creations are licensed under the identical terms.

For reprints contact: reprint@ipinnovative.com

1. Background

Empyema necessitans is a rare long term complication of poorly or uncontrolled empyema thoracis characterised by the dissection of pus through the soft tissues and skin of the chest wall the pus collection bursts and communicates with the exterior, forming a fistula between the pleural cavity and the skin.¹

Salmonella enterica serotype typhi is a human specific bacteria that causes a systemic infection known as typhoid fever. Salmonellae are gram negative, facultatively anaerobic, non sporing motile bacilli. Humans acquire Salmonella typhi infection through ingestion

of contaminated food or water.²The common clinical manifestations of typhoid fever include intermittent fever, headache and gastrointestinal symptoms such as abdominal pain, diarrhea, constipation, vomiting and loss of appetite.³ Localized infections develop in approximately 5-10% cases with salmonella bacteremia and the presentation may be delayed. Extra intestinal infectious complication especially pleural cavity abscess due to Salmonella species is extremely rare.⁴ We report a case of left sided subcutaneous anterior chest wall abscess communicating with left pleural cavity(empyema necessitans) caused by Salmonella typhi in a 44 years old man in a tertiary care hospital, Bangalore.

* Corresponding author.

E-mail address: girishdasanur@yahoo.co.in (G. Narayanaswamy).

2. Case Report

A 44 years old male presented to the Surgery Department of a tertiary care in Karnataka in September 2022 with complaints of swelling on left side of chest since 2months, low grade fever since 15 days and breathlessness at night time since 10days. The swelling was small initially but slowly it increased in size. He was a known case of Type 2DM since 3years on Tab Metformin and Glimeperide 500/2mg.

On admission, the patient was moderately built and nourished conscious, oriented to time, place and person. His vitals were as follows.

PR-88 BPM, BP-110/70 MMHG, RR-18/MIN, SPO2-97%@ROOM AIR, Temperature: 100⁰F.

There was no signs of Pallor, Icterus, Cyanosis, Clubbing, Oedema. He was evaluated by a surgeon who on examination found a 8x5 cm horizontally oval swelling, over the 8th, 9th, 10th rib of anterior chest wall with an ill defined edge without any active discharge. Surrounding skin was erythematous. There was no visible pulsations or peristalsis and no impulse on coughing. On palpation it was tender and there was local rise of temperature. Respiratory examination revealed harsh vesicular breathing with scattered left basal crepitus.

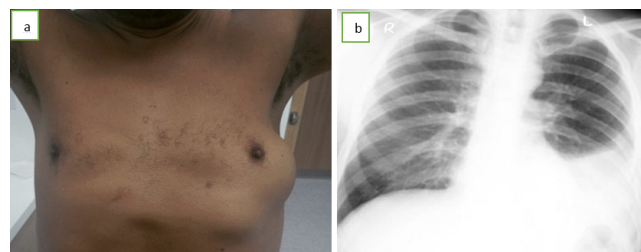


Fig. 1: a: Clinical finding; **b:** Chest X ray PA view

Provisional diagnosis was done CECT Thorax which revealed an well-defined hypodense collection with peripheral rim enhancement in the anterior chest wall around the 7th and 8th costochondral junctions showing a communication with the left pleural cavity likely abscess * ??Left-sided pleural effusion. SURFACE SCAN of area of interest was done on same day which showed an anechoic collection with internal echoes noted in the subcutaneous and intramuscular plane in the left chest wall with a same volume of 350-400c.

His RBS was 290mg/dl, HBA1C was 12.4%, Hemoglobin was 11.4 g/dl, white blood count was 15.1 x10⁹/l red blood cells count was 4.06million/mcL, platelet count was 635000 platelets/ μ L.

The patient was started on inj Piperacillin & Tazobactam 4.5GM thrice a day, and had undergone incision and drainage with thoracotomy and lobectomy done UNDER GA. About 700 ml of pus drained from the abscess cavity involving 7th and 8th intercostal space and ribs

near the costochondral junction. As abscess cavity was communicating to the deeper structures of left pleural cavity, hence Incision was extended to thoracotomy incision, Loculi in the pleural cavity was broken down and left lower lobectomy was done with an ICD insertion on the left 7th intercostal space. Pus sample was sent to the Microbiology laboratory for culture and sensitivity. AFB smears of pus sample was negative. Gram stain of pus showed numerous pus cells and few gram negative bacilli. The pus sample was inoculated on 5% sheep Blood agar and on MacConkey agar and incubated at 37⁰C aerobically for 24 hours. After overnight incubation, culture of the pus sample yielded pure growth of non lactose fermenting colonies on MacConkey agar, greyish colonies on Blood agar. Culture smears showed Gram negative rods, catalase test was positive, oxidase test was negative, and hanging drop revealed motile bacteria.

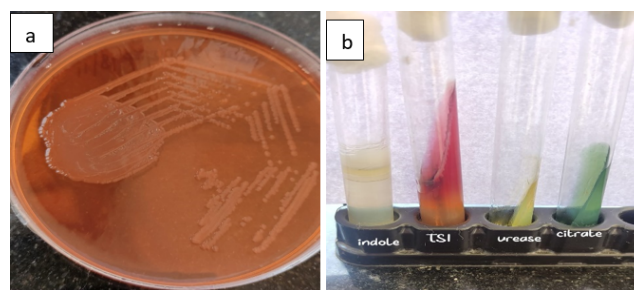


Fig. 2: a: Growth on MacConkey plate; **b:** Biochemical reactions.

Identification of the organism was done by automated VITEK 2 system as well as by the Biochemical reactions. The organism was identified as *Salmonella typhi*. This was confirmed by type specific antisera. Antimicrobial susceptibility testing was carried out on the Mueller - Hinton agar using Clinical Laboratory Standard Institute criteria. The antimicrobials tested were Ampicillin 10 μ g, Chloramphenicol 30 μ g, Cotrimoxazole 25 μ g, Ceftriaxone 30 μ g, Ciprofloxacin 5 μ g, Azithromycin 15 μ g. The organism was sensitive to Ampicillin, Azithromycin, Ceftriaxone, Ciprofloxacin, Cotrimoxazole while being resistant to Chloramphenicol. After the sensitivity report was available, inj PIPERACILLIN & TAZOBACTAM was stopped and inj Ceftriaxone 1 gm I/V 12 hourly was started for 7 days along with other supportive therapy. After 72 hours of treatment the patient was afebrile. The patient was discharged after 7 days on oral cefixime 400 mg 12 hourly for another 1 week.

3. Discussion

Salmonella species are a group of gram negative bacilli and known human pathogen. They are facultative anaerobic, motile bacilli commonly isolated from the intestines of humans and animals. Identification is primarily based on the ability of the organism to use citrate as the sole carbon

source and lysine as a nitrogen source in combination with hydrogen sulfide production. The genus is comprised of two primary species, *S. enterica* (human pathogen) and *S. bongori* (animal pathogen). *S. enterica* is subdivided into six subspecies: subspecies *enterica*, subspecies *salamae*, subspecies *arizonae*, subspecies *diarizonae*, subspecies *houtenae*, and subspecies *indica*. *S. enterica* subspecies *enterica* can be further divided into serotypes with unique virulence properties. Serotypes are differentiated based on the characterization of the heat stable O antigen, included in the LPS, the heat labile H antigen flagellar protein, and the heat labile Vi antigen, capsular polysaccharide.⁵ *Salmonella typhi* is endemic in India which causes typhoid fever or gastroenteritis.⁶ They receive more attention because of the higher morbidity and mortality and their multi drug resistant nature.⁷ Salmonellosis is a major cause of bacterial enteric illness in both humans and animals. Human infections with salmonellae are most commonly caused by ingestion of food, water, or milk contaminated by human or animal excreta. Salmonellae are primary pathogens of lower animals (eg- poultry, cows, pigs, pets, birds, sheep, seals, lizards and snakes), which are the principal source of nontyphoidal salmonellosis in humans.⁸ The most important complications of typhoid fever are Intestinal perforation, Hemorrhage and Circulatory collapse.⁹ Pleural Empyema Necessitans due to *Salmonella typhi* is very rare and unusual and very few reports of *Salmonella typhi* isolation from pleural empyema were available in India.⁴

4. Source of Funding

None.

5. Conflicts of Interest

There is no conflict of interest.

References

1. S M, Pattnaik D, Swine B. Pleural Empyema due to salmonella typhi: A case report. *J Coll Physicians Surg Pak*. 2004;47:75–6.
2. Huang DB, DuPont HL. Problem pathogens: extra-intestinal complications of *Salmonella enterica* serotype Typhi infection. *Lancet Infect Dis*. 2015;5(6):341–8. doi:10.1016/S1473-3099(05)70138-9.
3. Rim MS, Park CM, Ko KH. Pleural empyema due to *Salmonella*: A case report. *Korean J Intern Med*. 2000;15(3):138–41.
4. Cohen JI, Barlttt JA, Corey GR. Extra-intestinal manifestations of salmonella infections. *Medicine (Baltimore)*. 1987;66(5):349–88. doi:10.1097/00005792-198709000-00003.
5. Kainat S, Tariq N. Isolation of salmonella typhi from perinephric abscess- a case report from national medical hospital. *J Bacteriol Mycol*. 2016;3(4):302–4. doi:10.15406/jbmoa.2016.03.00075.
6. Kaur A, Sarma S. Renal abscess caused by *Salmonella typhi*. *J Lab Physicians*. 2015;7(2):121–3.
7. Komus N, Gunes J. Pleural empyema due to *S.typhi*. *Tuberk Torak*. 2005;53:397–400.
8. Cabral JPS. Water Microbiology. Bacterial Pathogens and Water. *Int J Environ Res Public Health*. 2010;7(10):3657–703.
9. Afridi FI, Farooqi BJ, Hussain A. Pleural empyema due to salmonella typhi. *J Coll Physicians Surg Pak*. 2012;22(12):803–5.

Author biography

Supriya Dey, Assistant Professor

Girish Narayanaswamy, Professor

Cite this article: Dey S, Narayanaswamy G. Isolation of salmonella typhi from pleural empyema necessitans- A case report from a tertiary care hospital, Bangalore, Karnataka. *IP Int J Med Microbiol Trop Dis* 2022;8(4):336-338.