

Content available at: <https://www.ipinnovative.com/open-access-journals>

IP International Journal of Medical Microbiology and Tropical Diseases

Journal homepage: <https://www.ijmmt.org/>

Case Report

Eumycetoma infection of the hand: A case report

Jyoti Tomar^{1,*}, Neelima Goyal¹, Ketki Jangid¹

¹Dept. of Microbiology, Pacific Institute of Medical Sciences(PIMS), Umarda, Udaipur, Rajasthan, India



ARTICLE INFO

Article history:

Received 10-11-2022

Accepted 24-11-2022

Available online 28-12-2022

Keywords:

Eumycetoma
Itraconazole
serosanguineous
Black grains

ABSTRACT

Mycetoma is a chronic granulomatous infection of cutaneous and subcutaneous tissues caused by filamentous bacteria (actinomycetoma) or fungi (eumycetoma). The most common site of infection is the foot, followed by the hand, but sometimes other body parts may also be infected. The patients present with a painless hard and swelling subcutaneous mass, multiple sinuses, and the pathognomonic discharge of grains. A 42-year-old male patient, presented pain and swelling in his right hand and also complained of swelling in his right forearm. The swelling later involved his whole right hand and wrist joint. Physical examination revealed multiple discharging sinuses with serosanguineous exudates and black grains. Swelling and local erythema were present, lymph nodes were not palpable. The patient complained of constant mild pain which is relieved by pain medications. The serohematic discharge was witnessed with conglomerates of small and firm blackish pellets, evoking eumycetoma. Saline dressing was applied overnight and next morning grains were directly collected from sinuses. Tissue and black grain samples were analyzed for bacterial and mycological evaluation. Direct microscopy was performed using Gram stain showed thicker hyphae of eumycetoma. Modified ZN stain showed no acid fast bacilli. LPCB was helpful in confirming thicker hyphae of eumycetoma. Here, on clinical diagnosis (classical triad that is, painless soft tissue swelling, draining sinuses and extrusion of grains) with microbiological investigation, we concluded it a case of “Eumycetoma”.

This is an Open Access (OA) journal, and articles are distributed under the terms of the [Creative Commons Attribution-NonCommercial-ShareAlike 4.0 License](https://creativecommons.org/licenses/by-nc-sa/4.0/), which allows others to remix, tweak, and build upon the work non-commercially, as long as appropriate credit is given and the new creations are licensed under the identical terms.

For reprints contact: reprint@ipinnovative.com

1. Introduction

Mycetoma is a chronic granulomatous infection of cutaneous and subcutaneous tissues which is caused by filamentous bacteria (actinomycetoma) or fungi (eumycetoma).¹ Mycetoma mainly infects young male field workers in rural area.² Mycetoma usually results from small traumatic implantation of the causative agent in the subcutaneous tissue.³ The most common site of infection is the foot, followed by the hand, but sometimes other body parts may also be infected.⁴ The patients present with a painless hard and swelling subcutaneous mass, multiple sinuses, and the pathognomonic discharge of grains.⁵

* Corresponding author.

E-mail address: jyotibst1998@yahoo.com (J. Tomar).

2. Case Report

We describe a case of a 42-year-old male patient, from Udaipur, Rajasthan, who presented with pain and swelling in his right hand for the past 4 years. The patient also complained of swelling in his right forearm for the past 6 months. The biological assessment didn't show any signs of bacterial infection.

The patient joined the Indian armed forces at 18 years of age. The patient was deployed in Tamil Nadu for 2 years (2017-2018) where he came in contact with wild bushes and remembers being pricked by thorns multiple times. In 2018 when he returned to Rajasthan he noticed a small swelling in his right thumb. He went to some Bikaner Government Hospital and was diagnosed with a case of Mycetoma. He

was prescribed Septran and Itraconazole. The patient had no relief and his symptoms worsened. He went to Jaipur government hospital in 2019 where they prescribed the same Itraconazole medications. The swelling later involved his whole right hand and wrist joint. The patient is unable to perform daily functions using his right hand. The patient came to our hospital in June 2022 Physical examination revealed multiple discharging sinuses with serosanguineous exudates and black grains (Figures 1 and 2), located on the dorsum of the right hand and wrist. Swelling and local erythema were present, lymph nodes were not palpable. The swelling in the forearm was around 15 x 12 cm in size with no erythema or sinus tracts. The patient complained of constant mild pain which is relieved by pain medications.

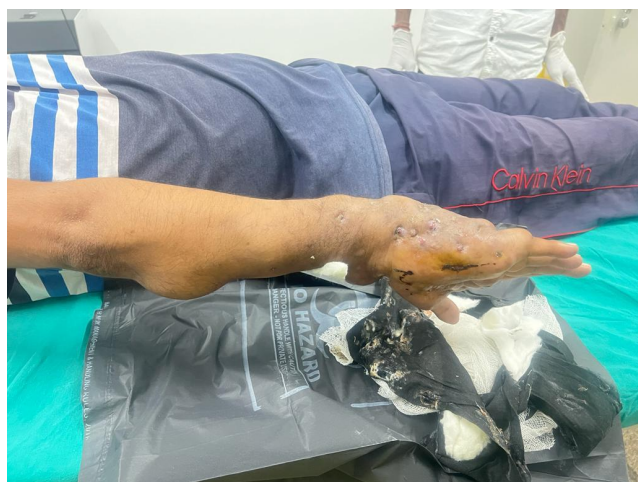

Fig. 1: Clinical case presenting multiple discharging sinuses with serosanguineous exudates and black grains.

2.1. Investigations

The serohematic discharge was witnessed with conglomerates of small and firm blackish pellets, evoking eumycetoma. Tissue and black grain samples (Figure 2), were analyzed for bacterial and mycological evaluation. For specimen collection: Saline dressing was applied overnight and next morning grains were directly collected from sinuses. Grains were examined in two ways, direct microscopy and culture. Direct microscopy was performed using Gram stain showed thicker hyphae of eumycetoma (Figure 3). Modified ZN stain showed no acid fast bacilli. LPCB was helpful in confirming thicker hyphae of eumycetoma.

Histology was not needed as drainage material was sufficient and culture results were conclusive.

Radiological evaluation by computed tomography showed multiple lytic lesions with cortical destruction in the right distal radius, distal ulna, metacarpal, and



Fig. 2: Black grains received in laboratory

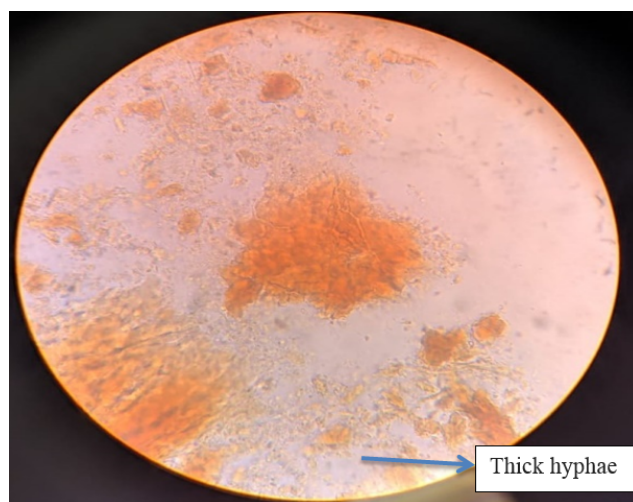


Fig. 3: Thicker hyphae of eumycetoma

phalanges with non-visualization of the proximal part of the fourth metacarpal and few carpal bones surrounding significant soft tissue edema (Figure 4).

Here, based on clinical diagnosis (classical triad that is, painless soft tissue swelling, draining sinuses and extrusion of grains) with microbiological investigation, we concluded it a case of “Eumycetoma”

Here, based on clinical diagnosis (classical triad that is, painless soft tissue swelling, draining sinuses and extrusion of grains) with microbiological investigation, we concluded it a case of “Eumycetoma”

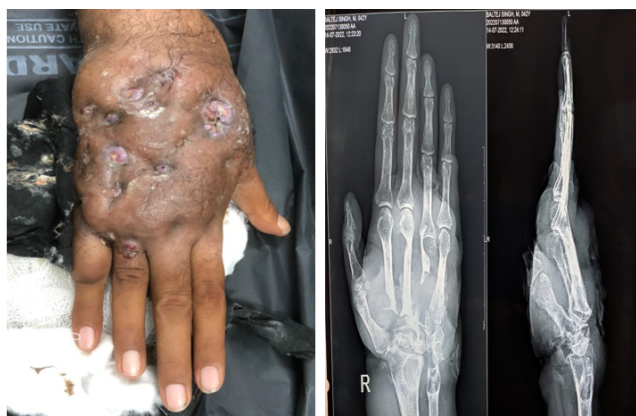

Fig. 4: multiple lytic lesions with cortical destruction in the right distal radius, distal ulna, metacarpal, and phalanges

2.2. Treatment

As eumycetoma respond less well to oral drug treatment, so we advised to combine surgical and medical treatment. Surgical debridement has been done and now patients has been put on capsule itraconazole 400 mg/day.

3. Discussion

Mycetoma is a chronic suppurative infection that infects the skin and subcutaneous tissue. It is endemic in tropical and subtropical regions of Africa, Mexico, and India. It commonly affects people between 20 and 50 years of age with a male to female ratio of 2.2:1.⁶

Mycetoma predominantly presents in agricultural workers but it can also occur in the general population. Repeated minor trauma or penetrating injury by thorns or splinters provides a portal of entry for the organism.⁷

Mycetoma infection can be caused by fungi or bacteria. The two groups of mycetoma are the Actinomycotic and Eumycotic groups. Actinomycetoma is caused by a group of filamentous bacteria that include *Nocardia* and *Streptomyces* species.⁸ Eumycetoma is caused by a group of fungi like *Allescheria boydii*, *Madurella griesia*, and *Madurella mycetomi*.⁸

The three cardinal features of mycetoma are tumefaction, multiple sinus tracts, and the presence of grains in the affected tissue.⁹ Our patient presented with diffuse swelling of the right hand with multiple sinuses discharging black grains. The size, color, and consistency of the grains found in the discharge are indicative of the species and are helpful to initiate appropriate treatment.¹⁰ Grains of different species may have similar morphological features,

so culture is needed for definitive diagnosis.¹⁰ Mycetoma can lead to high morbidity. An early diagnosis and treatment are required in preventing disease progression.

4. Source of Funding

None.

5. Conflicts of Interest

There is no conflict of interest.

References

1. Zijlstra EE, Van De Sande W, Welsh O, Mahgoub ES, Goodfellow M, Fahal AH, et al. Mycetoma: a unique neglected tropical disease. *Lancet Infect Dis.* 2016;16(1):100–12. doi:10.1016/S1473-3099(15)00359-X.
2. Reis CMS, De MRFE. Mycetomas: An epidemiological, etiological, clinical, laboratory and therapeutic review. *An Bras Dermatol.* 2018;93(1):8–18. doi:10.1590/abd1806-4841.20187075.
3. van de Sande W. Global Burden of Human Mycetoma: A Systematic Review and Meta-analysis. *PLoS Negl Trop Dis.* 2013;7(11):e2550. doi:10.1371/journal.pntd.0002550.
4. Relhan V, Mahajan K, Agarwal P, Garg VK. Mycetoma: An Update. *Indian J Dermatol.* 2017;62(4):332–40. doi:10.4103/ijid.IJD_476_16.
5. Ahmed AOA, Van Leeuwen W, Fahal A, Van De Sande W, Verbrugh H, Van Belkum A, et al. Mycetoma caused by *Madurella mycetomatis*: A neglected infectious burden. *Lancet Infect Dis.* 2004;4(9):566–74. doi:10.1016/S1473-3099(04)01131-4.
6. Magana M. Mycetoma. *Int J Dermatol.* 1984;23(4):221–36. doi:10.1111/j.1365-4362.1984.tb01238.x.
7. Lichon V, Khachemoune A. Mycetoma : a review. *Am J Clin Dermatol.* 2006;7(5):315–21. doi:10.2165/00128071-200607050-00005.
8. Goptu S, Ali I, Singh G, Mishra RN. Mycetoma foot. *J Family Community Med.* 2013;20(2):136–8. doi:10.4103/2230-8229.114775.
9. Davis JD, Stone PA, McGarry JJ. Recurrent mycetoma of the foot. *J Foot Ankle Surg.* 1999;38(1):55–60. doi:10.1016/s1067-2516(99)80089-1.
10. Alam K, Maheshwari V, Bhargava S, Jain A, Fatima U, Haq EU, et al. Histological diagnosis of madura foot (mycetoma): A must for definitive treatment. *J Glob Infect Dis.* 2009;1(1):64–7. doi:10.4103/0974-777X.52985.

Author biography

Jyoti Tomar, Assistant Professor

Neelima Goyal, Assistant Professor

Ketki Jangid, Assistant Professor

Cite this article: Tomar J, Goyal N, Jangid K. *Eumycetoma* infection of the hand: A case report. *IP Int J Med Microbiol Trop Dis* 2022;8(4):339-341.