

Content available at: <https://www.ipinnovative.com/open-access-journals>

IP International Journal of Medical Microbiology and Tropical Diseases

Journal homepage: <https://www.ijmmttd.org/>

## Case Report

# *Ochrobactrum anthropi*: An unusual opportunistic pathogen causing septicemia and Pneumonia

Vandana Sardana<sup>1</sup>, Sameer Rajeev Verma<sup>2,\*</sup><sup>1</sup>Dept. of Microbiology, Shri Ram Murti Smarak Institute of Medical Sciences, Bareilly, Uttar Pradesh, India<sup>2</sup>Dept. of Radiodiagnosis, Shri Ram Murti Smarak Institute of Medical Sciences, Bareilly, Uttar Pradesh, India

### ARTICLE INFO

#### Article history:

Received 29-08-2022

Accepted 05-11-2022

Available online 28-12-2022

#### Keywords:

Ochrobactrum anthropi

Indwelling catheters

Septicemia

Pneumonia

### ABSTRACT

*Ochrobactrum anthropi* is being increasingly recognized as an opportunistic human pathogen, causing severe infections mostly in debilitated or immunocompromised patients. It has been implicated in causing nosocomial infections, particularly in those with indwelling catheters, which can lead to catheter-related bloodstream infections. We report the constellation of clinical, microbiological and radiological findings of a case of septicemia and pneumonia caused by this unusual pathogen. Treatment of *Ochrobactrum anthropi* infection is challenging because of an unpredictable resistance to antibiotics. Correct identification and timely initiation of an appropriate antimicrobial therapy proves to result in the dramatic recovery of the patient.

This is an Open Access (OA) journal, and articles are distributed under the terms of the [Creative Commons Attribution-NonCommercial-ShareAlike 4.0 License](https://creativecommons.org/licenses/by-nc-sa/4.0/), which allows others to remix, tweak, and build upon the work non-commercially, as long as appropriate credit is given and the new creations are licensed under the identical terms.

For reprints contact: [reprint@ipinnovative.com](mailto:reprint@ipinnovative.com)

## 1. Introduction

*Ochrobactrum anthropi* formerly known as Achromobacter Centres for Disease Control and Prevention (CDC) group Vd, is an oxidase-positive, non-fermenting, Gram-negative bacillus.<sup>1,2</sup> The genus *Ochrobactrum* belongs to the family Brucellaceae.<sup>3</sup> The name *Ochrobactrum* is derived from the Greek ‘ochros’, meaning pale yellow; which is the characteristic colour of *Ochrobactrum* colonies. The genus *Ochrobactrum* comprises nine species, of which only three species, *O. anthropi*, *O. intermedium*, and *O. pseudintermedium*, have been reported to occur in clinical samples.<sup>4</sup> *Ochrobactrum anthropi* has been found in environmental and hospital water sources and has pathogenic potential in humans.<sup>1,4,5</sup> This aerobic organism has an ability to survive in antiseptic solution and to form biofilms, which may cause serious nosocomial infections.<sup>5</sup> Even though it is considered to have low virulence, *O. anthropi* has been described as an emerging pathogen,

causing severe infections in immunocompromised hosts, and in those with medical devices such as indwelling catheters and drainage tubes.<sup>2,5–7</sup> *O. anthropi* is often misidentified or missed out by conventional diagnostic techniques, which calls for the need of automated methods for the accurate identification and antimicrobial susceptibility testing of this unusual organism. We, hereby, report a case of *O. anthropi* causing septicemia and pneumonia in elderly patient who was a known case of diabetes mellitus type 2 and chronic kidney disease, and was on regular haemodialysis. The authors gives an insight of clinical manifestations, diagnosis, and treatment of infections caused by this unusual opportunistic pathogen.

## 2. Case Report

A seventy-year-old female, resident of western Uttar Pradesh, was brought to emergency with the history of fever since last 5 days, and shortness of breath since 2 days. She was admitted with central venous catheter in situ. As per patient’s previous medical records and as stated by her

\* Corresponding author.

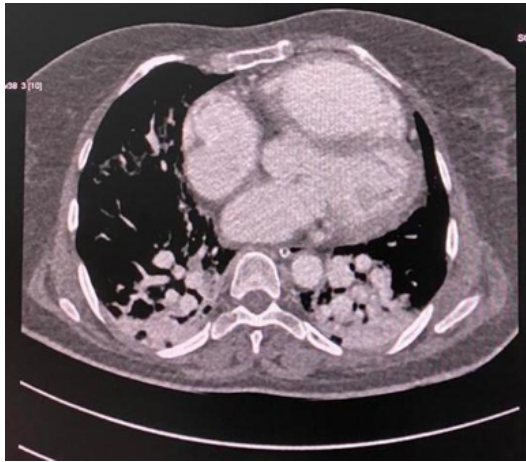E-mail address: [drvanverma@yahoo.in](mailto:drvanverma@yahoo.in) (S. R. Verma).

relatives, she was a known case of diabetes mellitus type 2 since last 20 years, taking medications irregularly. She was also diagnosed as a case of advanced chronic kidney disease about six months back. She had been on regular haemodialysis, two times per week, done via a Permcath inserted in the right internal jugular vein. The last dialysis was done one week back in another private hospital, as mentioned in her records. On physical examination, patient was disoriented and febrile, having temperature of 102<sup>o</sup>F. Her blood pressure was 104/60 mm Hg, pulse rate was 112/minute, and respiratory rate was 32 breaths/minute and oxygen saturation was 86%. On auscultation, bronchial breath sounds and crackles were heard in both the lung fields. Immediately, patient was shifted to intensive care unit and was put on ventilator support. Prior to administration of antibiotics, blood samples were collected for culture from two different sites, peripheral vein and permacath at the right internal jugular vein. Thereafter, intravenous cefpodoxime-clavulanic acid combination was started. Arterial blood gas analysis revealed pH 7.326, pCO<sub>2</sub> 34.6 mm Hg, pO<sub>2</sub> 74.2 mm Hg. Blood samples were also sent for hematological and biochemical analysis. Haematological investigations revealed leucocytosis (16200/mm<sup>3</sup>) with 79% neutrophils and 21% lymphocytes. Haemoglobin was 11.2 gm/dl, platelet count was 94000 cells/mm<sup>3</sup>, erythrocyte sedimentation rate was 36 mm/hour. C-reactive protein was 25.6 mg/dl. Procalcitonin level was 1.4 ng/ml. Renal function tests revealed serum creatinine 2.5 mg/dl, blood urea 60 mg/dl, sodium 132 mEq/l, potassium 4.2 mmol/l, chloride 103mmol/l and calcium 0.81mg/dl. Random blood sugar was 216 mg/dl. Liver function tests were within normal limits. Initial x-ray chest and subsequent Computed tomography (CT) scan of chest (Figure 1) showed bilateral lower lobar pneumonia. Ultrasound abdomen of the patient revealed bilateral small kidneys with raised parenchymal echogenicity and loss of corticomedullary differentiation suggestive of medical renal disease (Figure 2). Blood culture was done by an automated BACTEC System (BD) as per the manufacturer's instructions. After 18 hours of incubation, central line blood culture showed positive signal for microbial growth. The growth was identified by conventional methods such as Gram staining, colony characteristics, motility and the biochemical tests.<sup>6</sup> Gram staining done from the blood culture bottle showed Gram negative bacilli with no specific arrangement. Subculture was done on 5% sheep blood agar and MacConkey's agar. After 24 hours of aerobic incubation at 37<sup>o</sup>C, colonies on sheep blood agar were circular, about 1mm in diameter, mucoid, greyish in colour with slight tint of yellow, low convex and with entire edge (Figure 3), and MacConkey's agar showed non-lactose fermenting mucoid colonies (Figure 4). The isolate was motile, catalase positive and oxidase positive. It reduced nitrates to nitrites, utilized citrate, hydrolysed urea and was indole negative. It utilized

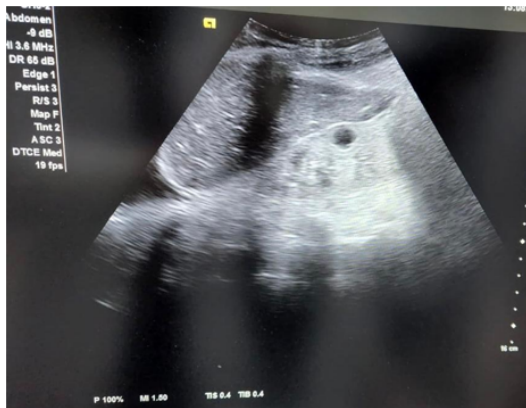glucose oxidatively on Hugh and Leifson's oxidation fermentation media. The isolate gave an alkaline slant by no change in the butt reaction on triple sugar iron agar. The above findings and characteristics of our isolate were pinpointing the growth of an unusual non-fermenter. So, the isolate was further identified by an automated VITEK 2 system (Biomérieux, France). Identification and drug susceptibility of the isolate were performed using VITEK 2 GN card and VITEK 2 AST-N281 card; respectively. The isolate was identified as *Ochrobactrum anthropi*. It was susceptible to ciprofloxacin, aminoglycosides, trimethoprim-sulfamethoxazole and carbapenems but was resistant to penicillin, ampicillin, cephalosporins, combination of beta lactam and beta lactamase inhibitor antibiotics, chloramphenicol, tetracycline and colistin. The peripheral line blood culture showed positive signal three hours later than the central line blood culture, suggesting a catheter-related bloodstream infection (CRBSI). The peripheral line blood culture also grew *O. anthropi* with similar antibiogram. The clinician was informed about the blood culture and the antibiotic sensitivity report on the fourth day following sample submission. The patient's fever and respiratory distress had not subsided by that time and the repeat x-ray of chest showed no improvement. Based on the sensitivity report, patient was started on intravenous ciprofloxacin and meropenem. The central venous catheter was removed. After 7 days of treatment with these antibiotics and removal of the catheter, the patient became afebrile and her respiratory distress improved. For follow-up, after one week of treatment, a fresh blood sample was drawn for culture, and this showed no growth at 37<sup>o</sup>C after 5 days of aerobic incubation. Follow-up x-ray of chest showed resolution of consolidation. Patient recovered and was extubated after 12 days of treatment. She was then shifted to ward. She was accepting orally and was able to maintain her oxygen saturation between 96-98%, without oxygen support. Finally, after two weeks patient was discharged with good general condition.

### 3. Discussion

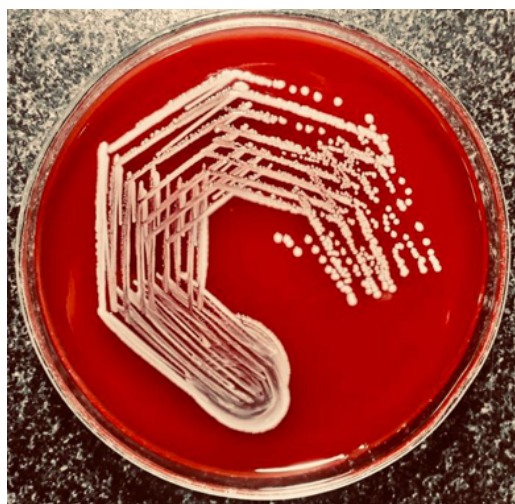*Ochrobactrum anthropi* is an aerobic, motile, urease positive, non-fermenting gram-negative bacillus with strict oxidative metabolism.<sup>1,6</sup> In recent years it has gained importance as an emergent pathogen in immunocompromised patients, especially in hospital settings, as it can survive within intravenous fluids and dialysis liquids.<sup>2,6,7</sup> It is ubiquitous in nature, belonging to the Brucellaceae family, within the Alphaproteobacteria class.<sup>7,8</sup> *O. anthropi* has been isolated from a number of environmental sources, and also recovered from various clinical samples, especially blood. It has been associated primarily with bacteremia and sepsis, especially in cases involving infected indwelling catheter lines.<sup>2,9-11</sup> Although initially believed to be an opportunistic pathogen causing



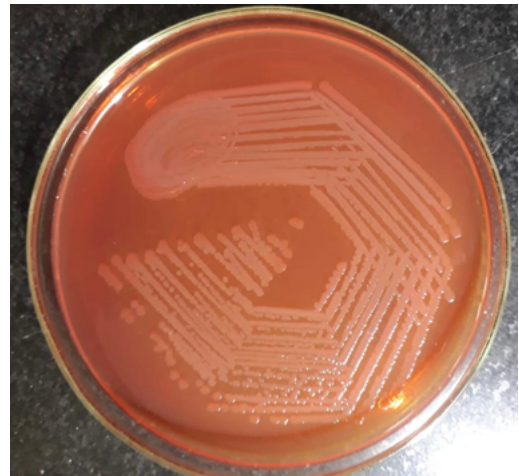
**Fig. 1:** Computed tomography (CT) scan of chest showing bilateral lower lobar consolidations with air bronchograms.



**Fig. 2:** Ultrasound image showing small right kidney with increased parenchymal echogenicity with complete loss of corticomedullary differentiation and small cortical cyst in mid portion



**Fig. 3:** Sheep blood agar showing greyish colonies with slight tint of yellow



**Fig. 4:** MacConkey's agar showing non-lactose fermenting mucoid colonies

infections in severely-ill or immunocompromised patients, especially the catheter-related blood stream infections, *O. anthropi* is increasingly being recognized as a pathogen in immunocompetent hosts which have been found to be associated with osteomyelitis, pelvic abscess, prosthetic valves, trauma, endophthalmitis, and usage of contaminated pharmaceuticals.<sup>2,10,11</sup> The predisposing factors such as prolonged antibiotic usage, steroid therapy, prior surgical procedure with allografts, accidental wound, and co-infection with other bacterium have been seen to be implicated with *O. anthropi* infections.<sup>2</sup> The correct identification of *O. anthropi* is a diagnostic challenge. It resembles the *Pseudomonas* species in that it has affinity for aquatic sources. It is generally mis-identified as *Pseudomonas* or *Brucella* by conventional culture methods.<sup>3,5</sup> Our case report highlights the role and importance of automated culture methods for the rapid and an accurate identification of this rare pathogen up to species level, so that it is not missed out in routine microbiological practice. *O. anthropi* poses a significant nosocomial threat, and has unique antibiotic susceptibility profile. Therefore, antimicrobial susceptibility testing done using automated system and alerting the treating clinician has resulted in saving the life of our patient. In our case, indwelling catheter lines had been the main underlying cause for septicaemia, as *O. anthropi* can adhere to catheters or other medical devices. Thus, breach in sterile clinical practices and instrumentation becomes the culprit for the nosocomial potential of *O. anthropi* causing blood stream infections. Our isolate was susceptible to ciprofloxacin, aminoglycosides, trimethoprim-sulfamethoxazole and carbapenems but was resistant to penicillin, ampicillin, cephalosporins, combination of beta lactam and beta lactamase inhibitor antibiotics, chloramphenicol, tetracycline and colistin. It

was found to be AmpC beta lactamase producers, similar to the observations made by other studies.<sup>3,5</sup> Acquired resistance of *O. anthropi* to colistin, which had been seen in our case, was also found in the studies done by Khan ID et al.<sup>5</sup> and Menuet M et al.<sup>12</sup> In 2016, Ashraf F<sup>9</sup> describes a case of *O. anthropi* - induced septic shock and infective endocarditis in a patient of end-stage renal disease, who was on haemodialysis, and also had a pacemaker for third degree heart block. Ashraf F<sup>9</sup> observed that his patient responded to intravenous meropenem, and on transoesophageal echocardiogram native mitral valve infective endocarditis was detected which got managed with antibiotic therapy for 6 weeks. Thus, patient with blood culture positive for *O. anthropi* should be screened for endocarditis, especially those who have any hardware in their heart such as prosthetic valves and pacemakers.<sup>9</sup> In 2013, Siti Rohani AH et al.<sup>13</sup> have also reported *O. anthropi* catheter-related bacteremia in a diabetic and hypertensive patient with end stage renal failure, who was on regular haemodialysis. *O. anthropi* isolated by Siti Rohani AH et al.<sup>13</sup> was found to be sensitive to imipenem, meropenem, cefepime, amikacin, gentamicin, ciprofloxacin and trimethoprim-sulfamethoxazole, and resistant to ceftazidime, piperacillin-tazobactam and polymyxin-B. Our case findings are similar to the observations made by Siti Rohani AH et al.<sup>13</sup> A study carried out by Daxboeck F et al.<sup>14</sup> reported bacteremia with *O. anthropi* in patient on haemodialysis, who had responded by removal of the dialysis catheter and a 3-week course of gentamicin. Chertow GM has also reported catheter-related blood stream infection due to *O. anthropi* in a haemodialysis patient.<sup>15</sup> Given the organism's hydrophilic property and the usage of indwelling catheters in debilitated patients with renal failure, *O. anthropi* infection should be considered in the differential diagnosis of a haemodialysis patient with unexplained fever.<sup>15</sup> A study carried out in Amritsar by Arora U et al.<sup>16</sup> have reported a case of *O. anthropi* septicemia in an elderly male patient with a history of hypertension, diabetes and coronary artery disease with severe left ventricular dysfunction, who had undergone intraaortic balloon pump insertion, following which the patient developed a haematoma at the local site, which had led to blood stream infection. Catheter-related blood stream infection (CRBSI) due to *O. anthropi* have been documented by Kern WV et al.<sup>17</sup> in patients of acute leukemia as the underlying disease. The Infectious Diseases Society of America (IDSA) Clinical Practice Guidelines for the Diagnosis and Management of Intravascular Catheter-Related Infection<sup>18</sup> states that "A definitive diagnosis of catheter-related blood stream infection requires that the same organism grow from at least one percutaneous blood culture and from a culture of the catheter tip, or that two blood samples be drawn (one from a catheter hub and the other from a peripheral vein) that, when

cultured, meet CRBSI criteria for quantitative blood cultures or differential time to positivity." In 2013, a study done in New Delhi by Kumar S et al.<sup>19</sup> reported a case of *O. anthropi* septicemia and pneumonia in a preterm infant with congenital anomalies, who had responded well and recovered with meropenem administered for seven days. In our case also, after treatment with intravenous meropenem and ciprofloxacin patient became afebrile, follow-up blood culture was sterile and the follow up chest X-ray showed resolution of consolidation. In 2013, Naik C et al.<sup>2</sup> documented a case of septic shock and respiratory failure from pneumonia secondary to *O. anthropi* infection, who had recovered with intravenous ciprofloxacin. Cieslak TJ et al.<sup>20</sup> had reported a case of pneumonia due to *O. anthropi* in a patient with underlying lung carcinoma, where this rare pathogen was isolated on culture from the purulent discharge from the draining chest tube, and the patient had responded well to trimethoprim-sulfamethoxazole administered via gastrostomy tube. The various authors across the world has reported *O. anthropi* blood stream infections in immunocompromised patients.<sup>5,13,15-17,19-21</sup> However, in 2017, Rastogi N et al.<sup>22</sup> observed catheter-related septicemia with meningitis due to *O. anthropi*, in an elderly immunocompetent male with a head trauma. Kettaneh A et al.<sup>23</sup> documented a case of septic shock that occurred in an otherwise healthy host after administration of a peripheral venous infusion of a solution contaminated with *O. anthropi*. Our case report alerts the emergence of *O. anthropi* as an opportunistic pathogen in an immunocompromised patient. Severe immunosuppression and association with an indwelling catheter appears to be the major factors favouring the *O. anthropi* septicemia. Treatment of *O. anthropi* infection is challenging because of widespread and unpredictable resistance to antimicrobial agents. Timely initiation of appropriate antibiotic therapy and removal of catheter played a key role to favourable clinical outcome in our case.

#### 4. Conclusion

The authors stress upon the importance of rapid identification and susceptibility testing of *Ochrobactrum anthropi*, as this unusual and unconventional organism appears to be an emerging opportunistic and nosocomial pathogen associated with the implantation of intravenous catheters or other medical devices in immunosuppressed or debilitated patients. This case also highlights the importance of prompt communication between microbiologists and clinicians in managing the infection, in view of *O. anthropi* unique antibiotic susceptibility profiles. Implementation of effective methods of sterilization and strict adherence to infection prevention and control practices becomes essential to prevent the spread of this organism.

## 5. Source of Funding

None.


## 6. Conflict of Interest

None.

## References

1. Winn W, Allen S, Janda W, Koneman E, Procop G, Schreckenberger P. Infection: the first case report in Malaysia. *Koneman's Color Atlas and Textbook of Diagnostic Microbiology 6th edition Philadelphia: Lippincott Williams & Wilkins*. 2006;68.
2. Yu WL, Lin CW, Wang DY. Clinical and microbiologic characteristics of *Ochrobactrum anthropi* bacteremia. *J Formos Med Assoc*. 1998;97(2):106–118.
3. Hagiya H, Ohnishi K, Maki M, Watanabe N, Murase T. Clinical characteristics of *Ochrobactrum anthropi* bacteremia. *J Clin Microbiol*. 2013;51(4):1330–1333.
4. Jelveh N, Cunha BA. *Ochrobactrum anthropi* bacteremia. *Heart Lung*. 1999;28(2):145–151.
5. Khan ID, Mukherjee T, Gupta S, Haleem S, Sahni AK, Banerjee S, et al. *Ochrobactrum anthropi* sepsis in Intensive Tertiary Care. *J of basic and Clin Med*. 2014;3(1):18–20.
6. Patricia MT. *Bailey and Scott's Diagnostic Microbiology*. St. Louis, Missouri: Elsevier; 2014.
7. Chain PS, Lang DM, Comerchi DJ, Malfatti SA, Vergez LM, Shin M, et al. Genome of *Ochrobactrum anthropi* ATCC 49188 T, a versatile opportunistic pathogen and symbiont of several eukaryotic hosts. *J Bacteriol*. 2011;193(16):4274–4279.
8. Bruckner C. Nomenclature for aerobic and facultative bacteria. *Clin Infect Dis*. 1993;16(5):598–605.
9. Ashraf F. A case of *Ochrobactrum anthropi*-induced septic shock and infective endocarditis. *R I Med J*. 2016;99(7):27–35.
10. Vaidya SA, Citron DM, Fine MB, Murakami G, Goldstein E. Pelvic abscess due to *Ochrobactrum anthropi* in an immunocompetent host: case report and review of the literature. *J Clin Microbiol*. 2006;44(3):1184–1190.
11. Javadi R, Cubbon M. *Ochrobactrum anthropi* bacteremia in a non-diabetic, immunocompetent hemodialysis patient. *Dialysis & Transplantation*. 2008;37(11):452–453.
12. Menuet M, Bittar F, Stremler N, Dubus JC, Sarles J, Raoult D. First isolation of two colistin-resistant emerging pathogens, *Brevundimonas diminuta* and *Ochrobactrum anthropi*, in a woman with cystic fibrosis: a case report. *J Med Case Rep*. 2008;2:373–373.
13. Rohani AHS, Tzar MN.
14. Daxboeck F, Zitta S, Assadian O, Krause R, Wenisch C, Kovarik J. *Ochrobactrum anthropi* bloodstream infection complicating hemodialysis. *Am J Kidney Dis*. 2002;40(4):17–17.
15. Chertow GM. *Ochrobactrum anthropi* bacteremia in a patient on hemodialysis. *Am J Kidney Dis*. 2000;35:30–30.
16. Arora U, Kaur S, Devi P. *Ochrobactrum anthropi* septicaemia. *Indian J Med Microbiol*. 2008;26:81–84.
17. Kern WV, Oethinger M, Kaufhold A, Rozdzinski E, Marre R. *Ochrobactrum anthropi* bacteremia: Report of four cases and short review. *Infection*. 1993;21:306–316.
18. Mermel MA, Allon M, Bouza E, Craven DE, Flynn P, Grady O, et al. Clinical practice guidelines for the diagnosis and management of intravascular catheter-related infection: 2009 Update by the Infectious Diseases Society of America. *Clin Infect Dis*. 2009;49(1):1–45.
19. Kumar S, Kapoor S, Chadha S, Saigal SR. *Ochrobactrum anthropi* septicemia and pneumonia in a preterm, small for gestational age infant with multiple congenital anomalies. *Indian J Pathol Microbiol*. 2013;56(3):317–325.
20. Cieslak TJ, Drabick CJ, Robb ML. Pyogenic infections due to *Ochrobactrum anthropi*. *Clin Infect Dis*. 1996;22(5):845–852.
21. Naik C, Kulkarni H, Darabi A, Bhanot N. *Ochrobactrum anthropi*: a rare cause of pneumonia. *J Infect Chemother*. 2013;19(1):162–167.
22. Rastogi N, Mathur P. *Ochrobactrum anthropi*: An emerging pathogen causing meningitis with sepsis in a neurotrauma patient. *J Infect Dev Ctries*. 2017;11(9):733–768.
23. Kettaneh A, Weill FX, Poilane I, Fain O, Thomas M, Herrmann JL, et al. Septic shock caused by *Ochrobactrum anthropi* in an otherwise healthy host. *J Clin Microbiol*. 2003;41(3):1339–1380.

## Author biography

**Vandana Sardana**, Professor  <https://orcid.org/0000-0003-4688-7148>

**Sameer Rajeev Verma**, Professor  <https://orcid.org/0000-0003-3007-9728>

**Cite this article:** Sardana V, Verma SR. *Ochrobactrum anthropi*: An unusual opportunistic pathogen causing septicemia and Pneumonia. *IP Int J Med Microbiol Trop Dis* 2022;8(4):345-349.