

Content available at: <https://www.ipinnovative.com/open-access-journals>

IP International Journal of Medical Microbiology and Tropical Diseases

Journal homepage: <https://www.ijmmt.org/>

## Case Report

# *Streptococcus pseudoporcinus* bacteremia in a Type II-respiratory failure patient with coronary artery disease: A case report

Ashwin Venu<sup>1</sup>, Jagadish K.L<sup>2</sup>, Sandhya Bhat<sup>1,\*</sup><sup>1</sup>Dept. of Microbiology, Pondicherry Institute of Medical Sciences, Pondicherry University, Kalapet, Pondicherry, India<sup>2</sup>Dept. of General Medicine, Pondicherry Institute of Medical Sciences, Pondicherry University, Kalapet, Pondicherry, India

### ARTICLE INFO

#### Article history:

Received 25-03-2023

Accepted 30-03-2023

Available online 19-04-2023

#### Keywords:

Bacteremia

*Streptococcus pseudoporcinus*

Beta-hemolytic streptococci

Respiratory failure

### ABSTRACT

*Streptococcus pseudoporcinus* is a beta-hemolytic Gram-positive, catalase-negative, nonmotile coccus arranged in short chains, usually found in the female genitourinary tract. Only a few human infections associated with this organism have been reported till date. *Streptococcus pseudoporcinus* is usually found as colonizer of female genital tract, has been rarely associated with bacteremia. We are reporting a rare case of *Streptococcus pseudoporcinus* causing bacteremia in patients with respiratory failure and coronary artery disease, who was treated with clindamycin and piperacillin/tazobactam. This case report illustrates the potential of these bacteria to cause severe invasive and life-threatening disease.

This is an Open Access (OA) journal, and articles are distributed under the terms of the [Creative Commons Attribution-NonCommercial-ShareAlike 4.0 License](https://creativecommons.org/licenses/by-nc-sa/4.0/), which allows others to remix, tweak, and build upon the work non-commercially, as long as appropriate credit is given and the new creations are licensed under the identical terms.

For reprints contact: [reprint@ipinnovative.com](mailto:reprint@ipinnovative.com)

## 1. Introduction

*Streptococcus pseudoporcinus* is a beta-hemolytic coccus arranged in short chains, usually found in the female genitourinary tract. The bacterium was first isolated from the female genito-urinary tract in the year 2006. It is usually recovered from the female genital tract as a colonizer.<sup>1</sup> Currently little is known about epidemiology of this organism or its role as a human pathogen; except for few case reports of causing obstetric disorders such as chorioamnionitis and preterm delivery, skin infections such as cellulitis. Recently invasive infection such as bacteremia was reported from a patient having syphilis and HIV co-infection.<sup>2,3</sup> Here, we report a case of *Streptococcus pseudoporcinus* bacteremia in a patient having coronary artery disease with type-2 respiratory failure.

## 2. Case History

A 50-year-old female patient came to the emergency department with complaints of severe breathlessness since one day and pedal edema, generalised malaise, decreased urine output, abdominal distension with on and off a fever for 3 days. She was referred to our tertiary care centre in intubated state for cardiogenic shock. She was on central line (day 2), peripheral line on right hand with 20 gauge venflon (day 2), urinary catheter (day 2) and on oropharyngeal tube (day 2). She was a known case of type-2 diabetes mellitus and systemic hypertension for 12 years and is on medication for the same. She has a h/o left ventricular dysfunction with ejection fraction of 49% with normal coronaries on angiogram done four years back.

On physical examination, she was drowsy but arousable and morbidly obese. Her Glasgow Coma Scale (GCS) was E3 VT M6, temperature was 101°F, pulse 120 beats per minute, respiration rate was 20 per minute, blood pressure 150/80 mmHg (with noradrenaline 0.3 µg/min) and SPO<sub>2</sub> was 100% with mechanical ventilation. On auscultation,

\* Corresponding author.

E-mail address: [sandhyabhatk@gmail.com](mailto:sandhyabhatk@gmail.com) (S. Bhat).

bilateral air entry was equal, bilateral extensive crepitations were present. Her blood sample was sent for routine hematological investigations. The diagnostic test results are displayed in Table 1.

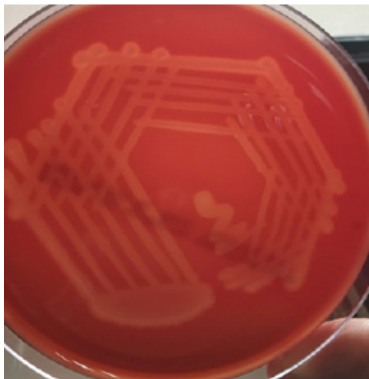

Fig. 1: Growth of *streptococcus pseudoporcinus* on blood agar.

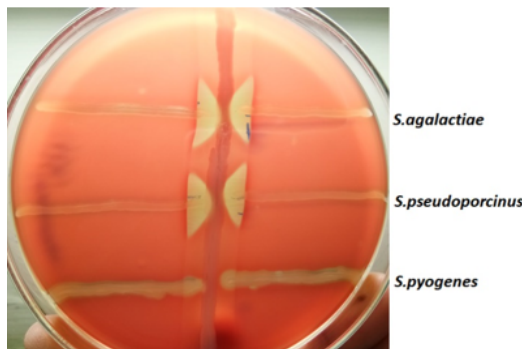


Fig. 2: *Streptococcus pseudoporcinus* showing CAMP positive on blood agar

Patient was started on Inj. Piptaz (4.5 gm Q6H IV), as a part of empirical therapy. Paired blood culture samples were sent. Her both the blood culture samples showed growth of small 0.5–1 mm in diameter, white circular colonies with a wide zone of β-hemolysis on blood agar after 24 hour of incubation (Figure 1). The isolate was catalase positive, bacitracin resistant, CAMP (Christie–Atkins–Munch–Peterson) test positive (Figure 2) and bile esculin hydrolysis negative. The isolate was identified to be *Streptococcus pseudoporcinus* by the VITEK2 Compact system (bioMérieux). The isolate was sensitive to penicillin, cefotaxime, clindamycin, erythromycin, vancomycin, linezolid, cotrimoxazole and ciprofloxacin tested by Kirby Bauer’s disk diffusion testing on Mueller Hinton blood agar (MHBA). Based on the antimicrobial susceptibility report patient was started on Inj. clindamycin (60 mg IV, TDS for 3 days) immediately.

1. Chest X-ray showed bilateral infiltrates. Troponin-1 was positive. He was started on dual anti-platelets and

heparin. 2D ECHO revealed Dilated cardiomyopathy with severe LV Dysfunction (30%). Patient was also started on T.Aspirin 75 mg OD, T.Clopilet 75 mg OD, T.Atorva 20 mg HS, T.Lasilactone OD, T.Ramipril 2.5 mg OD to manage his other underlying co-morbid conditions.

2. Patient symptomatically improved and was gradually tapered on inotropic support and weaned off from ventilator and continued on BIPAP support. Patient was advised on further stay for BIPAP support for further management, however in spite of explaining possible complications, was discharged against medical advice.

### 3. Discussion

We present a case of severe invasive infection due to *Streptococcus pseudoporcinus*. This patient presented with fever and underlying type-2 respiratory failure with coronary artery syndrome. His paired blood culture specimens yielded *S. pseudoporcinus*; definitive source of this isolate is unclear. *S. pseudoporcinus* usually colonizes gastrointestinal and genitourinary tracts.<sup>1,3</sup> In this case it may be a colonizer from her gastrointestinal tract, which would have ultimately led to her clinical disease via aspiration.

*Streptococcus pseudoporcinus* is a beta-hemolytic gram-positive, catalase-negative, nonmotile coccus arranged in short chains and can sometimes be confused with *Streptococcus agalactiae* (group B Streptococcus) because of its recovery from vaginal-rectal specimens, similar colony morphology and biochemical reactions, and frequent cross reactivity with Lancefield group B reagents.<sup>5,6</sup> In contrast to *S. agalactiae*, which displays a narrow zone of beta-hemolysis, *S. pseudoporcinus* exhibits a large zone. Additionally, *S. agalactiae* is esculin hydrolysis negative and hippurate hydrolysis positive and while the opposite is true for *S. pseudoporcinus*.<sup>2,7</sup> In our case, definite bacterial isolate identification was made using the VITEK2 compact system, which is a reliable automated tool for species identification of this streptococci.

Identification by conventional biochemical tests may be at times difficult. Unavailability of automated identification system, can make differentiation between *S. pseudoporcinus* and *S. agalactiae* difficult and has probably led to an underestimation of the former’s role and frequency in human colonization and disease.

Stoner et al. reported that 5.4% of women had genital cultures that were positive for *S.pseudoporcinus*, which suggests that the colonization of *S. pseudoporcinus* in healthy individuals is not rare.<sup>8</sup> Though little is known about the pathogenicity of *S. pseudoporcinus* in human disease, the literature suggests the possibility of adverse obstetric outcomes. It has been associated with chorioamnionitis and preterm delivery.

**Table 1:** Reports of various laboratory parameters

S. No.	Laboratory test performed	Result/ Value	Interpretation
1.	Random Blood Glucose	256mg/dl	Elevated
2.	D-Dimer [quantitative]	3.81mg/l	Elevated
3.	Blood Uric acid	8.0mg/dl	Elevated
4.	CRP	24mg/l	Elevated
5.	HbA1C	11.3%	Elevated
6.	Serum Potassium	5.4meq/l	Mildly elevated
7.	Serum Phosphorus	5.3mg/dl	Elevated
8.	Lipid profiles	-	Normal
9.	Peripheral smear study	Normocytic normochromic leukocytosis	blood picture with neutrophilic leukocytosis
10.	HBsAg [by chemiluminescence immunoassay]	-	Non-reactive
11.	HCV antibody	-	Non-reactive
12.	HIV Ab/Ag	-	Non-reactive
13.	Urine protein levels	Granular cast seen [8-10] <sup>4</sup> /LPF	Elevated
14.	Nasopharyngeal swab for SARS COV2 RNA by RT-PCR	-	Negative
15.	Urine C/S	-	No growth in culture
16.	Endotracheal aspirate C/S	-	Normal respiratory flora grown

Few case reports are available in the literature regarding its association with human infections including genitourinary infection, a wound infection of a finger as a result of trauma, another with left lower leg cellulitis, causing endocarditis and a case report with pneumonia and empyema. Although the clinical significance of *S. pseudoporcinus* has not been completely established, it is important to report the identification when we recover the organism from bacterial cultures.<sup>1-5</sup>

Previous studies reported that *S. pseudoporcinus* is highly susceptible to  $\beta$ -lactam antibiotics. And some isolates are resistant to erythromycin, clindamycin and tetracycline.<sup>3,6</sup> However, this isolate was uniformly susceptible to all tested antimicrobial agents.

#### 4. Conclusion

In conclusion, the increase in the number of isolates identified as *S. pseudoporcinus* is most likely related to improvements in identification methods and greater awareness of this organism rather than its recent emergence in the human population. Controlled studies in which microbiologic testing is performed to distinguish between *S. agalactiae* and *S. pseudoporcinus* are needed in order to determine if the latter is consistently identified as the true causative agent in various clinical conditions including invasive infections such as bacteremia.

As it is usually susceptible to many anti-streptococcal antimicrobial agents, inaccurate identification does not lead to treatment failure; however, we should keep in mind that *S. pseudoporcinus* could emerge as a serious medical problem in the near future, as with other  $\beta$ -hemolytic streptococci.

#### 5. Source of Funding

None.

#### 6. Conflicts of interest

There are no conflicts of interest.

#### References

1. Bekal S, Gaudreau C, Laurence RA, Simoneau E, Raynal L. Streptococcus pseudoporcinus sp. nov., a novel species isolated from the genitourinary tract of women. *J Clin Microbiol.* 2006;44(7):2584–6.
2. Sawamura S, Niimori D, Ihn H. A case of leg cellulitis caused by multidrug-resistant Streptococcus pseudoporcinus. *Intractable Rare Dis Res.* 2018;7(4):280–2.
3. Khan S, Wong TT, Prasad N, Lee B, Urban C, Segal-Maurer S, et al. Streptococcus pseudoporcinus: Case Reports and Review of the Literature. *Case Rep Infect Dis.* 2020;p. 4135246. doi:10.1155/2020/4135246.
4. Mahlen SD, Clarridge JE. Thumb infection caused by Streptococcus pseudoporcinus. *J Clin Microbiol.* 2009;47(9):3041–2.
5. Suwantarat N, Grundy M, Rubin M, Harris R, Miller JA, Romagnoli M, et al. Recognition of streptococcus pseudoporcinus colonization in women as a consequence of using matrix-assisted laser desorption ionization-time of flight mass spectrometry for Group B streptococcus identification. *J Clin Microbiol.* 2015;53(12):3926–30.
6. Gaudreau C, Simoneau E, Labrecque O, Laurence RA, Laferrière C, Miller M, et al. Epidemiological, biochemical and antimicrobial susceptibility characteristics of Streptococcus pseudoporcinus isolated in Quebec, Canada, from 1997 to. *J Med Microbiol.* 2006;56(12):1620–4.
7. Gullett JC, Westblade LF, Green DA, Whittier S, Burd EM. The brief case: Too beta to be a “B”. *J Clin Microbiol.* 2017;55(6):1604–7.
8. Stoner KA, Rabe LK, Austin MN, Meyn LA, Hillier SL. Incidence and Epidemiology of Streptococcus pseudoporcinus in the Genital Tract. *J Clin Microbiol.* 2011;49(3):883–6. doi:10.1128/JCM.01965-10.

## Author biography

**Ashwin Venu**, Final Year Post Graduate

**Jagadish K.L.**, Senior Resident

**Sandhya Bhat**, Professor  <https://orcid.org/0000-0002-4257-9220>

**Cite this article:** Venu A, Jagadish K.L, Bhat S. *Streptococcus pseudoporcinus* bacteremia in a Type II-respiratory failure patient with coronary artery disease: A case report. *IP Int J Med Microbiol Trop Dis* 2023;9(1):70-73.