

Content available at: <https://www.ipinnovative.com/open-access-journals>

IP International Journal of Medical Microbiology and Tropical Diseases

Journal homepage: <https://www.ijmmt.org/>

Case Report

Pulmonary aspergillosis caused by *Aspergillus terreus*: An ICU case report

Pranshu Pandey¹, Harshita Yadav¹, Kriti Maurya², Vikramjeet Singh¹,
Anupam Das^{1,*}, Manodeep Sen¹, Jyotsna Agarwal¹

¹Dept. of Microbiology, Dr. Ram Manohar Lohia Institute of Medical Sciences, Lucknow, Uttar Pradesh, India

²Dept. of Microbiology, All India Institute of Medical Sciences, Jodhpur, Rajasthan, India



ARTICLE INFO

Article history:

Received 15-02-2022

Accepted 30-03-2022

Available online 19-04-2023

Keywords:

Aspergillus terreus

Voriconazole

ABPA

Antifungal intrinsic resistance

ABSTRACT

Aspergillosis can be a severe cause of mortality specially in immunocompromised patients. The range of infection due to *Aspergillus spp.* extends from cutaneous to invasive infections. Other than the commonly encountered *Aspergillus fumigatus*, other species of *Aspergillus* like *Aspergillus terreus* is emerging now. The importance of identifying these newly emerging fungus *Aspergillus terreus* lies in the fact that these organisms are intrinsically resistant to polyenes, Hence, considering the same line of treatment for *A. terreus* as *A. fumigatus* will lead to therapeutic failure. The case report under mentioned highlights the importance of identifying *Aspergillus* to species level.

This is an Open Access (OA) journal, and articles are distributed under the terms of the [Creative Commons Attribution-NonCommercial-ShareAlike 4.0 License](#), which allows others to remix, tweak, and build upon the work non-commercially, as long as appropriate credit is given and the new creations are licensed under the identical terms.

For reprints contact: reprint@ipinnovative.com

1. Introduction

Pulmonary aspergillosis remains a significant cause of morbidity and mortality in immunocompromised patients.¹ Timely and accurate diagnosis is essential but remains challenging because of non-specific clinical and radiological findings. An important impediment for timely diagnosis is the low yield of positive cultures from respiratory specimens. Furthermore, the positive cultures may not always be indicative of *Aspergillus* infection. Among the newly delineated species of *Aspergillus*, *A. terreus* is associated with severe life-threatening infections.² We report a case of pulmonary aspergillosis due to *A. terreus* in a patient of chronic obstructive pulmonary disease.

2. Case Report

A 68-year-old diabetic and hypertensive female with chronic obstructive pulmonary disease was admitted in Intensive care unit with chief complaints of breathlessness and high grade fever. On diagnostic evaluation patient had high TLC (15,000/cu.mm) & deranged pulmonary function tests. On repeated endotracheal aspiration for bacterial culture sensitivity, polymicrobial microorganisms isolated. The bacterial isolates (*Pseudomonas aeruginosa*, *Klebsiella pneumoniae*, etc) were sensitive to carbapenem group of drugs and colistin. However, there was no improvement in patient's condition. She was then prepared for collection of bronchoalveolar lavage. Thereafter, three BAL samples at an interval of 3 days were sent for evaluation of fungal etiology. After 5-7 days of aerobic incubation at 37°C on Sabouraud dextrose agar (SDA), there was significant growth of mold. On the obverse mycelium growth was white to pale yellow, dense and in tufts. Conidia tan to light brown with a powdery texture which turned the media bright yellow (Figure 1a). Reverse was reddish brown

* Corresponding author.

E-mail address: dasdranupam@gmail.com (A. Das).

in appearance. The Lacto Phenol Cotton Blue (LPCB) mount was prepared which showed compact, columnar and biseriolate conidial head of size approximately 30 to 50 μm in diameter. Conidiophores were hyaline and smooth walled; conidia were globose shaped, smooth walled and 1.5 to 2.5 μm in diameter (Figure 1b). There was presence of similar growth on 2nd and 3rd bronchoalveolar lavage samples from the patient. Patient was initially managed on the clinical suspicion of pulmonary mycosis using Amphotericin B but as soon clinicians were informed about *A. terreus* infection and its inherent resistance to Amphotericin B, the antifungal treatment was changed to Voriconazole 200mg BD for 3 weeks. Other supportive measures were continued with antimicrobials coverage. Repeat BAL culture after 3 weeks of voriconazole treatment was negative for aspergillosis. Gradually improvement in patient's condition was observed and she was discharged without any adverse events.

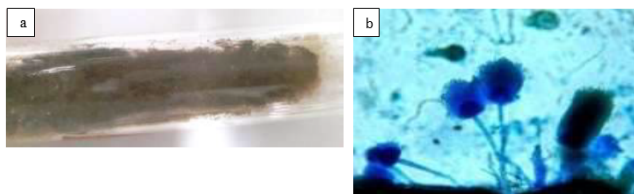


Fig. 1: a,b: Macroscopic and microscopic pictures of *Aspergillus terreus*

3. Discussion

The spores of *Aspergillus* species are present ubiquitously in environment, and the risk of spread of infection is influenced by living conditions like precipitation patterns, humidity, temperature, and wind conditions.¹ The patients' immune status plays a major role in contracting infection due to *Aspergillus* species. *Aspergillus spp* cause diseases like allergic bronchial pulmonary Aspergillosis (ABPA), aspergilloma, chronic necrotizing Aspergillus pneumonia, and invasive diseases.³ *Aspergillus terreus* complex belong to section *Terrei* in which *Aspergillus terreus sensu stricto* is the most commonly isolated species with other species in the complex *A. alabamensis*, *A. allahabadii*, *A. ambiguus*, *A. aureoterreus*, *A. bicephalus*, *A. carneus*, *A. citrinoterreus*, *A. floccosus*, *A. iranicus*, *A. hortai*, *A. microcysticus*, *A. neoafrikanus*, *A. neoindicus*, *A. niveus*, and *A. pseudoterreus*.³ There have been reports of *Aspergillus terreus* causing invasive infections like fungal peritonitis, fungal spondylodiscitis, fungal sinusitis as well as cutaneous fungal infections.^{4,5} The case presented here also was immunosuppressed due to her diabetic as well as hypertensive state. There was no improvement in patients' status instead of getting treatment for bacterial growth in bronchoalveolar lavage which indicated that there was some other underlying cause which ultimately grew as *Aspergillus*

terreus on fungal culture. Keeping the differential diagnosis of fungal etiology in such immunosuppressed patients would help in better treatment of patients presenting with such symptoms.

Triazoles like voriconazole, isavuconazole and lipid formulation of Amphotericin B are the mainstay of *Aspergillus* treatment but *Aspergillus terreus* are found to be resistant to polyenes hence in case of Amphotericin B being treatment option, the speciation of *Aspergillus* is necessary so the wrong treatment could be avoided.^{6,7} In vitro susceptibility testing may be a predictor of clinical outcome of invasive aspergillosis, although this has not yet been firmly established; this would be particularly important for infections with *A. terreus*, given its resistance to amphotericin B. The patient in our case also improved when the Amphotericin B was switched with Voriconazole thus indicating the importance of proper identification of invasive molds till species level.

4. Conclusion

In this case initial treatment with antifungals showed remarkable improvement, which was due to early diagnosis. Isolation of *Aspergillus terreus* from multiple sets of BAL culture proves the pathogenic nature of the isolate and should never be neglected.

5. Source of Funding

None.

6. Conflicts of interest

There are no conflicts of interest.


References

1. Russo A, Tiseo G, Falcone M, Menichetti F. Pulmonary Aspergillosis: An Evolving Challenge for Diagnosis and Treatment. *Infect Dis Ther*. 2020;9(3):511–24. doi:10.1007/s40121-020-00315-4.
2. Cooke FJ, Terpos E, Boyle J, Rahemtulla A, Rogers TR. Disseminated Aspergillus terreus infection arising from cutaneous inoculation treated with caspofungin. *Clin Microbiol Infect*. 2003;9(12):1238–41. doi:10.1111/j.1469-0691.2003.00797.x.
3. Lass-Flörl C, Dietl AM, Kontoyannis DP, Brock M. *Aspergillus terreus* Species Complex. *Clin Microbiol Rev*. 2021;34(4):e0031120. doi:10.1128/CMR.00311-20.
4. Thayanidhi P, Subramanian A, & kindo AJ. *Aspergillus terreus* : An emerging pathogen: A case series. *J Acad Clin Microbiol*. 2014;16(2):96–9.
5. Takagi Y, Yamada H, Ebara H, Hayashi H, Kidani S, Okamoto S, et al. Aspergillus terreus spondylodiscitis following an abdominal stab wound: a case report. *J Med Case Rep*. 2019;13(1):1–6.
6. Ullmann AJ, Aguado JM, Arikan-Akdagli S, Denning DW, Groll AH, Lagrou K, et al. Diagnosis and management of Aspergillus diseases: executive summary of the 2017 ESCMID-ECMM-ERS guideline. *Clin Microbiol Infect*. 2018;24(1):e1–e24. doi:10.1016/j.cmi.2018.01.002.
7. Lass-Flörl C. Treatment of infections due to Aspergillus terreus species complex. *J Fungi*. 2018;4(3):83. doi:10.3390/jof4030083.

Author biography

Pranshu Pandey, Senior Resident  <https://orcid.org/0000-0003-1460-3729>

Harshita Yadav, Junior Resident  <https://orcid.org/0009-0004-1355-3701>

Kriti Maurya, Senior Resident  <https://orcid.org/0000-0003-0230-3147>

Vikramjeet Singh, Assistant Professor

Anupam Das, Additional Professor  <https://orcid.org/0000-0002-1850-5969>

Manodeep Sen, Professor  <https://orcid.org/0000-0003-3081-9212>

Jyotsna Agarwal, Professor & Head  <https://orcid.org/0000-0003-0568-7959>

Cite this article: Pandey P, Yadav H, Maurya K, Singh V, Das A, Sen M, Agarwal J. Pulmonary aspergillosis caused by *Aspergillus terreus*: An ICU case report. *IP Int J Med Microbiol Trop Dis* 2023;9(1):74-76.