

Content available at: <https://www.ipinnovative.com/open-access-journals>

IP International Journal of Medical Microbiology and Tropical Diseases

Journal homepage: <https://www.ijmmt.org/>

Case Report

Empyema and haemothorax due to ruptured pulmonary hydatid cyst- A rare presentation

Mayur Tadvil¹, Anant Prabhakar Marathe^{1,*}, Vaidehi J Mehta¹

¹Dept. of Microbiology, Parul Institute of Medical Sciences and Research, Waghodia, Gujarat, India



ARTICLE INFO

Article history:

Received 01-05-2023

Accepted 22-06-2023

Available online 18-07-2023

Keywords:

Hydatid cyst

Empyema

ABSTRACT

Hydatidosis is a parasitic infection caused by *Echinococcus granulosus* (Dog Tape-worm). India is endemic for hydatid disease. The lung is the second most frequently affected organ by hydatid cysts after the liver. Hydatid cysts are mostly seen in the right lower lobe of the lung. We report an unusual presentation of ruptured pulmonary hydatid cyst as empyema and haemothorax in a 24-year-old boy who presented with dyspnoea on exertion with right-sided chest pain. Pleural fluid was suggestive of empyema. The pleural fluid examination revealed plenty of neutrophils and the presence of hooklets of hydatid cyst. Ruptured hydatid cyst is clinically and radiologically confused with many diseases, especially lung cancer. Surgical removal of hydatid cyst is accepted as primary treatment. Thoracotomy was done to excise hydatid cyst. Albendazole was given post-surgery. The patient was discharged on postoperative day 6th with good respiratory capacity. During two months follow up the patient remained asymptomatic.

This is an Open Access (OA) journal, and articles are distributed under the terms of the [Creative Commons Attribution-NonCommercial-ShareAlike 4.0 License](https://creativecommons.org/licenses/by-nc-sa/4.0/), which allows others to remix, tweak, and build upon the work non-commercially, as long as appropriate credit is given and the new creations are licensed under the identical terms.

For reprints contact: reprint@ipinnovative.com

1. Introduction

Hydatid disease, which is caused by the tape-worm *Echinococcus granulosus* or *Echinococcus multi-locularis*, is known as echinococcosis or hydatidosis.¹ Echinococcosis is endemic to the Mediterranean region, South America, Australia, New Zealand, the Middle East, Alaska, and Canada, where it is widespread among Indian tribes.² Liver is the most common location of the cyst while lungs are the second most common organ involved in this disease.³ Surgical removal of hydatid cyst is considered as the best treatment. In case of ruptured hydatid cyst, surgical removal is followed by treatment Albendazole treatment for long time is necessary to prevent seeding of protoscoleces, escaped from ruptured cysts, in the body and further dissemination of the disease.⁴

2. Case History

A 24-year-old boy presented to the OPD clinic of PSH with complaints of Dyspnoea over exertion and right-sided chest pain. The patient had been treated at another clinic before visiting our OPD. The patient was hemodynamically stable. He was admitted for observation and to perform some investigations.

The patient was put on Cefoparazone-sulbactam and metronidazole. The patient's CBC was within normal limits. The X-ray chest was suggestive of right-sided pleural effusion with hemothorax and query ruptured hydatid cyst.

Thoracotomy was done. The pleural fluid was sent to the microbiology laboratory for Gram's staining and culture/sensitivity.

The Gram-stained smear was suggestive of empyema and revealed plenty of pus cells and we noticed a single hooklet of *E. granulosus* pathognomonic of ruptured pulmonary hydatid cyst. Many hooklets were then observed in a wet film made from pleural fluid. The report was immediately

* Corresponding author.

E-mail address: dranantmarathe@hotmail.com (A. P. Marathe).

conveyed to the surgery department. The cyst was excised and the patient was given antibiotic along with albendazole 400 mg bid for 14 days. The patient was discharged on the sixth postop day with good respiratory capacity.

2.1. Test reports of various laboratory parameters

Lab investigations revealed HB-12.8 gm/dl, WBC-13310 /mm, CRP- 97.3 mg/l, PMNs-83%, with normal Eosinophil count, ESR- 76 mm in 1 hr and LFT, RFT within normal range.

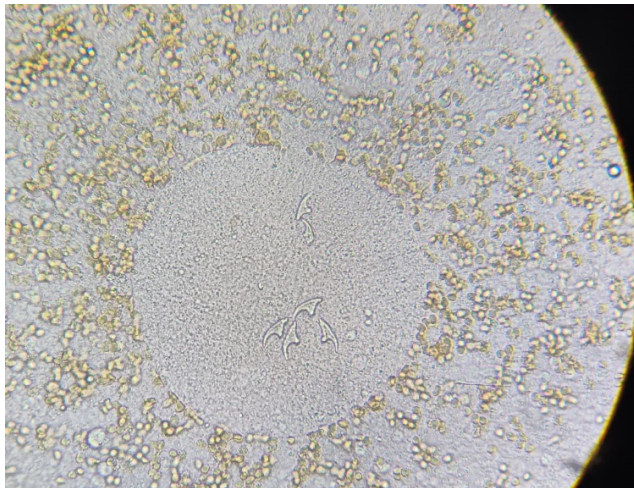


Fig. 1: Hooklets of *E. granulosus* as seen in wet mount microscopy




Fig. 2: Gram stain reveals a hooklet of *E. Granulosus*.

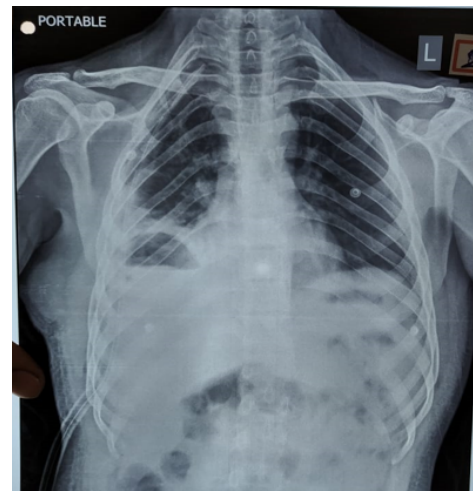


Fig. 3: The X-Ray chest PA view reveals right sided space occupying lesion in chest.

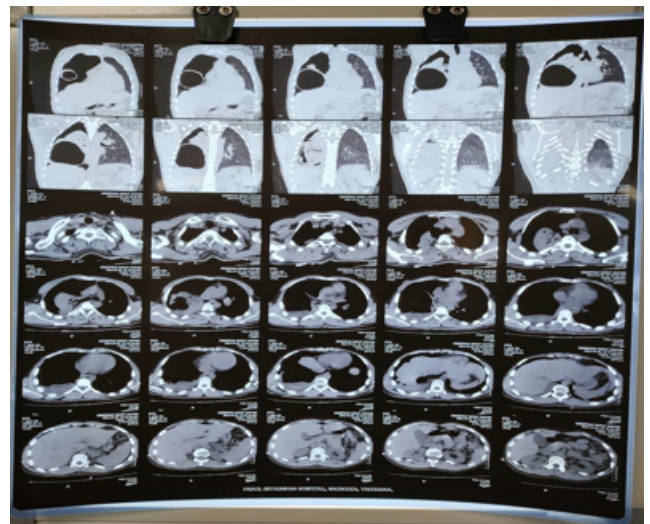


Fig. 4: CT scan suggests right sided moderate pleural effusion, well defined cystic lesion with air fluid levels in right lower lobe with normal liver findings.

3. Discussion

Hydatidosis or hydatid disease is caused by the cestodes *Echinococcus granulosus* or *Echinococcus multi-locularis*.¹ Echinococcosis is endemic to many countries including the Mediterranean region, South America, Australia, New Zealand, the Middle East, Alaska, and Canada. It is widespread among Indian tribes.² Generally hydatid cyst is found in Liver but rarely it can be found in lungs, lungs are considered second most common organ involving hydatid cyst.³ Surgical evacuation or removal is considered the preferred treatment of hydatid cyst.⁴ The Hydatid cyst may remain undiagnosed if the size of the cyst is small and the patient remains asymptomatic. As the size of the cyst

grows, depending on the site and adjacent organs involved, the patient develops symptoms. Rupture of the cyst, either because of trauma or increased size, complications may occur like anaphylaxis and sometimes in severe cases death.^{5,6} The ruptured pulmonary hydatid cysts patient may present with cough, pleuritic pain, hemoptysis, and anaphylactic shock.^{7,8} A ruptured hydatid cyst diagnosis must be made immediately as it requires appropriate surgical management.⁵ Albendazole, with a dose of 10 mg/kg/day for 12 months should be started in the immediate postoperative period to avoid recurrences.⁵

4. Conclusion

Hydatid lung disease can lead to fatal consequences if the cyst ruptures. Early diagnosis and surgical intervention are lifesaving. Long-term albendazole therapy is essential to check the recurrence of the disease. Careful examination of Grams stained smear or wet- film prepared from t specimen can be rewarding.

5. Source of Funding

None.

6. Conflicts of Interest


None.

References

1. Aletras H, Symbas PN. Hydatid disease of the lung. In: Shields TW, LoCicero J, Ponn R, editors. *General Thoracic Surgery*. 5th Edn. Philadelphia: Lippincott Williams & Wilkins; 2000. p. 1113–22.
2. Burgos R, Varela A, Castedo E, Roda J, Montero CG, Serranos S, et al. Pulmonary hydatidosis: surgical treatment and follow-up of 240 cases. *Eur J Cardiothorac Surg*. 1999;16(6):628–34. doi:10.1016/s1010-7940(99)00304-8.
3. Petrov DB, Terzinacheva PP, Djambazov VI, Plochev MP, Goranov EP, Minchev TR, et al. Surgical treatment of bilaterally hydatid disease of the lung. *Eur J Cardiothorac Surg*. 2001;19(6):918–23. doi:10.1016/s1010-7940(01)00693-5.
4. Sheikhy K, Shadmehr MB. Hemoptysis as a complication of capitonage for management of pulmonary hydatid cyst. *Tanaffos*. 2014;13(3):46–8.
5. Dirican A, Yilmaz M, Unal B. Ruptured hydatid cyst into the peritoneum: a case series eur. *J Trauma Emerg Surg*. 2010;36:375–9. doi:10.1007/s00068-009-9056-6.
6. Argemi X, Santelmo N, Lefebvre N. Pulmonary Cystic Echinococcosis. *Am J Trop Med Hyg*. 2017;97(3):641–2. doi:10.4269/ajtmh.17-0298.
7. Culafić DM, Kerkez MD, Mijac DD, Lekić NS, Ranković VI, Lekić DD, et al. Spleen cystic echinococcosis: clinical manifestations and treatment. *Scand J Gastroenterol*. 2010;45(2):186–90. doi:10.3109/00365520903428598.
8. Mokhtari MAM, Spoutin A. Splenic hydatid cyst and relevation with anaphylaxis. *Res. J Med Sci*. 2008;2(5):248–50.

Author biography

Mayur Tadvi, 1st year Resident

Anant Prabhakar Marathe, Professor and HOD
 <https://orcid.org/0000-0001-9001-899X>

Vaidehi J Mehta, Professor

Cite this article: Tadvi M, Marathe AP, Mehta VJ. Empyema and haemothorax due to ruptured pulmonary hydatid cyst- A rare presentation. *IP Int J Med Microbiol Trop Dis* 2023;9(2):126-128.