

Content available at: <https://www.ipinnovative.com/open-access-journals>

IP International Journal of Medical Microbiology and Tropical Diseases

Journal homepage: <https://www.ijmmt.org/>

Case Series

Aeromonas septicaemia - A case series

Aishwarya Babu^{1*}, Mahadevan Kumar¹, Abhijeet Mane¹,
Sunita Mangesh Bhatawadekar¹, Lata Yadav¹

¹Bharati Vidyapeeth Deemed to be University Medical College, Pune, Maharashtra, India



ARTICLE INFO

Article history:

Received 14-12-2023

Accepted 17-01-2024

Available online 27-01-2024

Keywords:

Brackish water

Mortality

Ubiquitous

Aeromonas

ABSTRACT

Aeromonas are ubiquitous Gram-negative bacilli which are seen in brackish or fresh water and soil in subtropical or temperate countries. They were considered as pathogen of many animals including fish but recently they have been gaining importance due to its ability to infect and colonise in human body. Though the most common site of *Aeromonas* infection is gastrointestinal tract, it can cause extraintestinal infections like skin and soft tissue infections, urinary tract infections, biliary tract infections and bacteremia. Its ability to acquire antibiotic resistance naturally from the environment and due to the inappropriate use of antibiotics makes treatment of this unusual pathogen difficult. Many studies have shown high morbidity and mortality rates associated with *Aeromonas*. Therefore, though it was initially considered as a rare cause of bacteremia, *Aeromonas* should be considered as an important nosocomial pathogen.

This is an Open Access (OA) journal, and articles are distributed under the terms of the [Creative Commons Attribution-NonCommercial-ShareAlike 4.0 License](https://creativecommons.org/licenses/by-nc-sa/4.0/), which allows others to remix, tweak, and build upon the work non-commercially, as long as appropriate credit is given and the new creations are licensed under the identical terms.

For reprints contact: reprint@ipinnovative.com

1. Introduction

Aeromonas are Gram negative, motile, facultative anaerobic and halophilic bacilli which belong to the family *Aeromonadaceae*.^{1–3} Although it was initially included in the *Vibrionaceae* family, it was separated based on the properties like absence of growth in 6% sodium chloride, resistance to vibriostatic compound O/129 and absence of ornithine decarboxylase activity.^{1,2} *Aeromonas* are commonly found in environmental sources like soil, fresh & salt water, fruits and vegetables, sewage, and processed food.⁴ Majority of the human infections are caused by *Aeromonas caviae*, *A. hydrophila* and *A. veronii biovar sobria*.⁵ It can cause infection in both immunocompromised and immunocompetent individuals.⁴ Humans acquire infection by consumption or contact with contaminated food or water.⁵ Virulence factors responsible for the establishment of *Aeromonas* infections include the presence

of flagella, fimbriae, capsule; production of enzymes like elastase, hemolysin, protease and lipase. They can also form biofilm. Some strains of *A. hydrophila* produces an exotoxin, aerolysin which can cause tissue damage.¹ Although it is considered as a gastrointestinal pathogen, recently it has also been found to cause a wide spectrum of infections like skin and soft tissue infections, cystitis, pleuropulmonary infections, hepatobiliary infections, ocular infections, primary bacteremia, endocarditis, osteomyelitis, and meningitis.^{3,5} Worldwide the incidence of bacteremia due to *Aeromonas* ranges from 0.12 to 3.3% and mortality rate is 25-63%.⁶

Here we report three cases of septicemia caused by *Aeromonas* species.

2. Case I

A 58-year-old man went to the ophthalmology outpatient department with sudden, painful diminution of vision in the left eye for seven days. He was given treatment with

* Corresponding author.

E-mail address: aishwaryabkk@gmail.com (A. Babu).

moxifloxacin eye drops for seven days after which he was referred to our hospital. He was diagnosed to have pan ophthalmitis of left eye. There was no history of surgery or trauma to the eye. He had history of chronic illnesses like chronic kidney disease (on haemodialysis), systemic hypertension (on beta-blockers), diabetes mellitus (on human insulin). He had an episode of cerebrovascular accident three years ago. His blood investigation showed raised total leukocyte count (TLC) (12,200/cumm), urea (129mg/dl), creatinine (5.63mg/dl) and deranged liver function tests (LFT). Evisceration of left eye was done. Conjunctival discharge and conjunctival tissue were sent for culture. Two samples of blood were sent for culture in BD BACTEC TM FX bottles (Becton, Dickinson and Company, NJ, and USA). Pure growth was obtained after culture of these four samples. On blood agar it grew as large, round opaque colonies and as non-lactose fermenting colonies on MacConkey's agar (Figure I & II). It was motile Gram-negative bacilli which was catalase positive, oxidase positive. Biochemical reactions showed Voges-Proskauer test (VP) positive, indole negative, glucose fermented with production of gas and DNase test positive. Arginine was di-hydrolysed, ornithine & lysine were not decarboxylated. The organism was identified based on biochemical tests and Vitek 2 (bioMerieux, Marcy l'Etoile, France) as *Aeromonas hydrophilia*. The organism was susceptible to penicillins, cephalosporins, aminoglycosides, fluoroquinolones and cotrimoxazole but resistant to carbapenems. The patient was started on injection ceftriaxone and oral doxycycline. The patient was not willing to stay admitted in the hospital till the completion of the course of antibiotic. Hence, he was discharged against medical advice once he became afebrile.

3. Case II

An 18-year-old boy with acute lymphoid leukaemia was admitted to oncology ward with complaints of fever and giddiness. His hemogram showed pancytopenia. His blood was taken for culture from right and left cubital vein after which he was started on cefoperazone-sulbactam, antipyretics and was also given blood transfusion. He had episodes of fever spikes. His serum C-Reactive protein and procalcitonin levels were elevated. Blood was sent for culture from two different sites. The morphology and biochemical characters of the organism was same as in CASE I and it was identified as *Aeromonas hydrophilia*. It was susceptible to cephalosporins, aminoglycosides, fluoroquinolones and cotrimoxazole but resistant to carbapenems. Levofloxacin was added along with cefoperazone-sulbactam. Patient still had on and off fever. His haemoglobin (Hb), TLC and platelets levels were showing a decreasing trend. He was shifted to intensive care unit (ICU) and kept in positive pressure isolation. A combination of antibiotics, meropenem and teicoplanin

were started along with the antifungal flucytosine. Before the initiation of antibiotics, blood was sent for culture which grew *Pseudomonas aeruginosa* which was pan drug resistant (resistant to carbapenems and polymyxins also). Patient succumbed to his illness in a few days.

4. Case III

A 56-year-old man who was a chronic alcoholic was brought to the emergency medicine department with complaints of fever for five days, two episodes of malena and altered sensorium for one day. He had history of chronic liver disease and chronic kidney disease. On examination, he was afebrile, his pulse rate was 130 per minute, blood pressure was 80/60 mm mercury (Hg), oxygen saturation was only 84% on room air for which he was intubated. Glasgow coma scale was E4V4M5 (best eye response, best vocal response, best motor response). The patient was transferred to the ICU and started on anti-hepatic encephalopathy medications and antibiotic piperacillin-tazobactam. Blood investigations showed anaemia (Hb: 7g/dl), thrombocytopenia (Platelet: 13,000/cubic mm), deranged LFT, deranged renal function test and hyponatremia. His procalcitonin levels were elevated suggestive of septic shock. He was diagnosed to have septic shock and hepatic encephalopathy. Antibiotics were changed to meropenem and doxycycline. Computed Tomography (CT) of brain showed intraparenchymal and subarachnoid haemorrhage. Blood from right and left cubital vein was sent for culture which grew *Aeromonas caviae*. The identity of the organism was confirmed by VP test which was negative (*A. hydrophilia* will give VP positive reaction) The isolate was susceptible to penicillin, cephalosporins, carbapenems, aminoglycosides, fluoroquinolone and cotrimoxazole. Hemogram showed a rapid rise in TLC in four days (from 4500 to 32,400/cumm) while Hb and platelet levels were reducing. His D-dimer levels were also very high (13002 ng/ml) which was suggestive of impending clotting disorder. Platelet transfusion was done. After a few days, the patient developed blackish fluid filled bullae in his body. Blood was sent for culture from radial artery and internal jugular vein for culture both of which grew *Klebsiella pneumoniae* and *Acinetobacter baumannii*. Biofire panel done on positively flagged BD BACTEC TM FX bottle (Becton, Dickinson and Company, NJ, and USA) also identified the same organisms with resistance genes, CTX-M, NDM and OXA-48-like. Polymyxin B was added. Patient did not show any response to treatment and succumbed to his illness.

5. Discussion

For a very long time, *Aeromonas* has been considered as a major cause of gastroenteritis. *A. hydrophilia* causes mild diarrhoea and rarely cellulitis in immunocompetent individuals.⁷ But it can cause severe infections

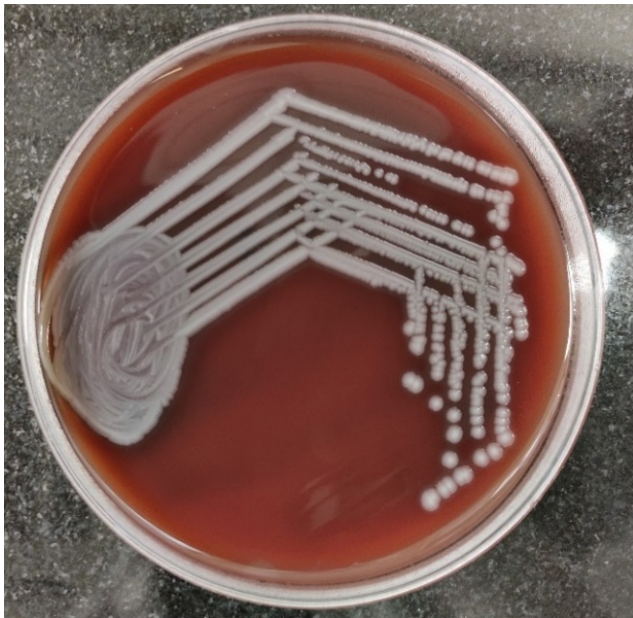

Figure 1: Growth of *Aeromonas hydrophilia* on blood agar

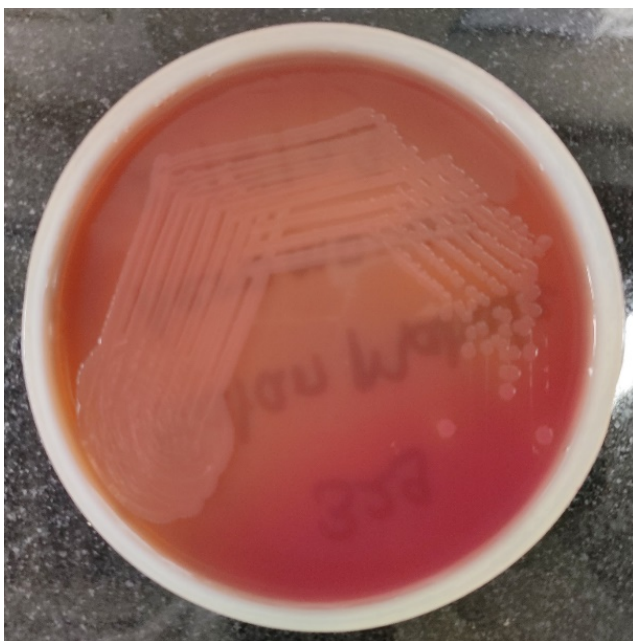


Figure 2: Growth of *Aeromonas hydrophilia* on MacConkey agar

like septicaemia in immunocompromised patients. Hepatobiliary diseases, malignancies like leukaemia, diabetes mellitus are the common risk factors seen in these patients.^{1,5–7} In the present study, two patients had history of chronic liver disease and one patient had acute lymphocytic leukemia. The source of *A. hydrophilia* in septicemia could be from the gastrointestinal colonisation or wound, infected with contaminated soil or water.¹ In the present study, source of *Aeromonas* could not be traced. In

a retrospective study from 2004–2011 in Taiwan by Wu CJ et al., 160 cases of *Aeromonas septicaemia* were reported. *A. caviae*, *A. hydrophilia*, *A. veronii* and *A. dhakensis* were the major species isolated.⁸ In another study from Japan (2000–2010) by Morinaga Y et al., seven cases of *Aeromonas septicaemia* were reported.⁹ Little data on *Aeromonas septicaemia* exists in India. Symptoms most associated with *Aeromonas septicaemia* are abdominal pain, fever, jaundice, and septic shock. As similar symptoms are also seen in septicemia due to other Gram-negative bacilli, *Aeromonas septicaemia* is difficult to diagnose.¹⁰ The presenting complaints of two of our patients were fever. Lau S.M et al, has described that *Aeromonas septicaemia* is often polymicrobial, associated with *Staphylococcus aureus*, *Klebsiella pneumoniae* and *Escherichia coli*.¹⁰ In contrary to this, all the three cases in the present study had monomicrobial septicemia. In their study, Janda et al., also found that *Aeromonas septicaemia* is monomicrobial.¹¹

Aeromonas species are resistant to first generation cephalosporins and penicillins.⁶ The most active antibiotic for *Aeromonas* infections are fluoroquinolones, third generation cephalosporins and imipenem.⁵ Ciprofloxacin or levofloxacin are recommended by the current guidelines as first line therapy for treatment of *Aeromonas* infection.¹² *A. hydrophilia* expresses class B, C, D betalactamases.⁶ CphA is the most common metallo-beta-lactamase (MBL) found in *A. hydrophilia* which is not very active on cephalosporins and penicillin but highly active on carbapenems.¹² Though reports have shown that CphA mediated carbapenemase resistance can be easily missed by routine susceptibility testing, two of our isolates showed this pattern of resistance. On studying beta-lactamases from *Aeromonas* species isolated from waste water sources, Piotrowska M et al. found that the majority of the genes were plasmid encoded. This can result in dissemination of these genes from wastewater to another environment.^{13–15} Therefore microbiological surveillance of intravenous fluids and hospital water will be required to prevent *Aeromonas* associated hospital acquired infections.⁸ Microbiologists and clinicians should also be alert about the emerging multidrug resistant *Aeromonas* species which can increase the morbidity and mortality due to *Aeromonas septicaemia* in our country.

6. Conclusion

Aeromonas species are found ubiquitously in the environment predominantly in the water bodies. With the uncontrolled use of antibiotics in humans, animals, agriculture, aquaculture, *Aeromonas* species are becoming multidrug resistant. The disturbing consequence is that these antibiotic resistance genes can get disseminated from water to humans. This is resulting in serious and life-threatening infections in humans like septicaemia especially in developing countries. Therefore, along with

the judicious use of antibiotics, maintenance of standards of water quality, sanitary measures for preparation of food, efficient sewage disposal methods are required to prevent the spread of *Aeromonas*.

7. Source of Funding

None.


8. Conflict of Interest


None.

References


1. Batra P, Mathur P, Misra MC. *Aeromonas* spp.: An Emerging Nosocomial Pathogen. *J Lab Physicians*. 2016;8(1):1–4.
2. Igbinoza IH, Igumbor EU, Aghdasi F, Tom M, Okoh AI. Emerging *Aeromonas* species infections and their significance in public health. *Scientific World J*. 2012;p. 625023. doi:10.1100/2012/625023.
3. Dwivedi M, Mishra A, Prasad A, Azim A, Singh RK, Baronia AK, et al. *Aeromonas caviae* septicemia in immunocompetent gastrointestinal carriers. *Braz J Infect Dis*. 2008;12(6):547–8.
4. Pessoa RBG, De Oliveira W, Correia M, Fontes A, Coelho L. *Aeromonas* and Human Health Disorders: Clinical Approaches. *Front Microbiol*. 2022;13::868890. doi:10.3389/fmicb.2022.868890.
5. Okumura K, Shoji F, Yoshida M, Mizuta A, Makino I, Higashi H, et al. Severe sepsis caused by *Aeromonas hydrophila* in a patient using tocilizumab: a case report. *J Med Case Rep*. 2011;5:499. doi:10.1186/1752-1947-5-499.
6. Fernández-Bravo A, Figueras MJ. An Update on the Genus *Aeromonas*: Taxonomy, Epidemiology, and Pathogenicity. *Microorganisms*. 2020;8(1):129. doi:10.3390/microorganisms8010129.
7. Park SY, Nam HM, Park K, Park SD. *Aeromonas hydrophila* Sepsis Mimicking *Vibrio vulnificus* Infection. *Ann Dermatol*. 2011;23((Suppl 1):25–9.
8. Wu CJ, Chen PL, Hsueh PR, Chang MC, Tsai PJ, Shih HI, et al. Clinical implications of species identification in monomicrobial *Aeromonas* bacteremia. *PLoS One*. 2015;10(2):117821. doi:10.1371/journal.pone.0117821.
9. Morinaga Y, Yanagihara K, Araki N, Harada Y, Yamada K, Akamatsu N, et al. Clinical characteristics of seven patients with *Aeromonas* septicemia in a Japanese hospital. *Tohoku J Exp Med*. 2011;225(2):81–4.
10. Lau SM, Peng MY, Chang FY. Outcomes of *Aeromonas* bacteremia in patients with different types of underlying disease. *J Microbiol Immunol Infect*. 2000;33(4):241–7.
11. Janda JM, Abbott SL. The genus *Aeromonas*: taxonomy, pathogenicity, and infection. *Clin Microbiol Rev*. 2010;23(1):35–73.
12. Hilt EE, Fitzwater SP, Ward K, Maurice ADS, Chandrasekaran S, Garner OB, et al. Carbapenem Resistant *Aeromonas hydrophila* Carrying bla_{CPH7} Isolated From Two Solid Organ Transplant Patients. *Front Cell Infect Microbiol*. 2020;10:563482. doi:10.3389/fcimb.2020.563482.
13. Piotrowska M, Przygodzińska D, Matyjewicz K, Popowska M. Occurrence and variety of β-Lactamase genes among *Aeromonas* spp. isolated from urban wastewater treatment plant. *Front Microbiol*. 2017;8:863. doi:10.3389/fmicb.2017.00863.
14. Pessoa RBG, De Oliveira W, Correia M, Fontes A, Coelho L. *Aeromonas* and Human Health Disorders: Clinical Approaches. *Front Microbiol*. 2022;13:868890. doi:10.3389/fmicb.2022.868890.
15. Kaki R. A retrospective study of *Aeromonas hydrophila* infections at a university tertiary hospital in Saudi Arabia. *BMC Infect Dis*. 2023;23(1):671. doi:10.1186/s12879-023-08660-8.


Author biography

Aishwarya Babu, Assistant Professor  <https://orcid.org/0000-0001-6667-8074>

Mahadevan Kumar, Professor  <https://orcid.org/0000-0003-1656-1649>

Abhijeet Mane, Associate Professor  <https://orcid.org/0000-0002-6007-6942>

Sunita Mangesh Bhatawadekar, Professor  <https://orcid.org/0000-0002-1808-7808>

Lata Yadav, Tutor  <https://orcid.org/0000-0001-7007-6404>

Cite this article: Babu A, Kumar M, Mane A, Bhatawadekar SM, Yadav L. *Aeromonas septicaemia* - A case series. *IP Int J Med Microbiol Trop Dis* 2023;9(4):285-288.