

Content available at: <https://www.ipinnovative.com/open-access-journals>

IP International Journal of Medical Microbiology and Tropical Diseases

Journal homepage: <https://www.ijmmt.org/>

Case Report

An immigrant with easy fatigability and eosinophilia caused by hookworm (A neglected tropical disease)

Gaurav Vipul Chotaliya¹, Rashmika Parmar¹, Hitesh K. S hingala¹,
Pushpa Kateshiya^{1*}, Krunal Mehta¹

¹Dept. of Microbiology, Shri M.P. Shah Medical College, Jamnagar, Gujarat, India



ARTICLE INFO

Article history:

Received 31-07-2024

Accepted 22-08-2024

Available online 27-09-2024

Keywords:

Hookworm
Immigrant
Eosinophilia
Parasitic disease
Eggs
A duodenale
Anemia
Microscopy

ABSTRACT

Hookworm; a one among the 20 neglected tropical disease (NTD) defined by WHO causing severe anemia, weakness, malnutrition in tropical countries like India, estimated that affected one billion people in the world. The blood sucking *A. duodenale* and *N. Americanus* are the causative agents. An adult immigrant landed in emergency with severe lethargy and fatigability with H/o travel to endemic area in a short time; laborer in farm been evaluated for possible cause. Lab reports concluded with severe anemia and eosinophilia. Stool culture was sterile. Next day fresh sample of stool for microscopy revealed eggs of hookworm with larva inside. We concluded with the diagnosis of hookworm & patient improved with blood transfusion which was started before labelling the diagnosis because of severe anemia and also with albendazole given in proper manner.

So it is important to keep in mind that generalized weakness, lethargy, anemia, eosinophilia in immigrants drawing attention to parasitic disease and we have to break the chain of transmission by giving community treatment, deworming, increase sanitation, WASH program implementation, footwear wearing practices to workers, public education. Keep in mind the diagnosis as hookworm infection & other NTDs especially in the immigrants. Proper treatment, regular surveillance involving multiple departments of hospital & medical college is important to eliminate this blood-sucking nematodes in 21st century.

This is an Open Access (OA) journal, and articles are distributed under the terms of the [Creative Commons Attribution-NonCommercial-ShareAlike 4.0 License](https://creativecommons.org/licenses/by-nc-sa/4.0/), which allows others to remix, tweak, and build upon the work non-commercially, as long as appropriate credit is given and the new creations are licensed under the identical terms.

For reprints contact: reprint@ipinnovative.com

1. Introduction

Hookworm is one of the most important soil transmitted helminth. It belongs to family ancylostomatidae which is having 2 species infecting the humans: *Ancylostoma duodenale* and *Necator americanus*.¹ Hookworm infection is a public health concern caused by nematode that lives in the small intestine of most mammals as its hosts, such as dogs, cats and humans also. It is under the group of neglected tropical diseases (NTD).²

It is one of the most common chronic infections with an estimated 740 million cases in rural poverty area of tropics

and subtropics. It is estimated that approx. 1 billion people are infected in the underdeveloped countries of the tropics and subtropics.³ Highest prevalence of hookworm is in Asia and Sub-Saharan Africa.²

Hookworm present across the national & international boundaries. It is present since a very long time. For example, the reputation of pre-1949 China as the "Sickman of Asia" was partly a result of high prevalence and intensity of infection with hookworm. Mohandas Gandhi, the father of our Nation-India had hookworm infection in the last years of his life. Though it is more common in Asia and African parts, it is a factor in slowing down the economy of most of the developed nations like US, England, etc. The use of DALY- disability adjusted life years as a quantitative

* Corresponding author.

E-mail address: pushpa22kateshiya@gmail.com (P. Kateshiya).

measure of burden of disease reveals that this infection outranks African trypanosomiasis, chaga's disease, dengue, schistosomiasis and leprosy.³

A more than 200 million people are estimated to be infected in India. India is contributing 25% of total global cases.⁴ Worldwide reductions in prevalence of hookworm is very less in comparison to other soil-transmitted helminths (STH).⁵ The STH prevalence in India is 17.0%. Hookworm is the predominant species, with prevalence of 21.0%. The prevalence rate of this disease is quite shocking with estimated that 1 in 5 people are infected with hookworm and other soil-transmitted helminths.⁶ *N. Americanus* is predominant in southern part of India whereas *A. duodenale* is in North India. Necator is present in all states except in UP and Punjab.¹ Recently a new member *A. ceylanicum* reported from Kolkata. The heavily infected states are UP, Bihar, Assam, West Bengal, Odisha, Tamil Nadu in India.¹

The two blood sucking, blood thirsty nematodes *Ancylostoma duodenale* & *Necator americanus* that responsible for the human infections,^{2,7} having ability of spread through the pet dogs and pet cats are also known. The dog hookworm *A. caninum* causes human enteritis in Australia and *A. Braziliense* causes cutaneous larva migrans.^{3,8}

Common risk factors for human infections are poor sanitation, low socio-economic status, improper sewage disposal, unhygienic practices, uncooked food, farmers, migration from hookworm endemic states. In view of clinical manifestations, young adult males (15-25 years) are commonly affected but anemia because of chronic blood loss is more prevalent and severe in children and pregnant females. Hookworm infected patients are present with abdominal pain, vomiting, nausea, weakness, iron deficiency anemia. The presentation can be asymptomatic also.

The laboratory diagnosis of Hookworm disease can be done by discovery of eggs in stool, egg counting by various methods, different molecular methods like PCR for species differentiation. This parasite can induce eosinophilia which can be observed on peripheral blood examination.⁹ Thus the diagnosis of hookworm is involving multiple departments of a medical college and tertiary care hospital not only microbiology but also pathology, medicine, biochemistry and P.S.M., Pharmacology.

Since immigrants are very important source of transmitting the diseases not only parasitic but also bacterial and other exotic viral diseases like Covid-19, it is wise to be vigilant for screening the immigrants as well as noticing their travel route and having information of local endemic disease prevalent in their resident states / countries. In this case report, different aspects of hookworm infection including its treatment and preventive control measures for community will be discussed.

2. Case Presentation

A 36 years old male patient came to the emergency department with complaints of generalized weakness, easy fatigability. The patient was completely lethargic. He had weakness since past 10-15 days and it was increasing in nature day-by-day. The patient did not have fever, vomiting, diarrhea, hypertension and any heart or lung disease. Patient was maintaining 99% SpO₂ on room air. On further history taking it came to know that patient was complaining abdominal pain & patient was chronic alcoholic. He was laborer in farm; belonging to lower socio-economic class & travelled to his native place in North India a short time ago before coming here in western part of Gujarat. He did not have sore throat/neck stiffness, palpitation and dysuria. On physical examination, pallor was present along with bilateral pitting edema. The skin of patient was waxy and having a yellowish tinge. Patient had exertional dyspnea.

By looking at above picture, physician ordered severe investigations. Complete blood count (CBC) revealed hemoglobin level 3.3 gm/dl, low RBC count, total WBC count 7,800 cells/cumm with neutrophils, platelets lymphocytes in normal limits. Peripheral smear examination concluded with severe degree normocytic normochromic anemia with absolute eosinophil count(AEC) of 1170 cells/cumm denoting severe eosinophilia, few microcytic hypochromic RBCs, many elliptocytes & tear drop cells seen. No malarial parasite seen. The biochemistry report was showing normal creatinine, urea, sodium, potassium levels. In liver function test reversed albumin / globulin ratio noted. Then, physicians choose to rule out any transfusion related disease like hepatitis - B, C, HIV. All were negative.

Then stool culture was sent. Stool culture was performed for enteric pathogens specifically shigella, salmonella, also proceeded stool for routine-micro examinations. The bacterial culture reports were all negative because up to that time empirical treatment already given for abdominal pain; Levofloxacin was started. USG was done; found nothing significant except fatty liver disease.

Hence, physician was guided to send fresh morning stool sample for parasitic infection. On macroscopic examination, the stool was brown colored, semisolid in consistency. No blood/mucous/pus/adult worms seen. Occult blood test was negative. By stool microscopy, egg like structures found, which were non-bile stained, oval shaped, surrounded by thin, translucent egg shell. Ovum was segmented with 8 blastomeres. Clear space was present between egg shell and embryo. (Figure-1) So, this was enough to label the diagnosis as Hookworm infection in this immigrant. We found approx. 20 eggs per low power field that corresponds in 2000 eggs/gm of stool by Stoll's egg counting method.

Treatment was started. Patient got transfused with 4 units of PCV for compensating severe anemia. Tab. Albendazole 400mg/12hrs. for two consecutive days given. Ferric carboxymaltose 1gm IV given with IV multivitamin

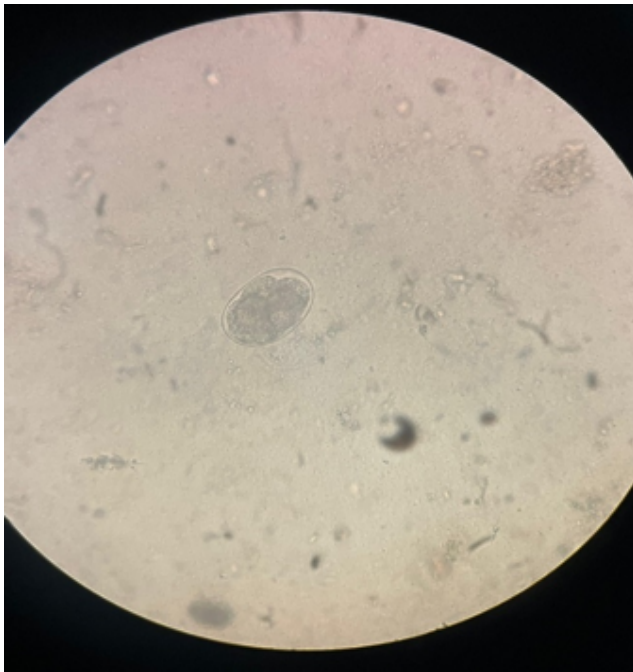


Figure 1: Microscopic view of hookworm egg with blastomeres inside.

infusion. Patient was improved after treatment. Weakness was resolved. Tab. Folic acid, Iron prescribed. Two months later patient came for follow up and given albendazole (400 mg). Hematological parameters came back to normal with negative examination of stool for eggs/ova.

3. Discussion

Hookworm is named after the typical shape of adult worm of *A. duodenale* which is straight except at anterior end which is bent dorsally in the same direction of body curvature.^{1,10} The hookworm is transmitted via contact with contaminated soil.¹¹ Conditions which are favorable for hookworm are presence of infected cases/carriers, open air defecation and not processing excreta properly, environment-warmer months.¹⁰ Adult worms live in the small intestine of infected persons, Mostly in jejunum, less often in duodenum, rarely in ileum.¹⁰ Humans are the natural host without any intermediate host. Infective form for human is 3rd stage filariform larva.¹⁰ The early interaction between the infective stage and host determines whether the parasite will be able to gain a foothold, evade the host's immune system, resumes development and causes infections. The period between entry of infective larva into the host and its appearance several weeks after as a blood feeding adult in small intestine has always been a 'black box'.¹²

Eggs released by adult female worm from infected person are passed in the feces where they hatch within

days to release L1 (first stage larva). L1 feeds on soil and becomes L2 eventually to the L3 stage which is arrested developmentally, non-feeding, free living. L3 is highly mobile and exhibits stage specific behaviors designed to increase the chance of locating host. Once the host is there, further events depend on species of hookworm. *N. Americanus* enter only by skin penetration while *A. duodenale* follows skin route or enter orally also. From skin penetration, larva are carried first by venules to right heart and then to lungs. Then larva ruptures and enter the alveoli, migrating to bronchi, trachea. After being swollen, larva come to GIT where they develop adult stage.^{10,11} In small intestine, L3 molts into L4 and to adults and completes life cycle.

A novel virulence factor has been identified ASP - *Ancylostoma Secreted Protein - 1* implies in transition to parasitism and act as modulator of host immune response. Other enzymes for skin penetration includes cysteinyl and aspartyl proteases released by L3 Larva & metalloproteases, hyaluronidase.¹²

3.1. How did hookworm infect this patient?

By seeing the history; he was farmer, history of travel from an endemic belt, unhygienic practices of food, sanitation, he might have been in contact with infective larval stage. No local site / foot side itching or redness or marks were seen. Regular exposure to hookworm larva gives rash called as "Ground itch".¹¹ Though the skin is most common route, *A. duodenale* can also get transmitted through ingestion of larva. They can develop to adults without going to lungs. This Wakana disease, is having nausea, vomiting, pharyngeal irritation, cough and hoarseness.¹¹ It occurs after large numbers of larva ingested. But this patient had no such history / symptoms 1 week prior hospitalization. So, keeping this in consideration, patient got infected via skin route only.

Acute infection of Hookworm presents with fatigue, nausea, abdominal pain, vomiting, diarrhea with black / red stools, pallor and weakness.^{11,13} Chronic infections are being manifested with iron deficiency anemia, edema of feet, face, mental and physical retardation.^{11,14}

3.2. What is the mechanism for anemia?

Blood loss occurs when worm uses their cutting apparatus to attach themselves to intestinal mucosa and contract their esophagus to create a negative pressure and this results in sucking of a plug of tissue into buccal capsule. Hence capillaries, arterioles are ruptured.¹⁵ Adult worm also releases some anticlotting agents to make sure continuous blood flow.³ *A. duodenale* is associated with more blood loss(0.2 ml/ day) than *N. americanus*(0.08 ml/day), so anemia is more prevalent in *A. duodenale* infection. Iron loss in *A. duodenale* is 0.76 mg/day and *N. americanus* is 0.45

mg/day.¹⁰

Hypoproteinemia, reversed A/G ratio is associated with features of edema of face, limbs, pot belly; seen in this patient. A yellow-colored skin was seen as a feature of tropical chlorosis.³

After 5 to 9 weeks of onset of infection, the eosinophilia peak is noted and correspond with appearance of adult hookworm in intestine.³ Some reports suggest the range of peak eosinophil count is from 1350 cells/ml to 3828 cells/ml.¹⁶ This patient was having 1170 cells/ml. Allergic, infectious, idiopathic, neoplastic diseases are also associated with increase AEC. So based on this finding, eosinophilia is very helpful in drawing the diagnosis towards parasite disease but still an absence of eosinophilia does not mean that there is not a parasitic infection. In adults, capability for daily work significantly hampers as they become anemic, in this infection.

Direct method of lab diagnosis in the hookworm case includes, direct wet microscopy of stool sample or by concentration technique. Stool samples examined after 24 hours of collection, having hatched egg with rhabditiform larva in it.¹⁰ [Figure 2]

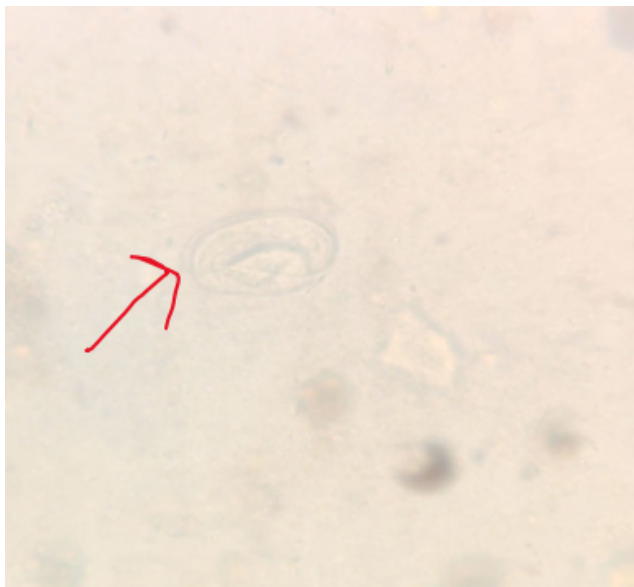

Figure 2: Hatched egg of hookworm with rhabditiform larva in it.

For measuring the intensity of infection, egg counting was done by Stoll's method. 20 eggs per low power objective field found so the probable count is $20 \times 100 = 2000$ eggs per gram of feces, while range of severe infection is >4000 eggs/gm of stool.¹¹ Stool culture not done because of limited facility at our center. Unfortunately, we were unable to perform species differentiation which is mainly done by their buccal capsule morphology. Indirect method of lab diagnosis includes peripheral smear examination for anemia, red cell morphology, eosinophilia, ESR (increased in this patient), stool occult blood test.

For treatment purpose most practical effective drug is albendazole (400 mg) single dose or mebendazole (500 mg). Pyrantel pamoate used in pregnant patient. Tetrachloroethylene is toxic and Thiabendazole is less effective drug. Patient is also having an interference with absorption of vit.B₁₂, iron & folic acid. That's why it's necessary to be supplemented.

In this case, anemia was so severe that before starting anthelmintic treatment, it was necessary to correct anemia by PCV. He got total 4-unit PCV in appropriate manner. After correction, his weakness and lethargy disappeared, hematological parameters improved and normalized in further follow-ups and repeated examination of stool for ova/egg was negative after 2 months.

It is very important to discuss here the prophylactic precautions in order to prevent / control the spread of hookworm because even single case is a red flag sign as he came from endemic belt in north India to our region for labor & many such laborers are migrating and immigrating between endemic and non-endemic areas and transmitting infections.

The steps are

1. Use of footwear to prevent entering the larva by foot.
2. Gloves for hand safety.
3. No open-air defecation and use of sanitary latrines.
4. Excreta disposal.
5. Treatment of patient & carriers preferably at the same time to limit source of infection.
6. Handwashing that prevents oral ingestion of eggs.
7. School based deworming which will reduce transmission of hookworm among children.^{3,17}
8. WASH program water, sanitation and hygiene program.¹⁰

This patient is already passing eggs in stool; observed by microscopy. So, to control further outbreaks & break the chain of transmission & eggs from reaching soil, it is necessary to treat a case with all his contact members. Also screening the community by local health authorities for such tropical parasitic disease particularly where these immigrants are residing like in industry, farms is necessary after the case is isolated.

4. Conclusion

We have reported here case of a hookworm in an immigrant. Considering history of travelling, occupation like farming denotes that there can be many cases which are incubating or already been to carrier stages. Though it is said that direct transmission among person to person is not possible by feces because of egg taking time of 3 weeks to mature in soil before becoming causative but by studying this case, it is important to break the chain by doing surveillance properly, checking the soil quality, water, hygiene status in particular areas, arranging camps for medical health - checkups,

collecting stool samples and processing just by microscopy on field, deworming, community health education under WASH strategy will be very helpful to eliminate the hook worm disease in this 21st century.

To conclude the report; eosinophilia in immigrants, especially from lower-middle socio-economic class, recent travel h/o, anemia, fatigability, negative bacterial culture of stool warrants to investigate further for this hookworm infection because this if neglected, really becomes community problem and reduces previously healthy people's lifestyle.

5. Conflict of interest

None.


6. Source of funding

None.


References


- Sastry AS, Bhat S. Nematodes-1(Intestinal Nematodes). In: Essentials of Medical Parasitology. New Delhi, India: Jaypee Brothers Medical; 2014. p. 220–47.
- Mohanty A, Gupta P, Gupta P, Shankar R. Diagnostic Dilemma in Hookworm Infection: An Unusual Presentation. *Int J Curr Microbiol Appl Sci.* 2018;7(3):3769–71.
- Hotez PJ, Brooker S, Bethony JM, Bottazzi ME, Loukas A, Xiao S, et al. Hookworm infection. *N Engl J Med.* 2004;351(8):799–807.
- Salam N, Azam S. Prevalence and distribution of soil-transmitted helminth infections in India. *BMC Public Health.* 2017;17:201. doi:10.1186/s12889-017-4113-2.
- Herricks JR, Hotez PJ, Wanga V, Coffeng LE, Haagsma JA, Basanez MG, et al. The Global Burden of Disease Study 2013: What Does It Mean for the NTDs? *PLoS Negl Trop Dis.* 2017;11(8):11. doi:10.1371/journal.pntd.0005424.
- Ajjampur SSR, Kaliappan SP, Halliday KE, Palanisamy G, Farzana J. Epidemiology of Soil Transmitted Helminths and Risk Analysis of Hookworm Infections in the Community: Results from the DeWorm3 Trial in Southern India. *PLoS Negl Trop Dis.* 2021;15(4). doi:10.1371/journal.pntd.0009338.
- Pearson MS, Pickering DA, Tribolet L, Cooper L, Mulvenna J, Oliveira LM, et al. Neutralizing Antibodies to the Hookworm Hemoglobinase Na-APR-1: Implications for a Multivalent Vaccine against Hookworm Infection and Schistosomiasis. *J Infect Dis.* 2010;201(10):1561–9.
- Prociw P, Croese J. Human Enteric Infection with *Ancylostoma Caninum*: Hookworms Reappraised in the Light of a “New” Zoonosis. *Acta Trop.* 1996;62(1):23–44.
- Wu KL, Hsu SK, Chiu KW, Chiu YC, Changechien CS. Endoscopic Diagnosis of Hookworm Disease of the Duodenum: A Case Report *J Int Med Taiwan.* 2002;13:27–30.
- Ghosh S, Paniker CKJ. Paniker's Textbook of Medical Parasitology. New Delhi: Jaypee/The Health Sciences Publisher; 2018. doi:10.5005/jp/books/18076.
- Wang CH, Lee SC, Huang SS, Chang LC. Hookworm Infection in a Healthy Adult That Manifested as Severe Eosinophilia and Diarrhea. *J Microbiol Immunol Infect.* 2011;44(6):484–7.
- Hawdon JM, Hotez PJ. Hookworm: developmental biology of the infectious process. *Curr Opin Genet Dev.* 1996;6(5):618–23.
- Anyaeze CM. Reducing Burden of Hookworm Disease in the Management of Upper Abdominal Pain in the Tropics. *Trop Doct.* 2003;33(3):174–5.
- Waina M, Unghango P, Williams D, Djanghara A, Clement M, Karadada L, et al. The Prevalence of Hookworm Infection, Iron Deficiency and Anaemia in an Aboriginal Community in North-West Australia. *Med J Aust.* 1997;167(10):554–5.
- Hotez PJ, Pritchard DI. Hookworm infection. *Sci Am.* 1995;272(6):68–74.
- Maxwell C, Hussain R, Nutman TB, Poindexter RW, Little MD, Schad GA, et al. The Clinical and Immunologic Responses of Normal Human Volunteers to Low Dose Hookworm (*Necator Americanus*) Infection. *Am. J Trop Med Hyg.* 1987;37(1):126–34.
- Chopra P, Shekhar S, Dagar VK, Pandey S. Prevalence and Risk Factors of Soil-Transmitted Helminthic Infections in the Pediatric Population in India: A Systematic Review and Meta-Analysis. *J Lab Physicians.* 2023;15(1):4–19.

Author biography

Gaurav Vipul Chotaliya, 2nd Year Resident  <https://orcid.org/0009-0007-1593-8551>

Rashmika Parmar, Associate Professor

Hitesh K. S hingala, Professor and Head  <https://orcid.org/0000-0003-2402-2872>

Pushpa Kateshiya, Assistant Professor  <https://orcid.org/0000-0001-6574-6346>

Krunal Mehta, Associate Professor  <https://orcid.org/0000-0003-4358-9145>

Cite this article: Chotaliya GV, Parmar R, hingala HKS, Kateshiya P, Mehta K. An immigrant with easy fatigability and eosinophilia caused by hookworm (A neglected tropical disease). *IP Int J Med Microbiol Trop Dis* 2024;10(3):284–288.