

Primary tuberculosis of appendix: A rare presentation

Motilal Bunkar¹, Rajendra Prasad Takhar^{2,*}, Arya Savita³, Kiran Mirdha⁴

¹Senior Resident, ²Assistant Professor, ³PG Student, Dept. of Respiratory Medicine, Govt. Medical College, Kota, Rajasthan, ⁴Medical Officer, Dr. SN Medical College, Jodhpur, Rajasthan

***Corresponding Author:**

Email: drrajtakhar@gmail.com

Abstract

Gastrointestinal tuberculosis is a common form of extra pulmonary tuberculosis. Tuberculosis of the appendix is a rare variant of gastrointestinal tuberculosis even in countries where tuberculosis is endemic like India; however, it should be included as one of the differential diagnosis of appendicular swelling as its clinical presentation mimicking various other conditions e.g. acute on chronic appendicitis, appendicular malignancy or abscess. The majority of the previously reported cases of tubercular appendicitis had a primary focus elsewhere in the body. Here we are describing a case of isolated tuberculosis of the appendix, who underwent laparotomy with the suspicion of appendicitis. The diagnosis was confirmed by histopathological examination of the resected specimen. No primary focus was found in elsewhere in the body. He was treated with four drug anti-TB regimen (2HERZ+4HR) and was asymptomatic in full course of therapy and later also till six months of follow up. Apart from rarity due to primary involvement, this case report highlights the rare clinical presentation and significance of histopathology in the diagnosis of this uncommon entity.

Keywords: Primary tubercular appendicitis, Histopathology, Anti-TB regimen.

Access this article online
Website: www.innovativepublication.com
DOI: 10.5958/2455-6807.2016.00019.2

Introduction

Tuberculosis (TB) is a major public health problem in developing countries like India. India accounts for one-fifth of the global TB incident cases. Gastrointestinal tuberculosis is quite rare, representing only 3% of all extra pulmonary cases. The most common site of intestinal tuberculosis is ileocecal region. Appendicitis caused by Mycobacterium tuberculosis is extremely rare and its presentation is also atypical. The incidence of secondary appendicular tuberculosis is 1.5 to 30%¹. Primary (isolated) tuberculosis of the appendix is a rare clinical entity, its reported incidence being 0.1 to 0.3%². It has no specific clinical and radiological feature so pre-operative diagnosis is not possible. Here we are discussing a case of isolated tuberculosis of appendix in a 25 year old male diagnosed by histopathological examination of resected specimen and treated with anti-TB drugs.

Case History

A 25 years old male came to the emergency department with complaints of pain in right lower abdomen, low grade fever and disturbed bowel habits of 10 days duration. He denied for melena and hematemesis. His past history was unremarkable. On general examination patient was febrile with normal vital signs, well-nourished and build. Local

examination of the abdomen revealed tenderness in right iliac region, but no palpable mass found. All routine blood investigations were within normal limit except for an elevated leukocyte count at 15,000/mm³. Skiagram of the chest and ultrasonography of the abdomen were normal. With the presumptive diagnosis of appendicitis emergency laparotomy was performed. A thickened, inflamed appendix found with adhesions in peri-appendicular tissues. The surrounding structures (including ileum, caecum and pelvic organ) were normal with no regional lymphadenopathy. Gross examination of appendectomy specimen showed grayish white appearance, measuring approximately 5 cm in length. On cut surface lumen was patent and had thickened wall with no mucosal ulceration (Fig. 1). Histopathology revealed a single layer of low columnar cell lined epithelium with open crypts of lieberkuhn. The lamina propria contains lymphoid follicles and non caseating epitheloid cell granuloma consists of epitheloid cells surrounded by lymphocytes, histiocytes, Langhans giant cell and rimmed by fibroblast (Fig. 2). Retrospectively patient was evaluated for primary focus. Contrast enhanced tomography (CECT) scan of the abdomen and pelvis didn't shows any abnormality. Colonoscopy showed normal caecum and ileum. Montoux test was positive. Thus, a final diagnosis of isolated (primary) tuberculosis of the appendix was made and the patient was treated with four drug anti-TB regimen (2HERZ+4HR). He remained asymptomatic in due course of treatment and improves with significant weight gain with no recurrence of symptoms till six months of follow up after treatment completion.



Fig. 1: Grayish white appendicectomy specimen approximately 5 cm in length

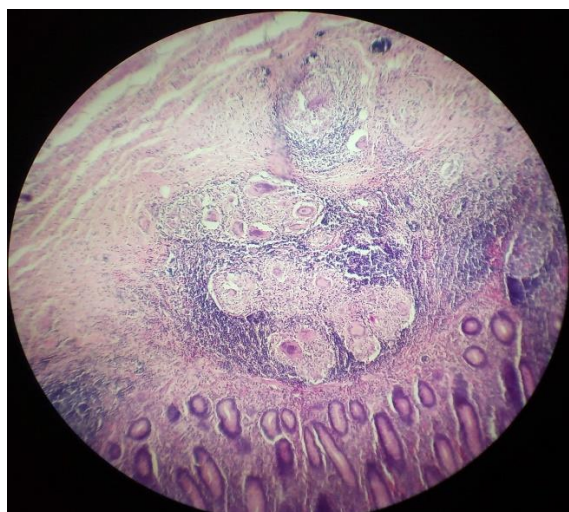


Fig. 2: Histopathological examination of the resected specimen showing the presence of chronic granulomatous inflammation composed of epithelioid cells, lymphocytes and multinucleated giant cells with caseous necrosis and rimmed by fibroblast

Discussion

Tuberculosis is one of the oldest and common infectious causes of morbidity and mortality all over the world. It has a fatal outcome, in the era of effective chemotherapy both in developing and developed countries, especially with the rising incidence of HIV infection. Gastrointestinal tuberculosis is one of variant of extra pulmonary tuberculosis. Most commonly affected organ is ileo-cecal junction. Primary appendicular involvement is distinctly uncommon, with merely fist case reports in known literature. It was first described by Corbin in 1873³. Although, gastrointestinal tuberculosis is secondary to pulmonary tuberculosis, the route of infection may be swallowing. Contaminated food, milk and other objects along with

unhealthy sanitary habits are possible modes of transmission of infection in an open case of pulmonary tuberculosis.

There are various pathways for involvements of the appendix are hematogenous, by infected intestinal contents and by extension of disease from neighbouring ileocecal or genital tuberculosis⁴. Secondary involvement can also occur as retrograde lymphatic spread from distant lesions or as appendicular serositis and peri-appendicitis in peritoneal tuberculosis⁵. There are three clinical variety tubercular appendicitis⁶. The acute form, undifferentiated pyogenic appendicitis until histologically proven, chronic form presenting with vague abdominal pain, occasional history of vomiting, diarrhoea and a mass in right iliac fossa. The third one latent type found accidentally on histopathological examination, as in our case.

The presences of chronic abdominal pain of long duration, pulmonary TB, poor nutritional status along with clinical symptoms of anorexia and chronic diarrhoea indicative of tubercular appendicitis but these symptoms are of suspicious⁷. Since there are no clinical and radiological features that are pathognomonic of appendicular TB so pre-operative diagnosis is difficult. The diagnosis is usually made after histopathological examination of the appendectomy specimen after ruling out other granulomatous diseases like Crohn's disease, sarcoidosis and foreign body induced inflammation and the most confirmatory test is tuberculosis polymerase chain reaction (TB-PCR) analysis; though expensive, it is the surest method^{8,9}. Detection of acid fast bacilli in the appendicular specimen can be negative but should be performed. The combined use of clinical diagnosis, histopathology and PCR has 100% sensitivity and 100% specificity¹⁰. Surgery is considered as the treatment of choice for appendicular TB as anti tuberculous drugs alone cannot control recurrent attacks of inflammation. Combined corticosteroid with specific antibiotic treatment used to reduce the complications of abdominal TB¹¹.

Conclusion

Primary (Isolated) tuberculosis of appendix is extremely rare entity and one of differential diagnosis of acute abdomen. The preoperative diagnosis of primary tuberculosis of the appendix is seldom possible. Appendicectomy should be performed in all patients with abdominal tuberculosis subjected to laparotomy and all surgically removed appendices should be subjected to histopathological examination to exclude tuberculosis and other pathology.

References

1. Shalaby AMR. Tuberculous appendicitis. *Inter J of Path* 2007;6(2).
2. Nuwal PI, Dixit R, Jain S, Porwal V. Isolated Appendicular Tuberculosis – A case report, *Ind. J. Tub* 2000;47:241-42.

3. Ammangi AS, Dhobale VD, Patil BV and Miskin AT. Isolated appendicular tuberculosis. *J Glob Infect Dis*. 2011;3(1):102-03.
4. Jarrett O, Grim SA, Benedetti E and Clark NM. Gastrointestinal tuberculosis in renal transplant recipients: case report and review of literature. *Transpl Infect Dis* 2011,13(1):52-57.
5. Gupta S, Kaushik R, Kaur A and Attri AK. Tubercular appendicitis-a case report. *World Journal of Emergency Surgery* 2006,1:22.
6. Tauro LF, Aithala S, George SRC, Hanumanthappa, MJ. Primary Tuberculosis of the Appendix. *OMJ [Online]* 2010 July;25(3).
7. Sharath chandra BJ, Girish TU, Thrishuli PB and Vinay HG. Primary tuberculosis of the appendix: A rare cause of common disease. *J Surg Tech Case Report* 2013;5:32-4.
8. Chong V H, Telisinghe P U, Yapp S K S, Chong C F. Tuberculous appendix: a review of clinical presentations and outcomes. *Singapore Med J* 2011;52(2):90.
9. Koujalagi RS, Baragundi MC, Uppin Sm and Togale MD. Primary Tuberculous Appendicitis: A Rare Case Report. *Int J Med Health Sci*. 2015,4(1):139-41.
10. Kesarwani RC, Pandey A, Misra A and Singh AK. Polymerase chain reaction (PCR): Its comparison with conventional techniques for diagnosis of extra pulmonary tubercular diseases. *Indian Journal of Surgery* 2004;66(2):84-8.
11. Rabbani K, Narjis Y, Difaa A, Louzi A, Benelkhaiat R and Finech B. Tuberculous appendicitis. *Saudi J Gastroenterol* 2011;17:287-8.

How to cite this article: Bunkar M, Takhar RP, Savita A, Mirdha K. Primary tuberculosis of appendix: A rare presentation. *International Journal of Medical Microbiology and Tropical Diseases* 2016;2(3):115-117.